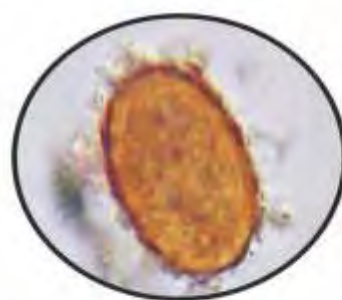
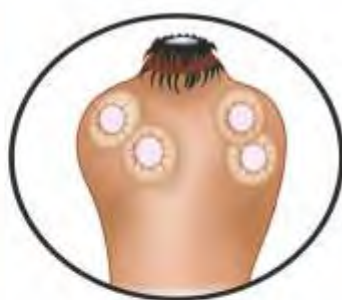
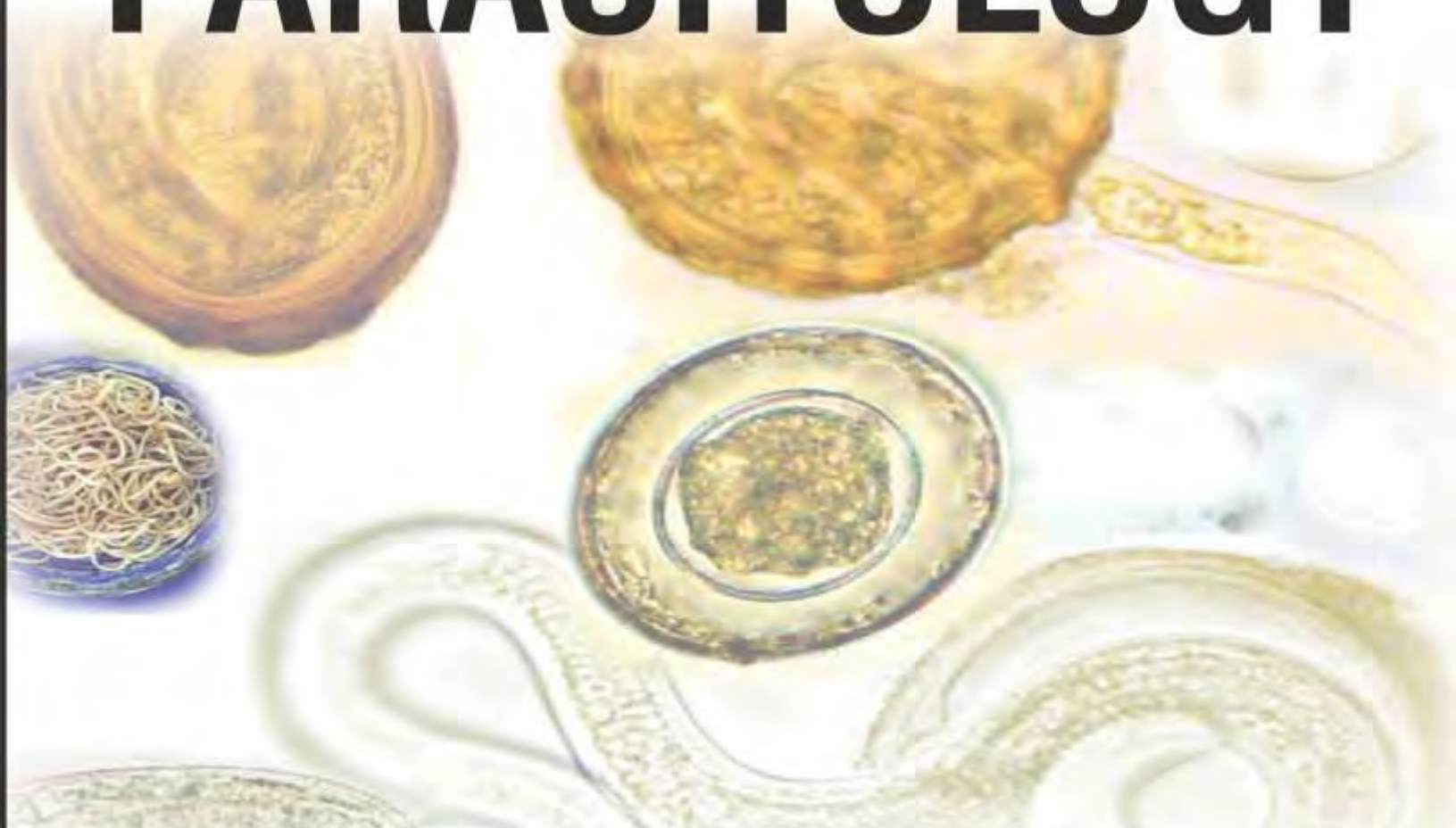8th
Edition

Paniker's Textbook of **MEDICAL PARASITOLOGY**



Revised & Edited by
Sougata Ghosh

Foreword
Jagdish Chander





ANTONIE VAN LEEUWENHOEK

Born: 24.10.1632 - Died: 26.8.1723
Delft, Holland

This man, born poor, with little education, a draper in his hometown of Delft had surprising visitors! They included great men of science as well as the Royalty like the Tsar Peter the Great, Frederick the Great of Prussia and King James II of England. This was due to his hobby of grinding fine lenses through which he looked at various objects and brought forth the wonder world of small things that none had seen before. He kept clear descriptions and accurate drawings of what he saw and communicated them to the Royal Society in London. A strict check convinced the Society of their authenticity. The unlettered Antonie was elected a Fellow of the Royal Society! The papers sent by him over decades can still be seen in the Philosophical Transactions of the Royal Society.

The discoveries he made are legion. He described the first protozoan pathogen Giardia. He also discovered many types of bacteria, human and animal spermatozoa, and eggs of various animals realizing their importance in reproduction. He could not recognize the significance of the different types of bacteria, and to him, they were just 'little animalcules'. His fault was in being much before the time, for it took two centuries more for people to accept the microbial origin of infectious diseases. But that should not deter us from acknowledging the great contributions made by Leeuwenhoek to Biology and many other branches of Science. He was truly the **Founder of Microbiology**.



Paniker's Textbook of
MEDICAL PARASITOLOGY



Paniker's Textbook of **MEDICAL PARASITOLOGY**

EIGHTH EDITION

(Late) CK Jayaram Paniker MD

Formerly
Director and Professor
Department of Microbiology
Principal
Government Medical College, Kozhikode, Kerala
Dean, Faculty of Medicine
University of Calicut, Kerala, India
Emeritus Medical Scientist
Indian Council of Medical Research
New Delhi, India

Revised and Edited by

Sougata Ghosh MD DCH

Professor
Department of Microbiology
Government Medical College
Kolkata, West Bengal, India
Formerly
Faculty
Institute of Postgraduate Medical Education and Research (IPGMER) and
Calcutta School of Tropical Medicine
Kolkata, West Bengal, India

Foreword

Jagdish Chander



JAYPEE

The Health Sciences Publisher

New Delhi | London | Panama



JAYPEE Jaypee Brothers Medical Publishers (P) Ltd.

Headquarters

Jaypee Brothers Medical Publishers (P) Ltd
4838/24, Ansari Road, Daryaganj
New Delhi 110 002, India
Phone: +91-11-43574357
Fax: +91-11-43574314
Email: jaypee@jaypeebrothers.com

Overseas Offices

J.P. Medical Ltd
83 Victoria Street, London
SW1H 0HW (UK)
Phone: +44 20 3170 8910
Fax: +44 (0)20 3008 6180
Email: info@jpmedpub.com

Jaypee Brothers Medical Publishers (P) Ltd
17/1-B Babar Road, Block-B, Shaymali
Mohammadpur, Dhaka-1207
Bangladesh
Mobile: +08801912003485
Email: jaypeedhaka@gmail.com

Jaypee-Highlights Medical Publishers Inc
City of Knowledge, Bld. 235, 2nd Floor, Clayton
Panama City, Panama
Phone: +1 507-301-0496
Fax: +1 507-301-0499
Email: cservice@jphmedical.com

Jaypee Brothers Medical Publishers (P) Ltd
Bhotahity, Kathmandu
Nepal
Phone: +977-9741283608
Email: kathmandu@jaypeebrothers.com

Website: www.jaypeebrothers.com

Website: www.jaypeedigital.com

© 2018, Jaypee Brothers Medical Publishers

The views and opinions expressed in this book are solely those of the original contributor(s)/author(s) and do not necessarily represent those of editor(s) of the book.

All rights reserved. No part of this publication may be reproduced, stored or transmitted in any form or by any means, electronic, mechanical, photocopying, recording or otherwise, without the prior permission in writing of the publishers.

All brand names and product names used in this book are trade names, service marks, trademarks or registered trademarks of their respective owners. The publisher is not associated with any product or vendor mentioned in this book.

Medical knowledge and practice change constantly. This book is designed to provide accurate, authoritative information about the subject matter in question. However, readers are advised to check the most current information available on procedures included and check information from the manufacturer of each product to be administered, to verify the recommended dose, formula, method and duration of administration, adverse effects and contraindications. It is the responsibility of the practitioner to take all appropriate safety precautions. Neither the publisher nor the author(s)/editor(s) assume any liability for any injury and/or damage to persons or property arising from or related to use of material in this book.

This book is sold on the understanding that the publisher is not engaged in providing professional medical services. If such advice or services are required, the services of a competent medical professional should be sought.

Every effort has been made where necessary to contact holders of copyright to obtain permission to reproduce copyright material. If any have been inadvertently overlooked, the publisher will be pleased to make the necessary arrangements at the first opportunity. The **CD/DVD-ROM** (if any) provided in the sealed envelope with this book is complimentary and free of cost. **Not meant for sale.**

Inquiries for bulk sales may be solicited at: jaypee@jaypeebrothers.com

Paniker's Textbook of Medical Parasitology

First Edition: 1988

Second Edition: 1989, *Reprint:* 1991

Third Edition: 1993

Fourth Edition: 1997, *Reprint:* 1999

Fifth Edition: 2002, *Reprint:* 2003, 2004

Sixth Edition: 2007, *Reprint:* 2011

Seventh Edition: 2013

Eighth Edition: **2018**

ISBN: 978-93-5270-186-5

Printed at: Ajanta Offset & Packagings Ltd., Faridabad, Haryana.

FOREWORD

This is a great pleasure to write the foreword to the eighth edition of *Paniker's Textbook of Medical Parasitology* dealing with medically important parasites *vis-a-vis* human diseases caused by them.

The parasitic infections (protozoal and helminthic) are still major cause of high morbidity as well as mortality of substantial number of population residing in the developing world of tropical and subtropical regions. The clinical presentations of parasitic diseases have also significantly evolved with the passage of time. Malaria caused by *Plasmodium vivax* has never been life-threatening but now it is presenting with renal failure as well as acute respiratory distress syndrome (ARDS) thereby leading to fatal consequences. On the other hand, some of the infections such as dracunculiasis have been eradicated from India and others are the next targets being in the pipeline.

There are a number of novel diagnostic techniques, which are being designed for rapid diagnosis of various parasitic diseases and accurate identification of their causative pathogens. The non-invasive imaging techniques, both MRI and CT scans, are proving to be very useful tools for an early diagnosis thereby delineating the extent of disease in a particular patient. Therefore, to cope up with the changing epidemiological scenario and newer diagnostic modalities, medical students and professionals involved in the patient care need updates from time to time. Dr Sougata Ghosh (Editor), has done a remarkable job of going through the voluminous information and presenting it in a very lucid, concise and reproducible manner.

This edition will ideally be suited for medical students and resident doctors, who are preparing for various examinations and entrance tests. I feel the present edition will also be appreciated by students and teaching faculties in all disciplines of medicine. The chapter on pneumocystosis has been removed, however, on sporozoa dealing with diseases caused by different species of microsporidia, traditionally retained in this edition, despite the fact that it has also been shifted now to the kingdom fungi like *Pneumocystis jirovecii*.

The unique feature of the textbook is that it has many illustrations, photographs of clinical specimens and photomicrographs with an easy-to-read and understand format. This will help the students to memorize the information given in the text easily as well as to use the same in medical practice. Each chapter has key points with a set of multiple choice questions (MCQs), which will help a student for better understanding and preparation before the examination. Although it is meant for medical graduates, recent advances mentioned in this book will also be useful for the postgraduates.

The original author, Professor CK Jayaram Paniker, was an experienced and enthusiastic medical teacher, and we recently lost him. Moreover, he was a legendary microbiologist and the author of numerous valuable textbooks, particularly co-author of *Ananthanarayan's Textbook of Microbiology*. His name has been retained as such in the title of the eighth edition of this textbook is a great honor and real tribute to him thereby continuing his legacy to attain more heights in the field of medical parasitology even in his physical absence. I hope that this textbook will continue to benefit the medical students and faculties for many years as it has done during the last three decades.



Jagdish Chander

Professor and Head
Department of Microbiology
Government Medical College and Hospital
Chandigarh, India

PREFACE TO THE EIGHTH EDITION

The previous editions of *Paniker's Textbook of Medical Parasitology* have been widely accepted by the medical students and teachers across India and abroad for almost three decades.

Medical science is not a static art. Methods of diagnosis and treatment of parasitic infections change constantly. To keep pace with these developments, all the chapters of present edition have been thoroughly revised and expanded, providing up-to-date epidemiological data, new diagnostic methods and recent treatment guidelines of parasitic infections.

In the current edition, many new tables, flow charts and photographs of specimens and microscopic view pictures have been added for better comprehension of the subject.

Recent advances such as vaccinology of malaria and leishmaniasis, malarial drug resistance, new treatment protocols of different parasitic infections are the salient features of the book.

The aim of the contents of the book remains same in this edition, that is compact yet informative and useful for both graduate and postgraduate students.

Like the last edition, the present edition is also designed in a colorful format, which can be easily read and comprehended.

Important points and terms have been highlighted by making them bold and italic. At the end of each chapter, the must-know facts are given as "Key Points" in box formats for quick recapitulation.

Important multiple choice questions (MCQs) and review questions from various university examinations' papers have been added to test and reinforce understanding of the topics by the students.

Sougata Ghosh

PREFACE TO THE FIFTH EDITION

The first edition of this book was published in 1963. It was a modest volume, intended as a text for students of the history of the United States. Over the years, it has been widely used and has received many favorable reviews. The second edition, published in 1970, was a significant revision, reflecting the changes in the field of American history. The third edition, published in 1977, was another major revision, incorporating the latest research and scholarship. The fourth edition, published in 1984, was a further revision, reflecting the continued growth and development of the field. This fifth edition, published in 1991, is the most comprehensive and up-to-date edition of the book to date. It includes new chapters, revised chapters, and updated references. The book is now a more substantial volume, reflecting the growth of the field and the increasing complexity of the subject matter. It is intended to provide a comprehensive and up-to-date survey of the history of the United States, from the early years of settlement to the present day. The book is written in a clear and concise style, and is intended to be accessible to a wide range of students. It is a valuable resource for anyone interested in the history of the United States.

The book is divided into two main parts. The first part, "The Early Years," covers the period from the early years of settlement to the American Revolution. The second part, "The American Revolution and the Early Republic," covers the period from the American Revolution to the early years of the Republic. The book is written in a clear and concise style, and is intended to be accessible to a wide range of students. It is a valuable resource for anyone interested in the history of the United States.

PREFACE TO THE FIRST EDITION

Parasitic infections continue to account for a large part of human illness. Antimicrobial drugs and vaccines that have made possible the effective control of most bacterial and viral diseases have not been as successful against parasitic infections. The numbers of persons afflicted by parasites run into many millions. Malaria still affects over 500 millions, pinworm and whipworm 500 millions each, hookworm 800 millions and roundworm a billion persons. Filariasis, leishmaniasis and schistosomiasis remain serious public health problems. Infections due to opportunist parasites are becoming increasingly evident in the affluent countries.

In recent years, there has been a resurgence in the study of parasitic infections. Much new knowledge has been gained making possible precise diagnosis and more effective control of parasites and the diseases, they cause.

This textbook attempts to present the essential information on parasites and parasitic diseases, with emphasis on pathogenesis, epidemiology, diagnosis and control. Every effort has been made to incorporate recent advances in the subject.

It is hoped that medical students, teachers and physicians will find the book useful. Their comments and suggestions for improvement of the book will be most welcome.


SHANTHI, East Hill Road
Kozhikode, Kerala-673 006

CK Jayaram Paniker

PREFACE TO THE FIRST EDITION

The first edition of this book was published in 1958. It was a time of great excitement and activity in the field of computer science. The computer had just been invented, and it was clear that it would revolutionize the way we live and work. This book was written to provide a comprehensive introduction to the field of computer science, and to help students and researchers alike to understand the basic principles and concepts of the subject. It was written in a clear and concise style, and it has since become a classic text in the field. The book has been revised and updated several times, and it continues to be a valuable resource for students and researchers alike. The first edition was published by McGraw-Hill, and it was a great success. It was one of the first books to be published in the field of computer science, and it was one of the first to be widely read and used. It was a landmark publication, and it has since become a classic in the field. The book has been translated into several languages, and it has been used in many universities and schools around the world. It is a testament to the power of the computer, and to the importance of computer science in our lives. The book is a must-read for anyone who is interested in the field of computer science, and it is a valuable resource for students and researchers alike. It is a book that has stood the test of time, and it is a book that will continue to be read and used for many years to come.

ACKNOWLEDGMENTS



I gratefully acknowledge the help of the Principal, Government Medical College, Kolkata; Director, Calcutta School of Tropical Medicine, Kolkata, West Bengal, India; and all my developmental colleagues for their valuable suggestions.

Lastly, I want to thank my parents, wife and my son Anindya Ghosh, for their emotional support, whenever I needed during preparations of the manuscript.

I solicit the comments and suggestions for the faculties and students for improvement of the book and many be e-mailed to s_ghosh2006@rediffmail.com

I owe my special thanks to Shri Jitendar P Vij (Group Chairman), Mr Ankit Vij (Group President) and Mr Sabyasachi Hazra (Commissioning Editor, Kolkata Branch) of M/s Jaypee Brothers Medical Publishers (P) Ltd, New Delhi, India, for their professional help and guidance to bring out the present edition of the book.

AT THE ALLEGMENTS

The following table shows the results of the experiments conducted on the various specimens of the material under investigation. The specimens were prepared in accordance with the standard procedure and were tested under the following conditions: temperature, humidity, and duration of exposure. The results are given in terms of the percentage of weight loss or gain, and the change in mechanical properties.

Specimen No.	Material	Temperature (°C)	Humidity (%)	Duration (hr)	Weight Change (%)	Change in Mechanical Properties
1	Aluminum	25	50	24	-0.5	None
2	Aluminum	50	50	24	-1.0	None
3	Aluminum	75	50	24	-1.5	None
4	Aluminum	100	50	24	-2.0	None
5	Aluminum	125	50	24	-2.5	None
6	Aluminum	150	50	24	-3.0	None
7	Aluminum	175	50	24	-3.5	None
8	Aluminum	200	50	24	-4.0	None
9	Aluminum	225	50	24	-4.5	None
10	Aluminum	250	50	24	-5.0	None
11	Aluminum	275	50	24	-5.5	None
12	Aluminum	300	50	24	-6.0	None
13	Aluminum	325	50	24	-6.5	None
14	Aluminum	350	50	24	-7.0	None
15	Aluminum	375	50	24	-7.5	None
16	Aluminum	400	50	24	-8.0	None
17	Aluminum	425	50	24	-8.5	None
18	Aluminum	450	50	24	-9.0	None
19	Aluminum	475	50	24	-9.5	None
20	Aluminum	500	50	24	-10.0	None
21	Aluminum	525	50	24	-10.5	None
22	Aluminum	550	50	24	-11.0	None
23	Aluminum	575	50	24	-11.5	None
24	Aluminum	600	50	24	-12.0	None
25	Aluminum	625	50	24	-12.5	None
26	Aluminum	650	50	24	-13.0	None
27	Aluminum	675	50	24	-13.5	None
28	Aluminum	700	50	24	-14.0	None
29	Aluminum	725	50	24	-14.5	None
30	Aluminum	750	50	24	-15.0	None
31	Aluminum	775	50	24	-15.5	None
32	Aluminum	800	50	24	-16.0	None
33	Aluminum	825	50	24	-16.5	None
34	Aluminum	850	50	24	-17.0	None
35	Aluminum	875	50	24	-17.5	None
36	Aluminum	900	50	24	-18.0	None
37	Aluminum	925	50	24	-18.5	None
38	Aluminum	950	50	24	-19.0	None
39	Aluminum	975	50	24	-19.5	None
40	Aluminum	1000	50	24	-20.0	None

CONTENTS



1. General Introduction: Parasitology

1

- Parasites 1
- Host 1
- Zoonosis 2
- Host-parasite Relationships 2
- Life Cycle of Parasites 3
- Sources of Infection 3
- Modes of Infection 4
- Pathogenesis 4
- Immunity in Parasitic Infection 5
- Immune Evasion 5
- Vaccination 5
- Laboratory Diagnosis 6

2. Protozoa

10

- General Features 10
- Structure 10
- Cytoplasm 10
- Nucleus 10
- Terminologies Used in Protozoology 10
- Reproduction 11
- Life Cycle 11
- Classification of Protozoa 11

3. Amebae

15

- Entamoeba histolytica* 15
- Nonpathogenic Intestinal Ameba 24
- Pathogenic Free-living Amebae 26

4. Intestinal, Oral and Genital Flagellates

32

- Giardia lamblia* 32
- Trichomonas* 36
- Chilomastix mesnili* 38
- Enteromonas hominis* 38
- Retortamonas intestinalis* 38
- Dientamoeba fragilis* 39

5. Hemoflagellates**41**

- Zoological Classification of Flagellates 41
- General Characteristics 41
- Trypanosomes 42
- Leishmania* 52

6. Malaria and Babesia**66**

- Malaria** 66
 - Classification 66
 - Causative Agents of Human Malaria 66
 - Malaria Parasite 66
- Babesia Species** 86
 - Classification 86
 - History and Distribution 86
 - Habitat 86
 - Morphology 86
 - Life Cycle 86
 - Pathogenicity and Clinical Features 87
 - Laboratory Diagnosis 87
 - Treatment 88
 - Prophylaxis 88

7. Coccidia**90**

- Toxoplasma gondii* 90
- Iso spor a belli* 96
- Cryptosporidium parvum* 97
- Cyclospor a cayetanensis* 100
- Blastocystis hominis* 101
- Sarcocystis* 102

8. Microspora**104**

- History and Distribution 104
- Morphology 104
- Life Cycle 105
- Clinical Features 105
- Laboratory Diagnosis 105
- Treatment 106
- Prophylaxis 106

9. *Balantidium coli***107**

- History and Distribution 107
- Habitat 107
- Morphology 107
- Life Cycle 108
- Pathogenesis 108
- Clinical Features 109
- Laboratory Diagnosis 109
- Treatment 109
- Prophylaxis 109

10. Helminths: General Features**111**

- Phylum Platyhelminthes 111
- Phylum Nematelminthes (Nematoda) 112
- Important Features of Helminths 112
- Zoological Classification of Helminths 113

11. Cestodes: Tapeworms**115**

- Classification of Cestodes 115
- Tapeworms: General Characteristics 115
- Pseudophyllidean Tapeworms 117
- Cyclophyllidean Tapeworms 122

12. Trematodes: Flukes**141**

- Classification of Trematodes 141
- Flukes: General Characteristics 141
- Life Cycle 142
- Blood Flukes 143
- Hermaphroditic Flukes: Liver Flukes 150
- Intestinal Flukes 156
- Lung Flukes 160

13. Nematodes: General Features**164**

- General Characteristics 164
- Life Cycle 164
- Modes of Infection 165
- Classification 165
- Larva Migrans 165

14. *Trichinella spiralis***170**

- Common Name 170
- History and Distribution 170
- Habitat 170
- Morphology 170
- Life Cycle 171
- Pathogenicity and Clinical Features 172
- Diagnosis 172
- Treatment 174
- Prophylaxis 174

15. *Trichuris trichiura***175**

- Common Name 175
- History and Distribution 175
- Habitat 175
- Morphology 175
- Life Cycle 176
- Pathogenicity and Clinical Features 177
- Laboratory Diagnosis 178
- Treatment 178
- Prophylaxis 178

16. *Strongyloides stercoralis***180**

- History and Distribution 180
- Habitat 180
- Morphology 180
- Life Cycle 182
- Pathogenicity and Clinical Features 183
- Laboratory Diagnosis 184
- Treatment 185
- Prophylaxis 185

17. Hookworm**187**

- History and Distribution 187
- Ancylostoma duodenale* 187
- Necator americanus* 189
- Pathogenicity and Clinical Features of Hookworm Infection 190
- Laboratory Diagnosis 191
- Treatment 192

Prophylaxis 193
Other Hookworms 193
Trichostrongyliasis 193

18. *Enterobius vermicularis* 195

Common Name 195
History and Distribution 195
Habitat 195
Morphology 195
Life Cycle 196
Pathogenicity and Clinical Features 196
Laboratory Diagnosis 197
Treatment 198
Prophylaxis 199

19. *Ascaris lumbricoides* 200

Common Name 200
History and Distribution 200
Habitat 200
Morphology 200
Life Cycle 201
Pathogenicity and Clinical Features 203
Laboratory Diagnosis 205
Treatment 205
Prophylaxis 205

20. Filarial Worms 208

Lymphatic Filariasis 210
Subcutaneous Filariasis 219

21. *Dracunculus medinensis* 225

Common Name 225
History and Distribution 225
Habitat 225
Morphology 225
Life Cycle 226
Pathogenicity and Clinical Features 227
Laboratory Diagnosis 227
Treatment 227
Prophylaxis 229

22. Miscellaneous Nematodes**230***Angiostrongylus cantonensis* 230*Capillaria philippinensis* 231*Gnathostoma spinigerum* 231

Anisakiasis 232

23. Diagnostic Methods in Parasitology**234**

Examination of Stool 234

Examination of Blood 240

Sputum Examination 242

Urine or Body Fluids Examination 243

Tissue Biopsy 243

Muscle Biopsy 243

Duodenal Capsule Technique (Enterotest) 243

Sigmoidoscopy Material 244

Urogenital Specimen 244

Culture Methods 244

Animal Inoculation 245

Xenodiagnosis 245

Immunological Diagnosis 246

Skin Tests 247

Molecular Methods 247

Index

249

General Introduction: Parasitology

■ INTRODUCTION

Medical parasitology deals with the parasites, which cause human infections and the diseases they produce.

- It is broadly divided into two parts:
 1. Protozoology
 2. Helminthology.
- The pioneer Dutch microscopist, *Antonie van Leeuwenhoek of Holland* in 1681, first introduced single lens microscope and observed *Giardia* in his own stools.
- *Louis Pastuer* in 1870, first published scientific study on a protozoal disease leading to its control and prevention during investigation of an epidemic silk worm disease in South Europe.
- A seminal discovery was made in 1878 by *Patrick Manson* about the role of mosquitoes in filariasis. This was the first evidence of vector transmission.
- Afterwards, *Laveran* in Algeria discovered the malarial parasite (1880), and *Ronald Ross* in Secunderabad and Calcutta in India, showed its transmission by mosquitoes (1897). A large number of vector-borne disease have since then been identified.
- By mid 20th century, with dramatic advances in antibiotics and chemotherapy, insecticides and antiparasitic drugs, and improved lifestyles, all infectious diseases seemed amenable to control.

■ PARASITES

Parasites are living organisms, which depend on a living host for their nourishment and survival. They multiply or undergo development in the host.

- The term "parasite" is usually applied to *Protozoa* (unicellular organisms) and *Helminths* (multicellular organisms) (**Flow chart 1**).
- Parasites can also be classified as:
 - **Ectoparasite:** Ectoparasites inhabit only the body surface of the host without penetrating the tissue. Lice, ticks and mites are examples of ectoparasites. The

term *infestation* is often employed for parasitization with ectoparasites.

- **Endoparasite:** A parasite, which lives within the body of the host and is said to cause an infection is called an endoparasite. Most of the protozoan and helminthic parasites causing human disease are endoparasites.
- **Free-living parasite:** It refers to nonparasitic stages of active existence, which live independent of the host, e.g. cystic stage of *Naegleria fowleri*.
- Endoparasites can further be classified as:
 - **Obligate parasite:** The parasite, which cannot exist without a host, e.g. *Toxoplasma gondii* and *Plasmodium*.
 - **Facultative parasite:** Organism which may either live as parasitic form or as free-living form, e.g. *Naegleria fowleri*.
 - **Accidental parasites:** Parasites, which infect an unusual host are known as accidental parasites. *Echinococcus granulosus* infects man accidentally, giving rise to hydatid cysts.
 - **Aberrant parasites:** Parasites, which infect a host where they cannot develop further are known as aberrant or wandering parasites, e.g. *Toxocara canis* (dog roundworm) infecting humans.

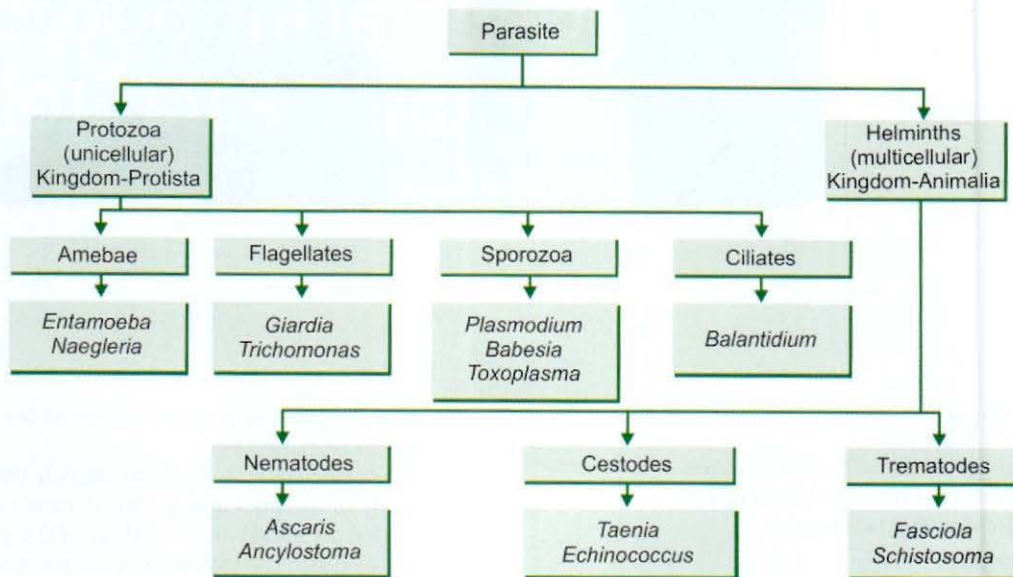
■ HOST

Host is defined as an organism, which harbors the parasite and provides nourishment and shelter to latter and is relatively larger than the parasite.

- The host may be of the following types:
 - **Definitive host:** The host, in which the adult parasite lives and undergoes sexual reproduction is called the definitive host, e.g. mosquito acts as definitive host in malaria.

The definitive host may be a human or any other living being. However, in majority of human parasitic infections, man is the definitive host (e.g. filaria, roundworm, hookworm).

Flow chart 1: Types of parasites



- **Intermediate host:** The host, in which the larval stage of the parasite lives or asexual multiplication takes place is called the intermediate host. In some parasites, two different intermediate hosts may be required to complete different larval stages. These are known as *first and second intermediate hosts*, respectively (**Box 1**).
- **Paratenic host:** A host, in which larval stage of the parasite remains viable without further development is referred as a paratenic host. Such host transmits the infection to another host, e.g. fish for plerocercoid larva of *D. latum*.
- **Reservoir host:** In an endemic area, a parasitic infection is continuously kept up by the presence of a host, which harbors the parasite and acts as an important source of infection to other susceptible hosts, e.g. dog is the reservoir host of hydatid disease.
- **Accidental host:** The host, in which the parasite is not usually found, e.g. man is an accidental host for cystic echinococcosis.

Box 1: Parasites with man as intermediate or secondary host

- *Plasmodium* spp.
- *Babesia* spp.
- *Toxoplasma gondii*
- *Echinococcus granulosus*
- *Echinococcus multilocularis*
- *Taenia solium*
- *Spirometra* spp.

- It is of following types:
 - *Protozoal zoonoses*, e.g. toxoplasmosis, leishmaniasis, balantidiasis and cryptosporidiosis.
 - *Helminthic zoonoses*, e.g. hydatid disease, taeniasis.
 - *Anthropozoonoses*: Infections transmitted to man from lower vertebrate animals, e.g. cystic echinococcosis.
 - *Zooanthroponoses*: Infections transmitted from man to lower vertebrate animals, e.g. human tuberculosis to cattle.

■ ZOONOSIS

The word *zoonosis* was introduced by Rudolf Virchow in 1880 to include the diseases shared in nature by man and animals.

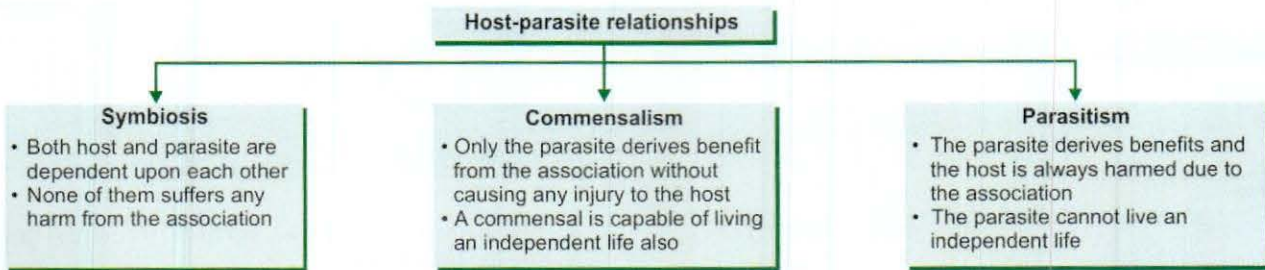
- Later, in 1959, the World Health Organization (WHO) defined zoonosis as *those diseases and infections, which are naturally transmitted between vertebrate animals and man*.

■ HOST-PARASITE RELATIONSHIPS

Host-parasite relationships are of following types (**Flow chart 2**):

- Symbiosis
- Commensalism
- Parasitism.

Flow chart 2: Host-parasite relationships



■ LIFE CYCLE OF PARASITES

- **Direct life cycle:** When a parasite requires only single host to complete its development, it is called as direct life cycle, e.g. *Entamoeba histolytica* requires only a human host to complete its life cycle (Table 1).
- **Indirect life cycle:** When a parasite requires two or more species of host to complete its development, the life cycle is called as indirect life cycle, e.g. malarial parasite requires both human host and mosquito to complete its life cycle (Tables 2 and 3).

■ SOURCES OF INFECTION

- **Contaminated soil and water:**
 - Soil polluted with embryonated eggs (roundworm, whipworm) may be ingested or infected larvae in soil, may penetrate exposed skin (hookworm).
 - Infective forms of parasites present in water may be ingested (cyst of ameba and *Giardia*).
 - Water containing the intermediate host may be swallowed (cyclops containing guinea worm larva).
 - Infected larvae in water may enter by penetrating exposed skin (cercariae of schistosomes).
 - Free-living parasites in water may directly enter through vulnerable sites (*Naegleria* may enter through nasopharynx).
- **Food:**
 - Ingestion of contaminated food or vegetables containing infective stage of parasite (amebic cysts, *Toxoplasma* oocysts, *Echinococcus* eggs).
 - Ingestion of raw or undercooked meat harboring infective larvae (measly pork containing cysticercus cellulosae, the larval stage of *Taenia solium*).
- **Vectors:** A vector is an agent, usually an arthropod that transmits an infection from man to man or from other animals to man, e.g. female *Anopheles* is the vector of malarial parasite. Vectors can be:
 - **Biological vectors:** The term biological vector refers to a vector, which not only assists in the transfer of

Table 1: Parasites having direct life cycle (requiring no intermediate host)

Protozoa	Helminths
• <i>Entamoeba histolytica</i>	• <i>Ascaris lumbricoides</i>
• <i>Giardia lamblia</i>	• <i>Enterobius vermicularis</i>
• <i>Trichomonas vaginalis</i>	• <i>Trichuris trichiura</i>
• <i>Balantidium coli</i>	• <i>Ancylostoma duodenale</i>
• <i>Cryptosporidium parvum</i>	• <i>Necator americanus</i>
• <i>Cyclospora cayetanensis</i>	• <i>Hymenolepis nana</i>
• <i>Isospora belli</i>	
• <i>Microsporidia</i>	

parasites but the parasites undergo development or multiplication in their body as well. They are also called as **true vectors**. Example of true vectors are:

- **Mosquito:** Malaria, filariasis
- **Sandflies:** Kala-azar
- **Tsetse flies:** Sleeping sickness
- **Reduviid bugs:** Chagas disease
- **Ticks:** Babesiosis.

– **Mechanical vectors:** The term mechanical vector refers to a vector, which assists in the transfer of parasitic form between hosts but is not essential in the life cycle of the parasite. Example of mechanical vectors is:

- **Housefly:** Amebiasis

In biological vectors, a certain period has to elapse after the parasite enters the vector, before it becomes infective. This is necessary because the vector can transmit the infection only after the parasite multiplies to a certain level or undergoes a developmental process in its body. This interval between the entry of the parasite into the vector and the time it takes to become capable of transmitting the infection is called the **extrinsic incubation period**.

- **Animals:**
 - **Domestic:**
 - ♦ Cow, e.g. *T. saginata*, *Sarcocystis*

Table 2: Parasites having indirect life cycle requiring one intermediate host and one definitive host

Parasite	Definitive host	Intermediate host
<i>Protozoa</i>		
<i>Plasmodium</i> spp.	Female <i>Anopheles</i> mosquito	Man
<i>Babesia</i>	Tick	Man
<i>Leishmania</i>	Man, dog	Sandfly
<i>Trypanosoma brucei</i>	Man	Tsetse fly
<i>Trypanosoma cruzi</i>	Man	Triatomine bug
<i>Toxoplasma gondii</i>	Cat	Man
<i>Cestodes</i>		
<i>Taenia solium</i>	Man	Pig
<i>Taenia saginata</i>	Man	Cattle
<i>Echinococcus granulosus</i>	Dog	Man
<i>Trematodes</i>		
<i>Fasciola hepatica</i>	Man	Snail
<i>Fasciolopsis buski</i>	Man, pig	Snail
<i>Schistosoma</i> spp.	Man	Snail
<i>Nematodes</i>		
<i>Trichinella spiralis</i>	Man	Pig
<i>Wuchereria bancrofti</i>	Man	Mosquito
<i>Brugia malayi</i>	Man	Mosquito
<i>Dracunculus medinensis</i>	Man	Cyclops

Table 3: Parasites having indirect life cycle requiring two intermediate host and one definitive host

Parasite	Intermediate hosts	Definitive host
<i>Fasciola</i> spp.	Snail, plant	Man
<i>Clonorchis sinensis</i>	Snail, fish	Man
<i>Diphyllobothrium latum</i>	Cyclops, fish	Man
<i>Paragonimus westermani</i>	Snail, crustacean	Man

- ♦ Pig, e.g. *T. solium*, *Trichinella spiralis*
- ♦ Dog, e.g. *Echinococcus granulosus*
- ♦ Cat, e.g. *Toxoplasma*, *Opisthorchis*.

– **Wild:**

- ♦ Wild game animals, e.g. trypanosomiasis
- ♦ Wild felines, e.g. *Paragonimus westermani*
- ♦ Fish, e.g. fish tapeworm
- ♦ Molluscs, e.g. liver flukes
- ♦ Copepods, e.g. guinea worm.

- **Carrier:** A person who is infected with parasite without any clinical or subclinical disease is known as carrier. He can transmit parasite to others. For example, all

Box 2: Parasites causing autoinfection

- *Hymenolepis nana*
- *Enterobius vermicularis*
- *Taenia solium*
- *Strongyloides stercoralis*
- *Capillaria philippinensis*
- *Cryptosporidium parvum*

anthroponotic infections, vertical transmission of congenital infections.

- **Self (autoinfection) (Box 2):**

- Finger-to-mouth transmission, e.g. pinworm
- Internal reinfection, e.g. *Strongyloides*.

■ MODES OF INFECTION

- **Oral transmission:** The most common method of transmission is through oral route by contaminated food, water, soiled fingers, or fomites. Many intestinal parasites enter the body in this manner, the infective stages being cysts, embryonated eggs, or larval forms. Infection with *E. histolytica* and other intestinal protozoa occurs when the infective cysts are swallowed.
- **Skin transmission:** Entry through skin is another important mode of transmission. Hookworm infection is acquired, when the larvae enter the skin of persons walking barefooted on contaminated soil. Schistosomiasis is acquired when the cercarial larvae in water penetrate the skin.
- **Vector transmission:** Many parasitic diseases are transmitted by insect bite, e.g. malaria is transmitted by bite of female *Anopheles* mosquito, filariasis is transmitted by bite of *Culex* mosquito. A vector could be a biological vector or a mechanical vector.
- **Direct transmission:** Parasitic infection may be transmitted by person-to-person contact in some cases, e.g. by kissing in the case of gingival amebae and by sexual intercourse in trichomoniasis.
- **Vertical transmission:** Mother to fetus transmission may take place in malaria and toxoplasmosis.
- **Iatrogenic transmission:** It is seen in case of transfusion malaria and toxoplasmosis after organ transplantation.

■ PATHOGENESIS

Parasitic infections may remain inapparent or give rise to clinical disease. A few organisms, such as *E. histolytica* may live as surface commensals, without invading the tissue.

- Clinical infection produced by parasite may take many forms: acute, subacute, chronic, latent, or recurrent.
- Pathogenic mechanisms, which can occur in parasitic infections are:
 - **Lytic necrosis:** Enzymes produced by some parasite can cause lytic necrosis. *E. histolytica* lyses intestinal cells and produces amebic ulcers.

- **Trauma:** Attachment of hookworms on jejunal mucosa leads to traumatic damage of villi and bleeding at the site of attachment.
- **Allergic manifestations:** Clinical illness may be caused by host immune response to parasitic infection, e.g. eosinophilic pneumonia in *Ascaris* infection and anaphylactic shock in rupture of hydatid cyst.
- **Physical obstruction:** Masses of roundworm cause intestinal obstruction. *Plasmodium falciparum* malaria may produce blockage of brain capillaries in cerebral malaria.
- **Inflammatory reaction:** Clinical illness may be caused by inflammatory changes and consequent fibrosis, e.g. lymphadenitis in filariasis and urinary bladder granuloma in *Schistosoma haematobium* infection.
- **Neoplasia:** A few parasitic infection have been shown to lead to malignancy. The liver fluke, *Clonorchis* may induce bile duct carcinoma, and *S. haematobium* may cause urinary bladder cancer.
- **Space occupying lesions:** Some parasites produce cystic lesion that may compress the surrounding tissue or organ, e.g. hydatid cyst.

■ IMMUNITY IN PARASITIC INFECTION

Like other infectious agents, parasites also elicit immunoresponses in the host, both humoral as well as cellular (**Fig. 1**). But immunological protection against parasitic infections is much less efficient, than it is against bacterial or viral infections. Several factors may contribute to this:

- Compared to bacteria and viruses, parasites are enormously larger or more complex structurally and antigenically, so that immune system may not be able to focus attack on the protective antigens.
- Many protozoan parasites are intracellular in location, and this protects them from immunological attack. Several protozoa and helminths live inside body cavities. This location limits the efficiency of immunological attack.
- Once the parasitic infection is completely eliminated, the host becomes again susceptible to reinfection. This type of immunity to reinfection is dependent on the continued presence of residual parasite population and is known as “**premunition**”.
- Antibodies belonging to different immunoglobulin classes are produced in response to parasitic infections. Selective tests for immunoglobulin M (IgM) are helpful in differentiating current infections from old infections.
- Excessive IgE response occurs in helminthiasis. A characteristic cellular response in helminth parasite is eosinophilia both local and systemic (**Fig. 1**).
- Parasites have evolved to be closely adapted to the host and most parasitic infections are chronic and show a degree of host specificity. For example, malarial parasites

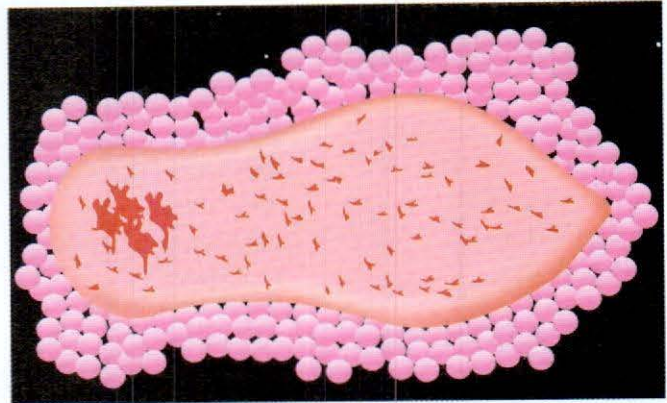


Fig. 1: Eosinophils surrounding schistosomulum (an example of immune attack in bloodstream)

Box 3: Parasites exhibiting antigenic variations

- *Trypanosoma brucei gambiense*
- *Trypanosoma brucei rhodesiense*
- *Plasmodium* spp.
- *Giardia lamblia*.

of human, bird and rodents are confined to their own particular species.

- Parasites like trypanosomes exhibit antigenic variation within the host. This genetic switch protects them from antibodies. Similar mechanism may be operative in the recrudescences in human malaria (**Box 3**).
- Some parasites adopt antigenic disguise. Their surface antigens are so closely similar to host components that they are not recognized as foreign by the immune system.
- Some infections may produce immunodeficiency due to extensive damage to the reticuloendothelial system, as in case of visceral leishmaniasis.

The fact that immunity normally plays an important role in the containment of parasitic infections is illustrated by the florid manifestations caused by opportunistic parasites such as *Pneumocystis jirovecii* and *T. gondii*, when the immune response is inadequate as in acquired immunodeficiency syndrome (AIDS) and other immunodeficiencies.

■ IMMUNE EVASION

All animal pathogens, including parasitic protozoa and worms have evolved effective mechanism to avoid elimination by the host defense system as described in **Table 4**.

■ VACCINATION

No effective vaccine for humans has so far been developed against parasites due to their complex life cycles, adaptive responses and antigenic variation, great progress has been

Table 4: Parasite escape mechanisms

Parasite escape mechanisms	Example
Intracellular habitat	Malarial parasite, <i>Leishmania</i>
Encystment	<i>Toxoplasma</i> <i>Trypanosoma cruzi</i>
Resistance to microbial phagocytosis	<i>Leishmania</i>
Masking of antigens	Schistosomes
Variation of antigen	Trypanosomes <i>Plasmodium</i> spp.
Suppression of immune response	<i>Trichinella spiralis</i> <i>Schistosoma mansoni</i> Malarial parasite
Interference by polyclonal activation	Trypanosomes
Sharing of antigens between parasite and host-molecular mimicry	Schistosomes
Continuous turnover and release of surface antigens of parasite	Schistosomes

made in identifying protective antigens in malaria and some other infections, with a view to eventual development of prophylactic vaccines.

LABORATORY DIAGNOSIS

Most of the parasitic infection cannot be conclusively diagnosed. On the basis of clinical features and physical examination laboratory diagnosis depends upon:

- Microscopy
- Culture
- Serological test
- Skin test
- Molecular method
- Animal inoculation
- Xenodiagnosis
- Imaging
- Hematology.

Microscopy

An appropriate clinical specimen should be collected for definitive diagnosis of parasitic infections.

- Following specimens are usually examined to establish a diagnosis:
 - Stool
 - Blood
 - Urine
 - Sputum
 - Cerebrospinal fluid (CSF)
 - Tissue and aspirates
 - Genital specimens.

Stool Examination

Examination of stool is very important for the detection of intestinal infections like *Giardia*, *Entamoeba*, *Ascaris*, *Ancylostoma*, etc.

Cysts and trophozoites of *E. histolytica*, *G. lamblia* can be demonstrated in feces. Eggs of roundworm and tapeworm are also found in stool. The larvae are found in the feces in *S. stercoralis* infection (**Table 5**).

For further details, refer to Chapter 23.

Blood Examination

Examination of blood is of vital importance for demonstrating parasites which circulate in blood vessels (**Table 6**). Malarial parasite is confirmed by demonstration of its morphological stages in the blood.

Urine Examination

The characteristic lateral-spined eggs of *S. haematobium* and trophozoites of *T. vaginalis* can be detected in urine. Microfilaria of *W. bancrofti* are often demonstrated in the chylous urine (**Box 4**).

Sputum Examination

The eggs of *P. westermani* are commonly demonstrated in the sputum specimen. Occasionally, larval stages of *S. stercoralis* and *A. lumbricoides* may also be found in sputum.

Cerebrospinal Fluid Examination

Some protozoa like *T. brucei*, *Naegleria*, *Acanthamoeba*, *Balamuthia* and *Angiostrongylus* can be demonstrated in the CSF.

Tissue and Aspirates Examination

The larvae of *Trichinella* and eggs of *Schistosoma* can be demonstrated in the muscle biopsy specimens. By histopathological examination of brain, *Naegleria* and *Acanthamoeba* can be detected. In kala-azar, Leishman-Donovan (LD) bodies can be demonstrated in spleen and bone marrow aspirate. Trophozoites of *Giardia* can be demonstrated in intestinal aspirates. Trophozoites of *E. histolytica* can be detected in liver pus in cases of amebic liver abscess.

Genital Specimen Examination

Trophozoites of *T. vaginalis* are found in the vaginal and urethral discharge. Eggs of *E. vermicularis* are found in anal swabs.

Table 5: Parasites and their developmental stages found in stool

Cysts/Trophozoites	Eggs	Larvae	Adult worms
• <i>Entamoeba histolytica</i>	Cestodes	• <i>Gastrodiscoides hominis</i>	<i>Strongyloides stercoralis</i>
• <i>Giardia lamblia</i>	• <i>Taenia</i> spp.	• <i>Heterophyes heterophyes</i>	• <i>Taenia solium</i>
• <i>Balantidium coli</i>	• <i>Hymenolepis nana</i>	• <i>Metagonimus yokogawai</i>	• <i>Taenia saginata</i>
• <i>Sarcocystis</i> spp.	• <i>Hymenolepis diminuta</i>	• <i>Opisthorchis</i> spp.	• <i>Diphyllobothrium latum</i>
• <i>Isospora belli</i>	• <i>Dipylidium caninum</i>	Nematodes	• <i>Ascaris lumbricoides</i>
• <i>Cyclospora cayetanensis</i>	• <i>Diphyllobothrium latum</i>	• <i>Trichuris trichiura</i>	• <i>Enterobius vermicularis</i>
• <i>Cryptosporidium parvum</i>	Trematodes	• <i>Enterobius vermicularis</i>	• <i>Trichinella spiralis</i>
	• <i>Schistosoma</i> spp.	• <i>Ascaris lumbricoides</i>	
	• <i>Fasciolopsis buski</i>	• <i>Ancylostoma duodenale</i>	
	• <i>Fasciola hepatica</i>	• <i>Necator americanus</i>	
	• <i>Fasciola gigantica</i>	• <i>Trichostrongylus orientalis</i>	
	• <i>Clonorchis sinensis</i>		

Table 6: Parasites found in peripheral blood film

Protozoa	Nematodes
• <i>Plasmodium</i> spp.	• <i>Wuchereria bancrofti</i>
• <i>Babesia</i> spp.	• <i>Brugia malayi</i>
• <i>Trypanosoma</i> spp.	• <i>Loa loa</i>
• <i>Leishmania</i> spp.	• <i>Mansonella</i> spp.

Box 4: Parasites found in urine

- *Schistosoma haematobium*
- *Wuchereria bancrofti*
- *Trichomonas vaginalis*

Culture

Some parasites like *Leishmania*, *Entamoeba* and *Trypanosoma* can be cultured in the laboratory in various axenic and polyxenic media.

Serological Tests

Serological tests are helpful for the detection and surveillance of many protozoal and helminthic infections. These tests are basically of two types:

1. Tests for antigen detection
2. Tests for antibody detection.

Antigen Detection

Malaria antigen like *P. falciparum* lactate dehydrogenase (pLDH) and histidine-rich protein 2 (HRP-2) are detected

Table 7: Antigen detection in parasitic diseases

• Galactose lectin antigen	<i>Entamoeba histolytica</i>
• Giardia-specific antigen 65	<i>Giardia lamblia</i>
• WKK and rk39 antigen	<i>Leishmania donovani</i>
• HRP-2 antigen	<i>Plasmodium falciparum</i>
• Vivax specific pLDH	<i>Plasmodium vivax</i>
• 200 kDa Ag and OG4C3 antigen	<i>Wuchereria bancrofti</i>

Abbreviations: Ag, antigen; HRP-2, histidine-rich protein 2; pLDH, *P. falciparum* lactate dehydrogenase; rk39, recombinant kinesin 39; WKK, Witebsky, Klingenstein and Kuhn

by rapid immunochromatographic test. Filarial antigens are detected in current infection by enzyme-linked immunosorbent assay (ELISA) (**Table 7**).

Antibody Detection

The following antibody detection procedures are useful in detecting various parasitic infections like amebiasis, echinococcosis and leishmaniasis in man:

- Complement fixation test (CFT)
- Indirect hemagglutination (IHA)
- Indirect immunofluorescent antibody (IFA) test
- Rapid immunochromatographic test (ICT)
- Enzyme-linked immunosorbent assay test (ELISA).

Skin Test

Skin tests are performed by injecting parasitic antigen intradermally and observing the reaction. In immediate hypersensitivity reaction, wheal and flare response is seen within 30 minutes of infection, whereas erythema and

Box 5: Important skin tests done in parasitology

- Casoni's test done in hydatid disease
- Montenegro test or leishmanin test done in kala-azar
- Frenkel's test done in toxoplasmosis
- Fairley's test done in schistosomiasis
- Bachman intradermal test done in trichinellosis.

induration seen after 48 hours of injection is called as delayed hypersensitivity reaction (**Box 5**).

Molecular Diagnosis

Molecular methods most frequently used to diagnose human parasitic infection are deoxyribonucleic acid (DNA) probes, polymerase chain reaction (PCR) and microarray technique. These tests are very sensitive and specific.

Animal Inoculation

It is useful for the detection of *Toxoplasma*, *Trypanosoma* and *Babesia* from the blood and other specimens.

Xenodiagnosis

Some parasitic infection like Chagas disease caused by *T. cruzi* can be diagnosed by feeding the larvae of reduviid bugs with patient's blood and then detection of amastigotes of *T. cruzi* in their feces.

Imaging

Imaging procedures like X-ray, ultrasonography (USG), computed tomography (CT) scan and magnetic resonance imaging (MRI) are now being extensively used for diagnosing various parasitic infections like neurocysticercosis and hydatid cyst disease.

Hematology

Anemia is frequently seen in hookworm infection and malaria. Eosinophilia is frequently present in helminthic infections. Hypergammaglobulinemia occurs in visceral leishmaniasis. Leukocytosis is seen in amebic liver abscess.

KEY POINTS

- Leeuwenhoek in 1681, first observed the parasite *Giardia* in stools. Laveran in 1880, discovered malarial parasite and Ronald Ross in 1897 showed the transmission of malaria by mosquitoes.
- Protozoa belong to kingdom Protista and helminths belong to kingdom Animalia.

- **Definitive host:** The host in which the adult stage lives or the sexual mode of reproduction takes place.
- **Intermediate host:** The host in which the larval stage of the parasite lives or the asexual multiplication takes place.
- **Zoonoses:** Diseases which can be transmitted to humans from animals, e.g. malaria, leishmaniasis, trypanosomiasis and echinococcosis.
- Parasites like trypanosomes exhibit antigenic variation within the host.
- Parasites like *Ascaris* and *Echinococcus* cause allergic manifestations in the host.
- Innate immunity against parasite may be genetic or by nonspecific direct cell-mediated or by complement activation.
- Acquired immunity in parasitic infections is by generating specific antibodies and effector T-cells against parasitic antigens.
- Diagnosis of parasitic infections are made by direct identification of parasite in specimens like stool, blood, urine, bone marrow, CSF, sputum, etc.
- Serological tests are also useful in diagnosis by detection of parasite-specific antibody and antigen.
- Other diagnostic modalities include imaging, molecular methods like PCR, skin test and xenodiagnosis.

REVIEW QUESTIONS

1. Write short notes on:
 - a. Parasites
 - b. Host
 - c. Host-parasite relationship
 - d. Zoonoses
 - e. Immune evasion mechanism of the parasites.
2. Discuss briefly the laboratory diagnosis of parasites.
3. Describe immunity in parasitic infections.
4. Differentiate between:
 - a. Direct and indirect life cycle
 - b. Definitive host and intermediate hosts

MULTIPLE CHOICE QUESTIONS

1. Definitive host is one
 - a. In which sexual multiplication takes place and harbors adult form
 - b. In which asexual multiplication takes place and harbors adult form
 - c. In which sexual multiplication takes place and harbors larval form
 - d. In which asexual multiplication takes place and harbors adult form
2. Autoinfection is seen in all except
 - a. *Hymenolepis nana*
 - b. *Enterobius vermicularis*
 - c. *Taenia solium*
 - d. *Ascaris lumbricoides*

3. Antigenic variation is exhibited by
- Entamoeba*
 - Schistosoma*
 - Trypanosoma*
 - Leishmania*
4. Which parasite enters the body by piercing the skin
- Trichuris trichiura*
 - Ascaris*
 - Necator americanus*
 - Plasmodium*
5. Which parasitic infection leads to malignancy
- Babesiosis
 - Clonorchis sinensis*
 - Trypanosoma cruzi*
 - Schistosoma haematobium*
6. Xenodiagnosis is useful in
- Wuchereria bancrofti*
 - Trypanosoma cruzi*
 - Trichinella spiralis*
 - All of the above
7. The following are zoonotic disease except
- Leishmaniasis
 - Balantidiasis
 - Scabies
 - Taeniasis
8. Two hosts are required in
- Taenia solium*
 - Entamoeba histolytica*
 - Trichuris trichiura*
 - Giardia*
9. Which of the following parasite passes its life cycle through three hosts
- Fasciola hepatica*
 - Fasciola buski*
 - Schistosoma haematobium*
 - Clonorchis sinensis*
10. Man is the intermediate host for
- Strongyloides stercoralis*
 - Plasmodium vivax*
 - Entamoeba histolytica*
 - Enterobius vermicularis*

Answer

1. a 2. d 3. c 4. c 5. b 6. d 7. c
8. a 9. d 10. b

Protozoa

■ INTRODUCTION

- Single-celled eukaryotic microorganisms belonging to kingdom Protista are classified as **Protozoa** (Greek *protos*: first; *zoon*: animal).
- Parasitic protozoa are adapted to different host species.
- Out of 10,000 species of parasitic protozoa, **man harbours only about 70 species.**

■ GENERAL FEATURES

- The single protozoal cell performs all functions.
- Most of the protozoa are completely nonpathogenic but few may cause major diseases such as malaria, leishmaniasis and sleeping sickness.
- Protozoa like *Cryptosporidium parvum* and *Toxoplasma gondii* are being recognized as opportunistic pathogens in patients affected with human immunodeficiency virus (HIV) and in those undergoing immunosuppressive therapy.
- Protozoa exhibit wide range of size (1–150 μm), shape and structure; yet all possess essential common features.
- The differences between protozoa and metazoa are given in **Table 1.**

■ STRUCTURE

The typical protozoan cell is bounded by a trilaminar unit membrane, supported by a sheet of contractile fibrils enabling the cell to move and change in shape.

■ CYTOPLASM

It has two portions:

1. **Ectoplasm:** Outer homogeneous part that serves as the organ for locomotion and for engulfment of food by producing pseudopodia is called as the ectoplasm. It also helps in respiration, discharging waste material, and in providing a protective covering of cell.
2. **Endoplasm:** The inner granular portion of cytoplasm that contains nucleus is called endoplasm. The

Table 1: Differences between protozoa and metazoa

	Protozoa	Metazoa
Morphology	Unicellular; a single "cell-like unit"	Multicellular; a number of cells, making up a complex individual
Physiology	A single cell performs all the functions: reproduction, digestion, respiration, excretion, etc.	Each special cell performs a particular function
Example	Ameba	Tapeworm

endoplasm shows number of structures: the Golgi bodies, endoplasmic reticulum, food vacuoles and contractile vacuoles. Contractile vacuoles serve to regulate the osmotic pressure.

■ NUCLEUS

The nucleus is usually single but may be double or multiple; some species having as many as 100 nuclei in a single cell.

- The nucleus contains one or more nucleoli or a central karyosome.
- The chromatin may be distributed along periphery (peripheral chromatin) or as condensed mass around the karyosome.

■ TERMINOLOGIES USED IN PROTOZOOLOGY

- **Chromatoid body:** Extranuclear chromatin material is called chromatoid body (e.g. as found in *Entamoeba histolytica* cyst).
- **Karyosome:** It is a deoxyribonucleic acid (DNA) containing body, situated peripherally or centrally within the nucleus and found in intestinal ameba, e.g. *E. histolytica*, *E. coli*.
- **Kinetoplast:** Nonnuclear DNA present in addition to nucleus is called kinetoplast. It is seen in trypanosomes. Flagellum originates near the kinetoplast. Point of origin of flagellum is called as *basal body*.

- **Cilia:** These are fine, needle-like filaments, covering the entire surface of the body and are found in ciliates, e.g. *Balantidium coli*.
- **Trophozoite** (*trophos: nourishment*): Active feeding and growing stage of the protozoa is called the trophozoites. It derives nutrition from the environment by diffusion, pinocytosis and phagocytosis.

■ REPRODUCTION

Reproduction can be:

- Asexual reproduction
- Sexual reproduction.

Reproduction usually occurs asexually in protozoans; however, sexual reproduction occurs in ciliates and sporozoans.

Asexual Reproduction

- **Binary fission:** It is a method of asexual reproduction, by which a single parasite divides either longitudinally or transversally into two or more equal number of parasites. Mitotic division of nucleus is followed by division of the cytoplasm. In amoebae, division occurs along any plane, but in flagellates, division is along longitudinal axis and in ciliates, in the transverse plane (**Fig. 1**).
- **Multiple fission or schizogony:** *Plasmodium* exhibits schizogony, in which nucleus undergoes several successive divisions within the *schizont* to produce large number of *merozoites* (**Fig. 1**).
- **Endodyogeny:** Some protozoa like *Toxoplasma*, multiply by internal budding, resulting in the formation of two daughter cells.

Sexual Reproduction

- **Conjugation:** In ciliates, the sexual process is conjugation, in which two organisms join together and reciprocally exchange nuclear material (e.g. *Balantidium coli*).
- **Gametogony or syngamy:** In Sporozoa, male and female gametocytes are produced, which after fertilization form the zygote, which gives rise to numerous sporozoites by sporogony (e.g. *Plasmodium*).

■ LIFE CYCLE

- **Single host:** Protozoa like intestinal flagellates and ciliates require only one host, within which they multiply asexually in trophic stage and transfer from one host to another by the *cystic form*.
- **Second host:** In some protozoa like *Plasmodium*, asexual method of reproduction occurs in one host (man) and sexual method of reproduction in another host (mosquito).

■ CLASSIFICATION OF PROTOZOA

Protozoan parasites of medical importance have been classified into *kingdom* Protista, *subkingdom* Protozoa which is further divided into the following four phyla (**Table 2**):

1. Sarcostigophora
2. Apicomplexa
3. Microspora
4. Ciliophora

The important protozoan pathogens of human are summarized in **Table 3**.

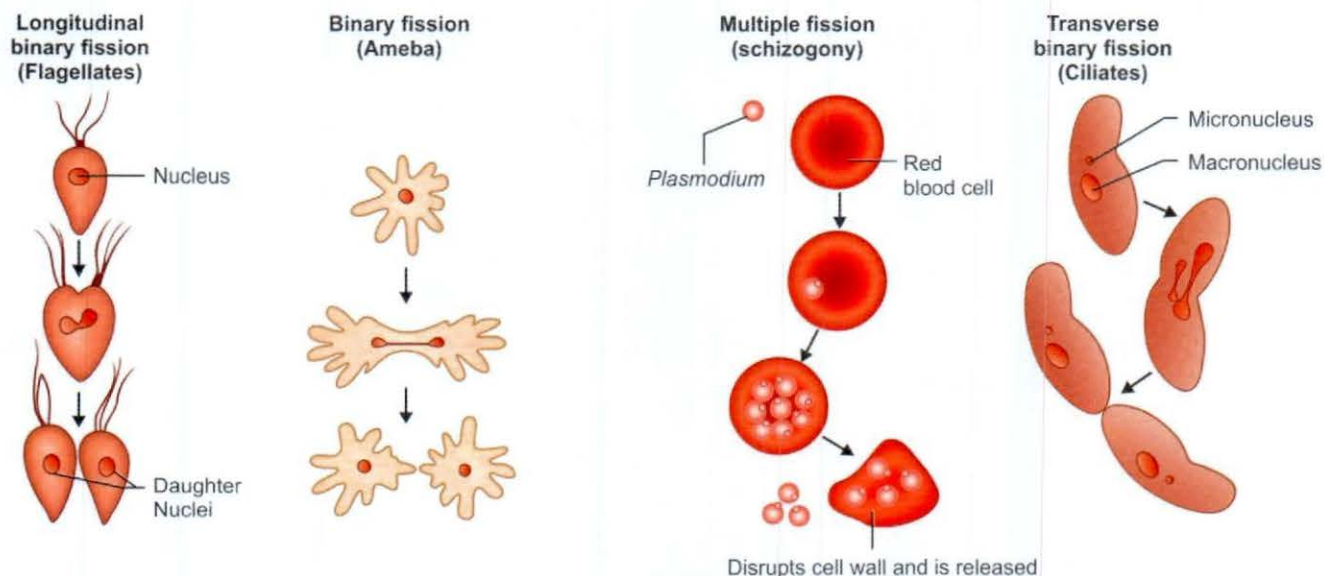


Fig. 1: Asexual reproduction in protozoans

Table 2: Classification of protozoa

Phylum	Subphylum	Superclass	Class	Subclass	Order	Suborder	Genus
<i>Sarcomastigophora</i>	Mastigophora (having one or more flagella)		Zoomastigophorea		Kinetoplastida	Trypanosomatina	• <i>Trypanosoma</i> • <i>Leishmania</i>
					Retortamonadida		• <i>Retortamonas</i> • <i>Chilomastix</i>
					Diplomonadida	Enteromonadina	<i>Enteromonas</i>
						Diplomonadina	<i>Giardia</i>
					Trichomonadida		• <i>Trichomonas</i> • <i>Dientamoeba</i>
	Sarcodina (pseudopodia present)	Rhizopoda	Lobosea	Gymnamebia	Amebida	Tubulina	• <i>Entamoeba</i> • <i>Endolimax</i> • <i>Iodamoeba</i>
						Acanthopodina	<i>Acanthamoeba</i>
						Schizopyrenida	<i>Naegleria</i>
<i>Apicomplexa</i>			Sporozoea	Coccidia	Eucoccidia	Eimeriina	• <i>Cryptosporidium</i> • <i>Isospora</i> • <i>Sarcocystis</i> • <i>Toxoplasma</i>
						Hemosporina	<i>Plasmodium</i>
						Piroplasmia	<i>Babesia</i>
<i>Ciliophora</i>			Kinetofragminophorea	Vestibuliferia	Trichostomastida	Trichostomatina	<i>Balantidium</i>
<i>Microspora</i>			Microsporea		Microsporidia	Apansporoblastina	• <i>Enterocytozoon</i> • <i>Encephalitozoon</i> • <i>Microsporium</i>

Table 3: Principal protozoan pathogens of man

Species	Habitat	Disease
<i>Entamoeba histolytica</i>	Large intestine	Amebic dysentery, amebic liver abscess
<i>Naegleria fowleri</i>	CNS	Amebic meningoencephalitis
<i>Acanthamoeba</i>	CNS, eye	Encephalitis, keratitis
<i>Giardia lamblia</i>	Small intestine	Malabsorption, diarrhea
<i>Trichomonas vaginalis</i>	Vagina, urethra	Vaginitis, urethritis
<i>Trypanosoma brucei</i>	Blood, lymph node, CNS	Sleeping sickness
<i>Trypanosoma cruzi</i>	Macrophage of bone marrow, nerves, heart, colon, etc.	Chagas disease
<i>Leishmania donovani</i>	Reticuloendothelial system	Kala-azar, Postkala-azar dermal leishmaniasis
<i>Leishmania tropica</i>	Skin	Cutaneous leishmaniasis (oriental sore)
<i>Leishmania braziliensis</i>	Naso-oral mucosa	Mucocutaneous leishmaniasis (espundia, chiclero's ulcer)
<i>Plasmodium</i> spp.	RBC	Malaria
<i>Babesia microti</i>	RBC	Babesiosis
<i>Isospora belli</i>	Intestine	Diarrhea in AIDS
<i>Cryptosporidium parvum</i>	Intestine	Diarrhea in AIDS
<i>Balantidium coli</i>	Large intestine	Dysentery

Abbreviations: AIDS, acquired immunodeficiency syndrome; CNS, central nervous system; RBC, red blood cell

Phylum Sarcomastigophora

Phylum Sarcomastigophora has been subdivided into two subphyla based on their modes of locomotion:

1. *Sarcodina* (*sarcos* meaning *flesh* or *body*): It includes those parasites, which have no permanent locomotory organs, but move about with the aid of temporary prolongations of the body called *pseudopodia* (e.g. amebae).
2. *Mastigophora* (*mastix*, meaning *whip* or *flagellum*): It includes those protozoa which possess whip-like flagella (e.g. *Trypanosoma* and *Trichomonas*).

Amebae

These protean animalcules can assume any shape and crawl along surfaces by means of foot-like projections called *pseudopodia* (literally meaning *false feet*). They are structurally very simple and are believed to have evolved

from the flagellates by the loss of the flagella. Two groups of amebae are of medical importance:

1. **Amebae of the alimentary canal:** The most important of these is *E. histolytica*, which causes intestinal and extraintestinal amebiasis. Amebae are also present in the mouth.
2. **Potentially pathogenic free-living amebae:** Several species of saprophytic amebae are found in soil and water. Two of these, (1) *Naegleria* and (2) *Acanthamoeba* are of clinical interest because they can cause eye infections and fatal meningoencephalitis.

Flagellates

These protozoa have whip-like appendages called *flagella* as the organs of locomotion. The fibrillar structure of flagella is identical with that of *spirochetes* and it has been suggested that they may have been derived from symbiotic spirochetes, which have become endoparasites. In some species, the flagellum runs parallel to the body surface, to which it is connected by a membrane called the *undulating membrane*. Flagellates parasitic for man are divided into two groups:

1. *Kinetoplastida*: These possess a kinetoplast from which a single flagellum arises. They are the **hemoflagellates** comprising the trypanosomes and *Leishmania*, which are transmitted by blood-sucking insects and cause systemic or local infections.
2. *Flagellates without kinetoplast*: These bear multiple flagella. *Giardia*, *Trichomonas* and other luminal flagellates belong to this group. Because most of them live in the intestine, they are generally called **intestinal flagellates**.

Phylum Apicomplexa

Phylum Apicomplexa was formerly known as *Sporozoa*. Members of this group possess, at some stage in their life cycle, a structure called the **apical complex** serving as the organ of attachment to host cells.

- They are tissue parasites.
- They have a complex life cycle with alternating sexual and asexual generations.
- To this group, belongs the malarial parasites (*Suborder*: Hemosporina, *Family*: Plasmodiidae), *Toxoplasma*, *Sarcocystis*, *Isospora*, and *Cryptosporidium* (*Under the Suborder*: Eimeriina), *Babesia* (*Under the Subclass*: Piroplasma) and the unclassified *Pneumocystis jirovecii*.

Phylum Ciliophora

These protozoa are motile by means of cilia, which cover their entire body surface. The only human parasite in this group is *Balantidium coli*, which rarely causes dysentery.

Phylum Microspora

Phylum Microspora contains many minute intracellular protozoan parasites, which frequently cause disease in immunodeficient subjects. They may also cause illness in the immunocompetent, rarely.

The zoological classification of protozoa is complex and is subject to frequent revisions. The classification described in the chapter is an abridged version of the classification proposed in 1980 by the Committee on Systematics and Evolution of the Society of Protozoologists, as applied to protozoa of medical importance.

IMPORTANT POINTS TO REMEMBER

- Only protozoan parasite found in lumen of human small intestine: *Giardia lamblia*.
- Largest protozoa: *Balantidium coli*.
- Most common protozoan parasite: *Toxoplasma gondii*.

KEY POINTS OF PROTOZOA

- Protozoa are single-celled, eukaryotic microorganisms consisting of cell membrane, cytoplasm and nucleus.
- Some protozoa have kinetoplast and flagella or cilia.
- Amebae move about with temporary prolongations of the body called *pseudopodia*.
- Hemoflagellates comprising of *Trypanosoma* and *Leishmania* possess a single flagellum and kinetoplast.
- Luminal flagellates like *Giardia* and *Trichomonas* bear multiple flagella without kinetoplast.
- *Balantidium coli* belongs to the Phylum Ciliophora, which is motile by cilia that cover its entire body surface.
- Trophozoites are active feeding and growing stage of protozoa.
- Cysts are resting or resistant stage of protozoa bounded by tough cell wall.
- Protozoa multiply by both asexual and sexual modes of reproduction.
- Malaria parasite, *Toxoplasma* and *Cryptosporidium* belong to phylum Apicomplexa or Sporozoa, which possess apical complex at some stage of their life cycle and have a complex life cycle with alternating sexual and asexual generations.
- Microspora are intracellular protozoan parasites, which cause disease in immunodeficient patients.

REVIEW QUESTIONS

1. Define Protozoa and describe their general characteristics.
2. Write short notes on:
 - a. Classification of Protozoa
 - b. Reproduction in Protozoa
3. Differentiate between Protozoa and Metazoa.

MULTIPLE CHOICE QUESTIONS

1. Protozoa belong to kingdom
 - a. Monera
 - b. Protista
 - c. Plantae
 - d. Animalia
2. All are intercellular parasites except
 - a. *Leishmania*
 - b. *Plasmodium*
 - c. *Toxoplasma*
 - d. None of the above
3. Non-nuclear DNA present in addition to nucleus in protozoan parasite is
 - a. Chromatid body
 - b. Karyosome
 - c. Kinetoplast
 - d. Basal body
4. *Entamoeba histolytica* trophozoites multiply by
 - a. Binary fission
 - b. Schizogony
 - c. Gametogony
 - d. All of the above
5. In humans, malarial parasites multiply by
 - a. Binary fission
 - b. Budding
 - c. Gametogony
 - d. Schizogony
6. Which of the following is not a flagellate
 - a. *Naegleria*
 - b. *Leishmania*
 - c. *Giardia*
 - d. *Dientamoeba*

Answer

1. b 2. d 3. c 4. a 5. d 6. a

Amebae

■ INTRODUCTION

The word ameba is derived from the Greek word “amibe” meaning change.

Amebae are structurally simple protozoans which have no fixed shape. They are classified under *Phylum: Sarcostigophora*, *Subphylum: Sarcodina*, *Superclass: Rhizopoda* and *Order: Amebida*.

- The cytoplasm of ameba is bounded by a membrane and can be differentiated into an **outer ectoplasm** and **inner endoplasm**.
- **Pseudopodia** are formed by the ameba by thrusting out ectoplasm, followed by endoplasm. These are employed for locomotion and engulfment of food by phagocytosis.
- **Reproduction** occurs by fission and budding. Cyst is formed in unfavorable conditions and is usually the infective form for vertebrate host (e.g. *Entamoeba histolytica*).
- Amebae are classified as either **free-living** or **intestinal amebae** (Table 1).
- A few of the free-living amebae occasionally act as human pathogens producing meningoencephalitis and other infections, e.g. *Naegleria* and *Acanthamoeba*.
- The parasitic amebae inhabit the alimentary canal.

Table 1: Classification of amebae

Intestinal amebae	Free-living amebae
<ul style="list-style-type: none"> • <i>Entamoeba histolytica</i> • <i>Entamoeba dispar</i> • <i>Entamoeba coli</i> • <i>Entamoeba polecki</i> • <i>Entamoeba hartmanni</i> • <i>Entamoeba gingivalis</i> • <i>Endolimax nana</i> • <i>Iodamoeba butschlii</i> 	<ul style="list-style-type: none"> • <i>Naegleria fowleri</i> • <i>Acanthamoeba</i> spp. • <i>Balamuthia mandrillaris</i>
Note: All intestinal amebae are nonpathogenic, except <i>Entamoeba histolytica</i>	Note: All free-living amebae are opportunistic pathogens

■ ENTAMOEBA HISTOLYTICA

History and Distribution

E. histolytica was discovered by Lösch in 1875, who demonstrated the parasite in the dysenteric feces of a patient in St. Petersburg in Russia.

- In 1890, William Osler reported the case of a young man with dysentery, who later died of liver abscess.
- Councilman and Lafleur in 1891 established the pathogenesis of intestinal and hepatic amebiasis and introduced the terms “**amebic dysentery**” and “**amebic liver abscess**”.
- *E. histolytica* is worldwide in prevalence, being much more common in the tropics than elsewhere. It has been found wherever sanitation is poor, in all climatic zones from Alaska (61°N) to Straits of Magellan (52°S).
- It has been reported that about 10% of world population and 50% of the inhabitants of developing countries may be infected with the parasite.
- The infection is not uncommon even in affluent countries, about 1% of Americans being reported to be infected.
- While the majority of infected humans (80–99%) are asymptomatic, invasive amebiasis causes disabling illness in an estimated 50 million of people and causes 50,000 deaths annually, mostly in the tropical belt of Asia, Africa and Latin America.
- It is the third leading parasitic cause of mortality, after malaria and schistosomiasis.
- Epidemiologically, India can be divided into three regions, depending on the prevalence of intestinal amebiasis:
 1. **High prevalence states (>30%)**: Chandigarh, Tamil Nadu and Maharashtra.
 2. **Moderate prevalence states (10–30%)**: Punjab, Rajasthan, Uttar Pradesh, Delhi, Bihar, Assam, West Bengal, Andhra Pradesh, Karnataka and Kerala.
 3. **Low prevalence states (<10%)**: Haryana, Gujarat, Himachal Pradesh, Madhya Pradesh, Odisha, Sikkim and Puducherry.

Morphology

E. histolytica occurs in three forms (Figs 1A to E):

1. Trophozoite
2. Precyst
3. Cyst.

Trophozoite

Trophozoite is the vegetative or growing stage of the parasite (Fig. 1A). It is the only form present in tissues.

- It is irregular in shape and varies in size from 12–60 μm ; average being 20 μm .
- It is large and actively motile in freshly-passed dysenteric stool, while smaller in convalescents and carriers.
- The parasite, as it occurs free in the lumen as a commensal is generally smaller in size, about 15–20 μm and has been called the *minuta form*.
- **Cytoplasm:** Outer ectoplasm is clear, transparent and refractile. Inner endoplasm is finely granular, having a *ground glass appearance*. The endoplasm contains nucleus, food vacuoles, erythrocytes, occasionally leukocytes and tissue debris.
- **Pseudopodia** are finger-like projections formed by sudden jerky movements of ectoplasm in one direction, followed by the streaming in of the whole endoplasm.
- Typical ameboid motility is a *crawling* or *gliding movement* and not a free swimming one. The direction of movement may be changed suddenly, with another pseudopodium being formed at a different site, when the whole cytoplasm flows in the direction of the new pseudopodium. The cell has to be attached to some surface or particle for it to move. In culture tubes, the trophozoites may be seen crawling up the side of the glass tube.
- Pseudopodia formation and motility are inhibited at low temperatures.
- **Nucleus** is spherical 4–6 μm in size and contains *central karyosome*, surrounded by clear halo and anchored to the nuclear membrane by fine radiating fibrils called the *linin network*, giving a *cartwheel appearance*. The nucleus is not clearly seen in the living trophozoites, but can be clearly demonstrated in preparations stained with iron hematoxylin.

- The nuclear membrane is lined by a rim of chromatin distributed evenly as small granules.
- The trophozoites from acute dysenteric stools often contain phagocytosed erythrocytes. This feature is diagnostic as phagocytosed red cells are not found in any other commensal intestinal amebae.
- The trophozoites divide by **binary fission** in every 8 hours.
- Trophozoites survive up to 5 hours at 37°C and are killed by drying, heat and chemical sterilization. Therefore, the infection is not transmitted by trophozoites. Even if live trophozoites from freshly-passed stools are ingested, they are rapidly destroyed in stomach and cannot initiate infection.

Precystic Stage

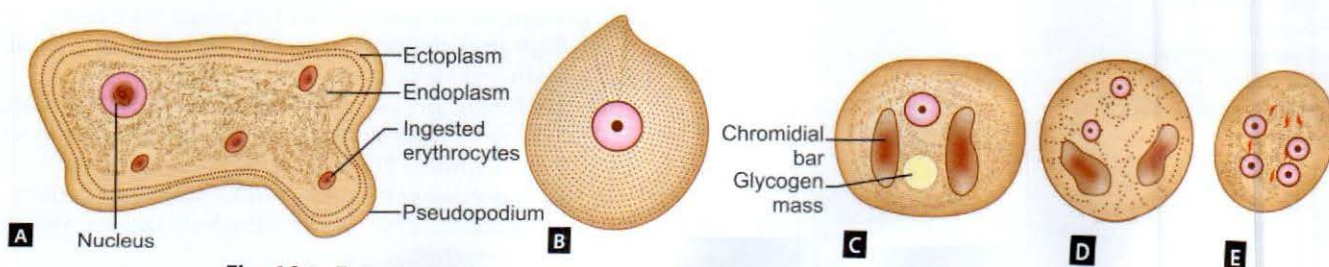
Trophozoites undergo encystment in the intestinal lumen. Encystment does not occur in the tissues nor in feces outside the body.

- Before encystment, the trophozoite extrudes its food vacuoles and becomes round or oval, about 10–20 μm in size. This is the precystic stage of the parasite (Fig. 1B).
- It contains a **large glycogen vacuole** and two **chromatid bars**.
- It then secretes a highly retractile cyst wall around it and becomes cyst.

Cystic Stage

The cyst is spherical in shape about 10–20 μm in size.

- The early cyst contains a single nucleus and two other structures: (1) a **mass of glycogen** and (2) 1–4 **chromatoid bodies** or **chromidial bars**, which are cigar-shaped refractile rods with rounded ends (Fig. 1C). The chromatoid bodies are so called because they stain with hematoxylin, like chromatin.
- As the cyst matures, the glycogen mass and chromidial bars disappear and the nucleus undergoes two successive mitotic divisions to form two (Fig. 1D) and then four nuclei. The mature cyst is, thus **quadrinucleate** (Fig. 1E).
- The cyst wall is a highly refractile membrane, which makes it highly resistant to gastric juice and unfavorable environmental conditions.



Figs 1A to E: *Entamoeba histolytica*. (A) Trophozoite; (B) Precystic stage; (C) Uninucleate cyst; (D) Binucleate cyst; and (E) Mature quadrinucleate cyst

- The nuclei and chromidial bodies can be made out in unstained films, but they appear more prominently in stained preparations.
- With iron hematoxylin stain, nuclear chromatin and chromatoid bodies appear **deep blue or black**, while the glycogen mass appears unstained.
- When stained with iodine, the glycogen mass appears **golden brown**, the nuclear chromatin and karyosome bright yellow, and the chromatoid bodies appear as clear space, being unstained.

Life Cycle

E. histolytica passes its life cycle only in one host man (Flow chart 1 and Fig. 2).

Infective Form

Mature quadrinucleate cyst passed in feces of convalescents and carriers. The cysts can remain viable under moist conditions for about 10 days.

Mode of Transmission

Man acquires infection by swallowing food and water contaminated with **cysts**.

- As the cyst wall is resistant to action of gastric juice, the cysts pass through the stomach undamaged and enter the small intestine.
- **Excystation:** When the cyst reaches cecum or lower part of the ileum, due to the alkaline medium, the cyst wall is damaged by trypsin, leading to excystation.

Flow chart 1: Life cycle of *Entamoeba histolytica* (schematic)

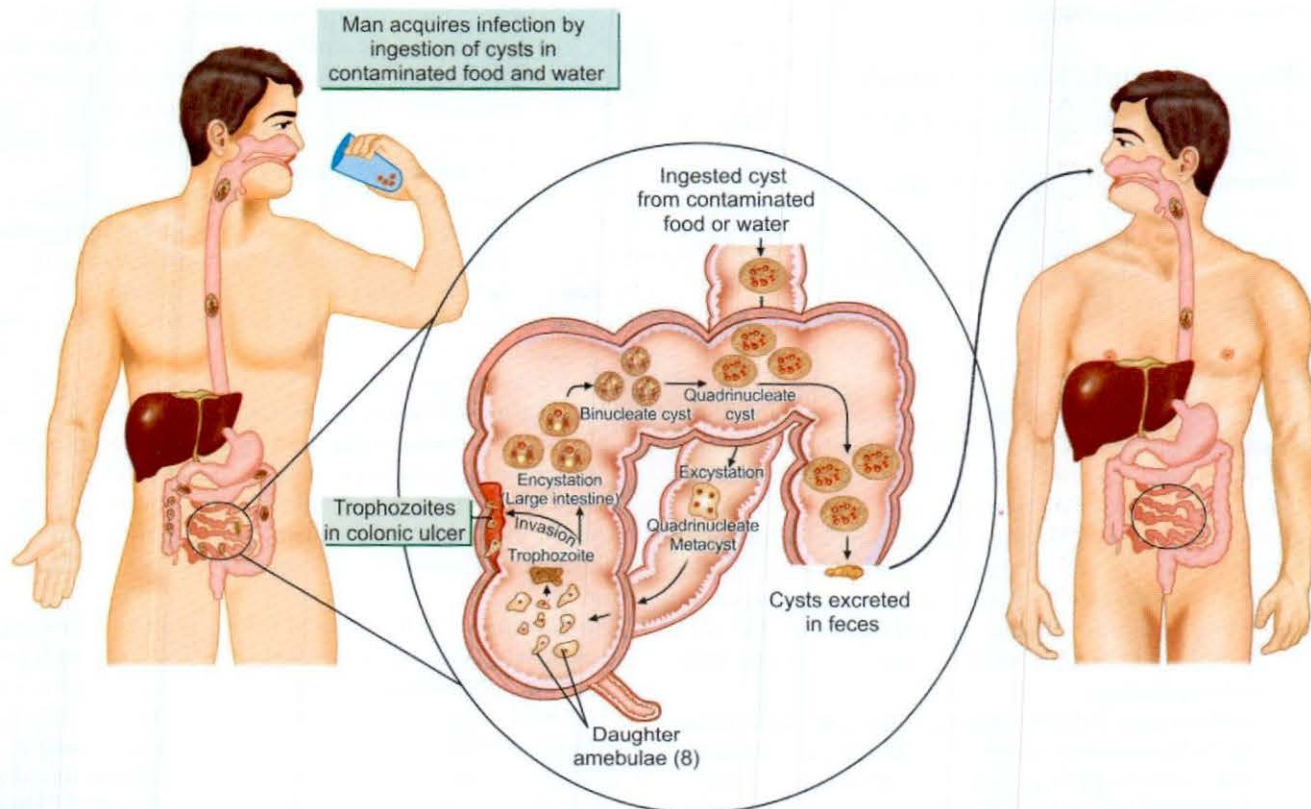
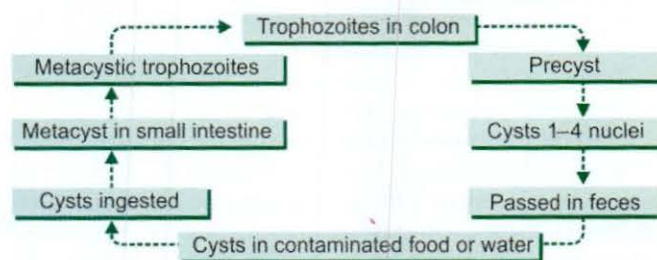


Fig. 2: Life cycle of *Entamoeba histolytica*

- The cytoplasm gets detached from the cyst wall and ameboid movements appear causing a tear in the cyst wall, through which *quadrinucleate ameba* is liberated. This stage is called the **metacyst** (Fig. 2).
- **Metacystic trophozoites:** The nuclei in the metacyst immediately undergo division to form **eight nuclei**, each of which gets surrounded by its own cytoplasm to become **eight small amebulae** or *metacystic trophozoites*.
- If excystation takes place in the small intestine, the metacystic trophozoites do not colonize there, but are carried to the cecum.
- The optimal habitat for the metacystic trophozoite is the submucosal tissue of **cecum and colon**, where they lodge in the glandular crypts and grow by binary fission (Fig. 2).
- Some develop into precystic forms and cysts, which are passed in feces to repeat the cycle.
- The entire life cycle is, thus completed in one host.

In most of the cases, *E. histolytica* remains as a commensal in the large intestine without causing any ill effects. Such persons become carriers or asymptomatic cyst passers and are responsible for maintenance and spread of infection in the community. Sometimes, the infection may be activated and clinical disease ensues. Such latency and reactivation are the characteristics of amebiasis.

Pathogenesis and Clinical Features

- *E. histolytica* causes intestinal and extraintestinal amebiasis.
- **Incubation period** is highly variable. On an average, it ranges from 4 days to 4 months.
- Amebiasis can present in different forms and degree of severity, depending on the organ affected and the extent of damage caused.

Intestinal Amebiasis

The lumen-dwelling amebae do not cause any illness. They cause disease only when they invade the intestinal tissues. This happens only in about 10% of cases of infection, the remaining 90% being **asymptomatic**.

- Not all strains of *E. histolytica* are pathogenic or invasive. Differentiation between pathogenic and nonpathogenic strains can be made by susceptibility to complement-mediated lysis and phagocytic activity or by the use of genetic markers or monoclonal antibodies and zymodeme analysis.
 - **Adherence:** Amebic lectins (**Gal/GalNAc lectin**, 260 kDa surface protein of *E. histolytica*) mediates adherence to glycogen receptors of colonic mucosa.
 - **Cytolysis:** The metacystic trophozoites penetrate the columnar epithelial cells in the **crypts of Lieberkuhn** in the colon. Penetration of the ameba is facilitated

Box 1: Factors affecting virulence of *Entamoeba histolytica*

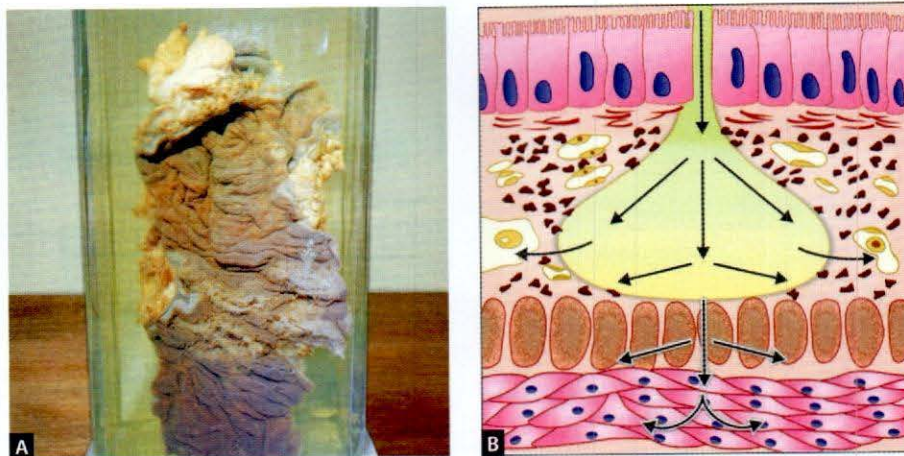
- Amebic cysteine proteinases, which inactivate complement factor C3 and degrade cellular matrix and IgA is an important virulence factor.
- Amebic lectin (Gal/GalNAc lectin) and ionophore protein are other virulence factors.
- Host factors such as stress, malnutrition, alcoholism, corticosteroid therapy and immunodeficiency influence the course of infection.
- Glycoproteins in colonic mucus block the attachment of trophozoites to epithelial cells, therefore alteration in the nature and quality of colonic mucus may influence virulence.
- Virulence may also be conditioned by the bacterial flora in the colon.
- Based on electrophoretic mobility of six isoenzymes (acetylglucosaminidase, aldolase, hexokinase, NAD-diaphorase, peptidase and phosphoglucomutase), *E. histolytica* strains can be classified into at least 22 zymodemes. Of these only nine are invasive and the rest are noninvasive commensals.
- It has been proposed that pathogenic and nonpathogenic strains though morphologically identical may represent two distinct species: (1) the pathogenic strains being *E. histolytica* and (2) the nonpathogenic strains reclassified as *E. dispar*. Trophozoites of *E. dispar* contain bacteria, but no red blood cells (RBCs).

by the motility of the trophozoites and the tissue lytic activity of the **amebic cysteine proteases** like histolysin, cathepsin B, metallocollagenase. Cysteine proteases degrade the extracellular matrix (ECM) component of host cells and immunoglobulin A (IgA) (Box 1) and also inactivates complement C3.

- **Amebapores** are ionophore proteins of ameba capable of inserting ion channels into liposomes causing lysis of target cell membrane of host cells.

Tissue necrosis is also caused by the lysosomal enzymes of the inflammatory cells surrounding the trophozoites and proinflammatory cytokines like interleukin-8 (IL-8) and tumor necrosis factor- α (TNF- α) released from these cells.

- **Mucosal penetration** by the ameba produces discrete ulcers with **pinhead center** and **raised edges**. Sometimes, the invasion remains superficial and heals spontaneously. More often, the ameba penetrates to submucosal layer and multiplies rapidly, causing lytic necrosis and thus forming an abscess. The abscess breaks down to form an ulcer.
- **Amebic ulcer** is the typical lesion seen in intestinal amebiasis (Fig. 3). The ulcers are **multiple** and are confined to the colon, being most numerous in the **cecum** and next in the **sigmoidorectal region**. The intervening mucous membrane between the ulcers remains healthy.
- Ulcers appear initially on the mucosa as **raised nodules with pouting edges** measuring pinhead to 1 inch. They later break down discharging brownish necrotic material containing large numbers of trophozoites.



Figs 3A and B: (A) Intestinal amebiasis: Specimen showing amebic ulcer in colon; (B) Flask-shaped amebic ulcer

- The typical amebic ulcer is **flask-shaped** in cross section, with mouth and neck being narrow and base large and rounded.
- Multiple ulcers may coalesce to form large necrotic lesions with **ragged** and **undermined edges** and are covered with brownish slough. Base is formed by muscular coat (**Figs 3A and B**).
- The ulcers generally do not extend *deeper than submucosal layer*, but amebae spread laterally in the submucosa causing extensive undermining and patchy mucosal loss. Amebae are seen at the periphery of the lesions and extending into the surrounding healthy tissues. Occasionally, the ulcers may involve the muscular and serous coats of the colon, causing perforation and peritonitis. Blood vessel erosion may cause hemorrhage.
- The superficial lesions generally heal without scarring, but the deep ulcers form scars which may lead to **strictures**, partial obstruction and thickening of the gut wall.
- **Ameboma:** Occasionally, a granulomatous pseudotumoral growth may develop on the intestinal wall by rapid invasion from a chronic ulcer. This amebic granuloma or ameboma may be mistaken for a malignant tumor. Amebomas are most frequent at cecum and rectosigmoid junction (**Box 2**).

Systemic manifestations of ameboma are rectal tenesmus, high fever, abdominal discomfort, anorexia and nausea.

Clinical features of intestinal amebiasis: The clinical picture covers a wide spectrum from noninvasive carrier state to fulminant colitis (**Box 3**).

- The incubation period is highly variable from 1–4 months.
- The clinical course is characterized by prolonged latency, relapses and intermissions.
- The typical manifestation of intestinal amebiasis is *amebic dysentery*. This may resemble bacillary dysentery, but can be differentiated on clinical and laboratory grounds.

Box 2: Lesions in chronic intestinal amebiasis

- Small superficial ulcers involving only the mucosa.
- Round or oval-shaped with ragged and undermined margin and flask-shaped in cross section.
- Marked scarring of intestinal wall with thinning, dilatation and sacculation.
- Extensive adhesions with the neighboring viscera.
- Formation of tumor-like masses of granulation tissue (ameboma).

Box 3: Complications and sequelae of intestinal amebiasis

- **Fulminant amebic colitis:**
 - Toxic megacolon
 - Perianal ulceration
 - Perforation and generalized peritonitis
- **Amebic appendicitis**
- **Ameboma**
- **Extraintestinal amebiasis:**
 - Amebic hepatitis
 - Amebic liver abscess
 - Pulmonary amebiasis
 - Cerebral amebiasis
 - Splenic abscess
 - Cutaneous amebiasis
 - Genitourinary amebiasis
 - Pericardial amebiasis

Compared to bacillary dysentery, it is usually insidious in onset and the abdominal tenderness is less and localized (**Table 2**).

- The stools are large, foul-smelling and brownish black, often with blood streaked mucus intermingled with feces. The red blood cells (RBCs) in stools are clumped and reddish-brown in color. Cellular exudate is scanty. **Charcot-Leyden crystals** are often present. *E. histolytica* trophozoites can be seen containing ingested erythrocytes.
- The patient is usually afebrile and nontoxic.

Table 2: Differential features of amebic and bacillary dysentery

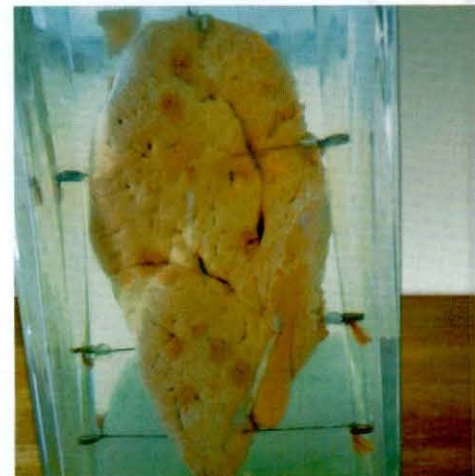
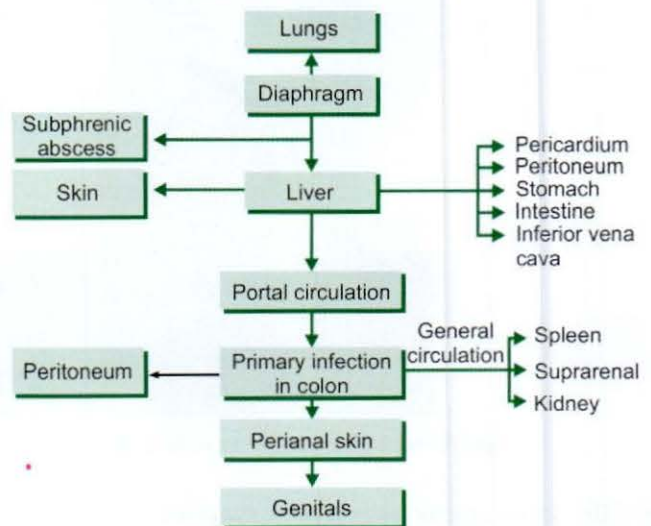
Features	Amebic dysentery	Bacillary dysentery
<i>Clinical</i>		
Onset	Slow	Acute
Fever	Absent	Present
Toxicity	Absent	Present
Abdominal tenderness	Localized	Generalized
Tenesmus	Absent	Present
<i>Stool</i>		
Frequency	6–8 per day	Over 10 per day
Odor	Offensive	Nil
Color	Dark red	Bright red
Nature	Feces mixed with blood and mucus	Blood and mucus with little or no feces
Consistency	Not adherent	Adherent to container
Reaction	Acid	Alkaline
<i>Microscopy</i>		
Cellular exudates	Scanty	Abundant
Red blood cells	Clumped, yellowish brown	Discrete or in rouleaux, bright red
Macrophages	Few	Several, some with ingested red blood cells
Eosinophils	Present	Absent
Charcot-Leyden crystals	Present	Absent
Motile bacteria	Present	Absent
Ameba	Motile trophozoites with ingested red blood cells	Absent

- In fulminant colitis, there is confluent ulceration and necrosis of colon. The patient is febrile and toxic.
- Intestinal amebiasis does not always result in dysentery. Quite often, there may be only diarrhea or vague abdominal symptoms popularly called “uncomfortable belly” or “growling abdomen”.
- Chronic involvement of the cecum causes a condition simulating appendicitis.

Extraintestinal Amebiasis

The various extraintestinal lesions in amebiasis have been summarized in **Flow chart 2** and depicted in **Figure 4**.

Hepatic amebiasis: Hepatic involvement is the most common extraintestinal complication of amebiasis. Although trophozoites reach the liver in most cases of amebic dysentery, only in a small proportion do they manage to lodge and

Flow chart 2: Sites affected in amebiasis**Fig. 4:** Specimen showing amebic liver abscess

multiply there. In the tropics, about 2–10% of the individuals infected with *E. histolytica* suffer from hepatic complications.

- The history of amebic dysentery is absent in more than 50% of cases.
- Several patients with amebic colitis develop an enlarged tender liver without detectable impairment of liver function or fever. This acute hepatic involvement (**amebic hepatitis**) may be due to repeated invasion by amebae from an active colonic infection or to toxic substances from the colon reaching the liver. It is probable that liver damage may not be caused directly by the amebae, but by lysosomal enzymes of lysed polymorphonuclear neutrophils and monocytes and cytokines from the inflammatory cells surrounding the trophozoites.

Amebic liver abscess:

- In about 5–10% of persons with intestinal amebiasis, *liver abscesses* may ensue (**Fig. 4**). The center of the abscess contains *thick chocolate brown pus (anchovy sauce pus)*, which is liquefied necrotic liver tissue. It is bacteriologically sterile and free of ameba. At the periphery, there is almost normal liver tissue, which contains invading ameba (**Flow chart 3A**).
- Liver abscess may be multiple or more often solitary, usually located in the upper right lobe of the liver. Cardinal signs of amebic liver abscess is painful hepatomegaly. Fever is present in most cases. Anorexia, nausea, weight loss and fatigue may also be present. About third-fourth cases of amebic liver abscess have leukocytosis ($>10,000/\mu\text{L}$) and increased serum transaminases. Jaundice develops only when lesions are multiple or when they press on the biliary tract.
- Untreated abscesses tend to rupture into the adjacent tissues through the diaphragm into the lung or pleural cavity, pericardium, peritoneal cavity, stomach, intestine, or inferior vena cava or externally through abdominal wall and skin.
- Amebic liver abscess is 10 times more frequent in adults than in children and three times more frequent in males than in females.

Pulmonary amebiasis: Very rarely, primary amebiasis of the lung may occur by direct hematogenous spread from the colon bypassing the liver, but it most often follows extension

of hepatic abscess through the diaphragm and therefore, the lower part of the right lung is the usual area affected (**Fig. 5**).

- Hepatobronchial fistula usually results with expectoration of *chocolate brown sputum*. Amebic empyema develops less often.
- The patient presents with severe pleuritic chest pain, dyspnea and nonproductive cough.

Metastatic amebiasis: Involvement of distant organs is by hematogenous spread and through lymphatics. Abscesses in **kidney, brain, spleen** and **adrenals** have been noticed. Spread to brain leads to severe destruction of brain tissue and is fatal.

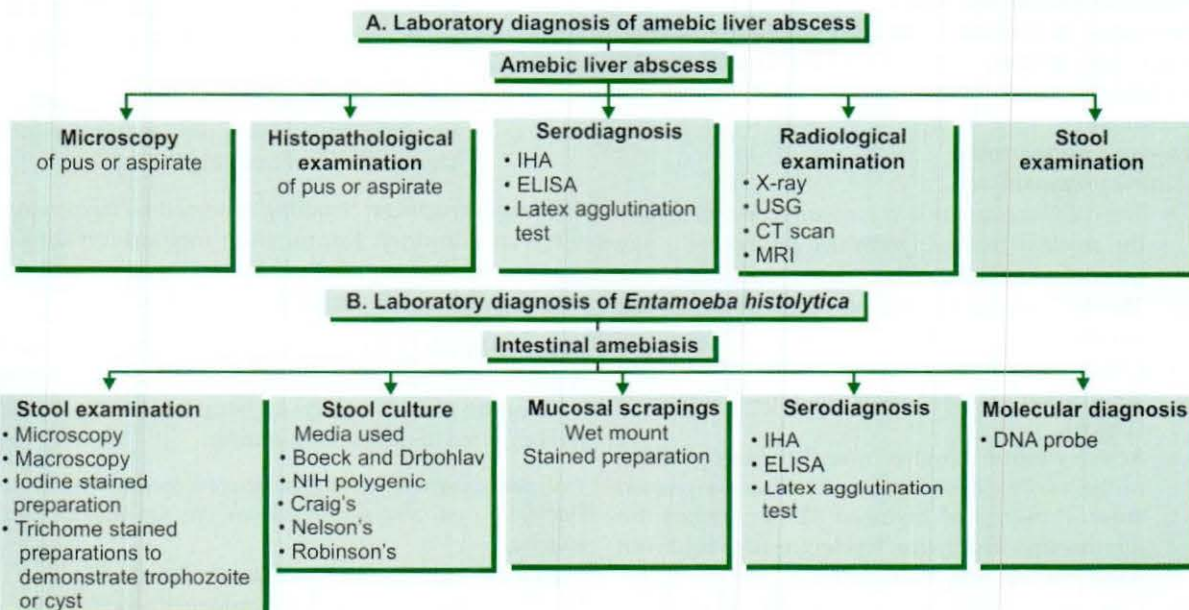
Cutaneous amebiasis: It occurs by direct extension around anus, colostomy site, or discharging sinuses from amebic abscesses. Extensive gangrenous destruction of the skin occurs. The lesion may be mistaken for condyloma or epithelioma.

Genitourinary amebiasis: The prepuce and glans are affected in penile amebiasis which is acquired through anal intercourse. Similar lesions in females may occur on vulva, vagina, or cervix by spread from perineum. The destructive ulcerative lesions resemble carcinoma.

Laboratory Diagnosis*Diagnosis of Intestinal Amebiasis*

Stool examination: Intestinal amebiasis has to be differentiated from bacillary dysentery (**Table 2**). The stool

Flow charts 3A and B: (A) Laboratory diagnosis of amebic liver abscess; (B) Laboratory diagnosis of *Entamoeba histolytica*



Abbreviations: CT, computed tomography; DNA, deoxyribonucleic acid; ELISA, enzyme-linked immunosorbent assay; IHA, indirect hemagglutination; MRI, magnetic resonance imaging; USG, ultrasonography

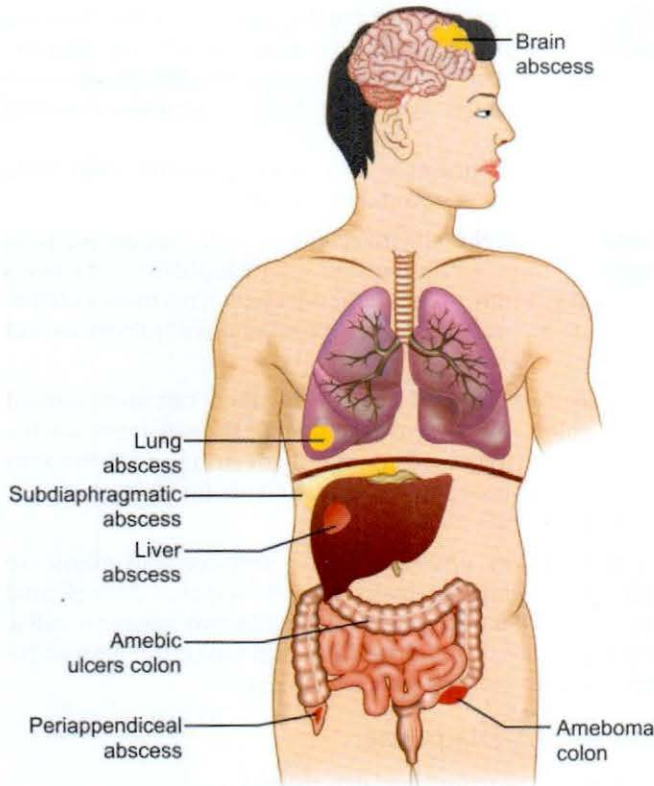


Fig. 5: Lesions of amebiasis

should be collected into a wide mouth container and examined without delay. It should be inspected macroscopically as well as microscopically (**Flow chart 3B**).

- **Macroscopic appearance:** The stool is foul-smelling, copious, semiliquid, brownish-black in color and intermingled with blood and mucus. It does not adhere to the container.

- **Microscopic appearance:**

- **Saline preparation:**

- The cellular exudate is scanty and consists of only the nuclear masses (**pyknotic bodies**) of a few pus cells, epithelial cells and macrophages.
- The RBCs are in clumps and yellow or brown-red in color.
- **Charcot-Leyden crystals** are often present. These are diamond-shaped, clear and refractile crystals (**Fig. 6**).
- Actively motile trophozoites throwing pseudopodia can be demonstrated in freshly-passed stool. Presence of ingested RBCs clinches the identity of *E. histolytica*. Nucleus is not visible but a faint outline may be detected.
- Cyst has a smooth and thin cell wall and contains round refractile chromatoid bars. Glycogen mass is not visible.

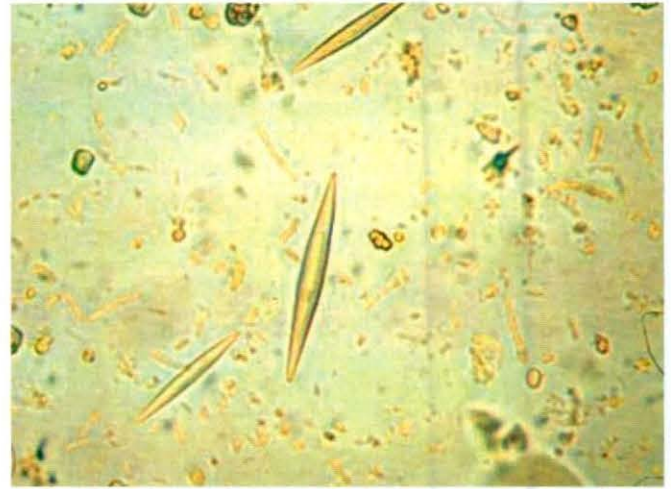


Fig. 6: Charcot-Leyden crystals

- **Iodine preparation:**

- For the demonstration of cysts or dead trophozoites, stained preparations may be required for the study of the nuclear character. Iodine-stained preparation is commonly employed for this purpose. The trophozoite of *E. histolytica* stains yellow to light brown. Nucleus is clearly visible with a central karyosome. The cytoplasm of the cystic stage shows smooth and hyaline appearance. Nuclear chromatin and karyosome appear bright yellow. Glycogen masses stain golden brown and chromatoid bars are not stained. Trichrome stain is useful to demonstrate intracellular features of both trophozoites and cysts.
- Since excretion of cysts in the stool is often intermittent, at least three consecutive specimens should be examined (**Fig. 7**).

Mucosal scrapings: Scraping obtained by sigmoidoscopy is often contributory. Examination method includes a direct wet mount and iron hematoxylin and immunofluorescent staining with anti-*E. histolytica* antibodies.

Stool culture: Stool culture is a more sensitive method in diagnosing chronic and asymptomatic intestinal amebiasis.

Culture of stools yields higher positivity for *E. histolytica* as compared to direct examination.

Polyxenic culture is done in enriched medium which contains bacteria, protozoa, serum, starch, etc. for nourishment of the ameba.

Media used for polyxenic culture include:

- Boeck and Drbohlav's biphasic medium
- NIH polygenic medium
- Craig's medium

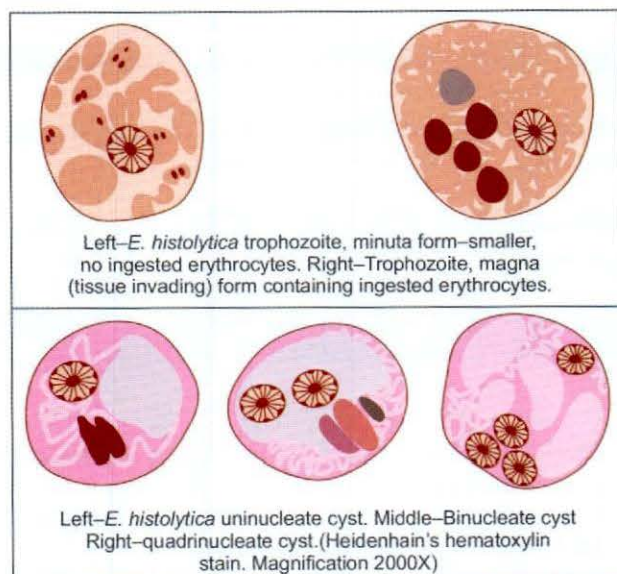


Fig. 7: *Entamoeba histolytica* as it appears in laboratory specimen

- Nelson's medium
- Robinson's medium
- Balamuth's medium.

Axenic culture is done in medium that does not require presence of other microorganisms. Diamond's axenic medium is commonly used. Axenic cultures are used for:

- Studies of pathogenicity
- Antigenic characterization
- Drug sensitivity of amoeba.

To obtain growth in these media 50 mg of formed stools or 0.5 mL of liquid stool containing cyst or trophozoites of amoeba is inoculated and incubated at 37°C.

Serodiagnosis: Serological tests become positive only in invasive amoebiasis.

Antibody detection: Amoebic antibodies appear in serum only in late stages of intestinal amoebiasis. Test for antibodies in serum help in diagnosis of mainly extraintestinal infections.

Serological tests include indirect hemagglutination assay (IHA), indirect fluorescent antibody (IFA), enzyme-linked immunosorbent assay (ELISA), counter-current immunoelectrophoresis (CIEP) and latex agglutination tests. Serum with antibody titer of 1:256 or more by IHA and 1:200 by IFA are considered to be significant.

Amoebic antigen detection: Amoebic antigen in serum are detected only in patients with active infections and disappears after clinical cure. Antigen like Lipophosphoglycan (LPG) **amoebic lectin**, serine rich *E. histolytica* protein (SREHP) are detected using monoclonal antibodies by ELISA.

Stool antigen detection: Detection of **coproantigen** of *E. histolytica* in stool by microwell ELISA is more sensitive than stool examination and culture.

Commercially available ELISA tests like **Techlab *E. histolytica* II** to detect *Entamoeba* antigen are more easily performed and are being used with increasing frequency.

Molecular diagnosis: Recently, deoxyribonucleic acid (DNA) probes and radioimmunoassay have been used to detect *E. histolytica* in stool. It is a rapid and specific method.

Real-time polymerase chain reaction (RT-PCR) is a sensitive test for detection of *E. histolytica* from pus of liver abscess.

Diagnosis of Extraintestinal Amoebiasis

Microscopy: Microscopic examination of pus aspirated from liver abscess may demonstrate trophozoite of *E. histolytica* in less than 20% cases. In case of liver abscess, when diagnostic aspiration is done, the pus obtained from the center of the abscess may not contain amoeba as they are confined to the periphery. The fluid draining after a day or two is more likely to contain the trophozoite. Aspirates from the margins of the abscess would also show the trophozoites. Cysts are never seen in extraintestinal lesions.

Liver biopsy: Trophozoite of *E. histolytica* may be demonstrated in liver biopsy specimen, in case of hepatic amoebiasis or amoebic hepatitis.

Serological test: Serological test, are of immense value in the diagnosis of hepatitis amoebiasis.

Craig (1928) was the first to report a **complement fixation test** in amoebiasis. Subsequently a number of different serological tests have been developed including:

- **Indirect hemagglutination (IHA)**
- **Latex agglutination (LA)**
- **Gel diffusion precipitation (GDP)**
- **Cellulose acetate membrane precipitation (CAP) test**
- **Counter-current immunoelectrophoresis (CIE)**
- **Enzyme linked immunosorbent assay (ELISA)**

While IHA and LA are highly sensitive, they often give false-positive results. They remain positive for several years even after successful treatment. Gel precipitation tests are less sensitive, but more specific. ELISAs are both sensitive and specific and tests like GDP and CIE become negative within 6 months of successful treatment.

Stool examination: It is not of much value as *E. histolytica* cyst can be detected in stool in less than **15%** cases of amoebic hepatitis.

Radiological examination:

- **On X-ray**, the right lobe of the liver is generally found to be situated at a higher level.

- **Radioisotope scan** of the liver may locate the space-occupying lesions.
- Ultrasonography (USG), computed tomography (CT) scan, or magnetic resonance imaging (MRI) of liver may be found useful in detection of amebic liver abscess (**Flow chart 3A**).

The diagnosis of amebic liver abscess is based on the detection (generally by USG or CT) of one or more space-occupying lesions in the liver and a positive serologic test for antibodies against *E. histolytica* antigens. When a patient has a space-occupying lesion of the liver and a positive amebic serology, it is highly sensitive (>94%) and highly specific (>95%) for the diagnosis of amebic liver abscess (**Flow chart 3A**).

Immunity

Infection with invasive strains includes both humoral and cellular immune responses. Local and systemic antibodies can be demonstrated within a week of invasive infection.

All classes of immunoglobulins are produced but IgG is predominant.

Immunoglobulin A plays an important role in humoral immunity to *E. histolytica* to resist Gal/GalNAc lectin.

Infection confers some degree of protection as evidenced by the very low frequency of recurrence of invasive colitis and liver abscess in endemic areas. The course and severity of amebiasis does not seem to be affected by human immunodeficiency virus (HIV) infection. Serological response is hardly ever seen in infection with noninvasive zymodemes.

Treatment

Three classes of drug are used in the treatment of amebiasis:

1. **Luminal amebicides:** Diloxanide furoate, iodoquinol, paromomycin and tetracycline act in the intestinal lumen but not in tissues.
2. **Tissue amebicides:** Emetine, chloroquine, etc. are effective in systemic infection, but less effective in the intestine. Dosage of chloroquine in amebic liver abscess is 1 g for 2 days followed by 5 g daily for 3 weeks.
3. **Both luminal and tissue amebicides:** Metronidazole and related compounds like tinidazole and ornidazole act on both sites and are the drug of choice for treating amebic colitis and amebic liver abscess.

Note: Although metronidazole and tinidazole act on both the sites but neither of them reach high levels in the gut lumen; therefore, patients with amebic colitis or amebic liver abscess should also receive treatment with a luminal agent (paromomycin or iodoquinol) to ensure eradication of infection (**Table 3**). Paromomycin is the preferred agent.

- Asymptomatic individuals with documented *E. histolytica* infection should also be treated because of the risks of

Table 3: Recommended dosages of antiamebic drugs

Drug	Dosage	Duration (in days)
<i>Amebic colitis or amebic liver abscess</i>		
Tinidazole	2 g/day orally	3
Metronidazole	750 mg three times a day, orally or intravenous (IV)	5–10
<i>Intestinal amebiasis</i>		
Paromomycin	30 mg/kg four times a day, orally in three divided doses	5–10
Iodoquinol	650 mg orally, three times a day	20

developing amebic colitis or amebic liver abscess in the future and risk of transmitting the infection to others. Paromomycin or iodoquinol in the doses listed in the **Table 3** should be used in these cases.

- Oral rehydration and electrolyte replacement should be done wherever necessary.
- Aspiration of liver abscess can be done as an adjunct to medical treatment in case of imminent rupture.

Prophylaxis

General prophylaxis is as for all fecal-oral infections. Food and water have to be protected from contamination with human excreta.

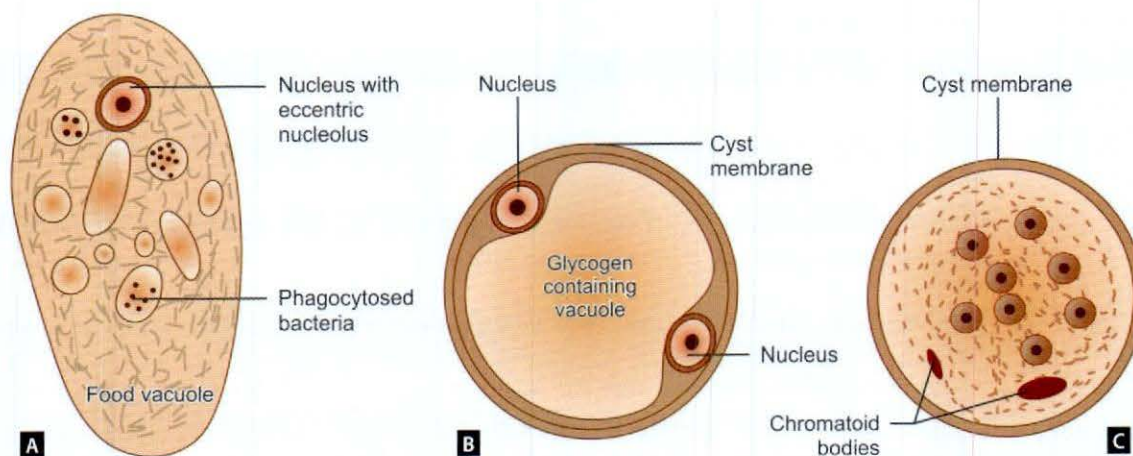
- Detection and treatment of carriers and their exclusion from food handling occupations will help in limiting the spread of infection.
- Health education and inclusion of healthy personal habits helps in control.

■ NONPATHOGENIC INTESTINAL AMEBA

Entamoeba Coli

E. coli was first described by Lewis (1870) and Cunningham (1871) in Kolkata and its presence in healthy persons was reported by Grassi (1878).

- It is worldwide in distribution and a nonpathogenic commensal intestinal ameba.
- It is larger than *E. histolytica* about 20–50 µm with sluggish motility and contains ingested bacteria but no red cells.
- The nucleus is clearly visible in unstained films and has a large eccentric karyosome and thick nuclear membrane lined with coarse granules of chromatin (**Figs 8A and B**).
- Cysts are large, 10–30 µm in size, with a prominent glycogen mass in the early stage. The chromatoid bodies are *splinter-like and irregular*. The mature cyst has *eight nuclei* (**Fig. 8C**).
- The life cycle is the same as in *E. histolytica* except that it remains a luminal commensal without tissue invasion and is nonpathogenic.



Figs 8A to C: Schematic diagram of the morphological forms of *Entamoeba coli* (Heidenhain's hematoxylin magnification 2000X). (A) Vegetative form; (B) Binucleate cyst; and (C) Eight-nucleate cyst

Entamoeba Hartmanni

E. hartmanni occurs wherever *E. histolytica* is found. It is now considered to be a separate species of nonpathogenic commensal intestinal amoeba.

- It is much smaller than *E. histolytica*, the trophozoite measuring 4–12 μm and cyst 5–10 μm in size (**Fig. 9**).
- Trophozoites do not ingest red cells and their motility is less vigorous.
- The cyst resembles that of *Endolimax nana*.

Differential features of cyst and trophozoites of *E. coli*, *E. hartmanni* and *E. histolytica* are shown in **Table 4**.

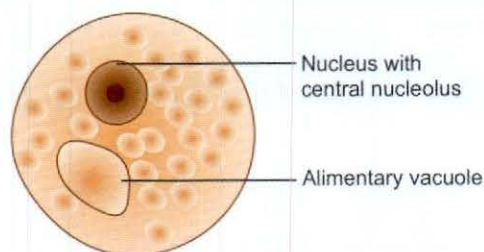


Fig. 9: Trophozoite of *Entamoeba hartmanni*

Entamoeba Gingivalis

E. gingivalis was the first amoeba of humans, discovered by Gros in 1849.

- It is global in distribution.
- Only the trophozoite is found; the cystic stage being apparently absent.
- The trophozoite is about 10–20 μm , actively motile with multiple pseudopodia.
- The cytoplasm contains food vacuoles with ingested bacteria, leukocytes and epithelial cells.
- Nucleus is round with central karyosome lined by coarse chromatin granules.
- The amoeba lives in gingival tissues and is abundant in unhygienic mouths. It is a commensal and is not considered to cause any disease.
- It is transmitted by direct oral contact.
- *E. gingivalis* have been found in bronchial washings and vaginal and cervical smears, where it can be mistaken for *E. histolytica*.

Endolimax Nana

This common commensal amoeba is widely distributed.

- It lives in the human intestine.
- The trophozoite is small (*nana*: small), less than 10 μm in size with a sluggish motility (**Fig. 10A**).
- The nucleus has conspicuous karyosome connected to nuclear membrane by one or more coarse strands.
- The cyst is small, oval and quadrinucleate with glycogen mass and chromidial bars, which are inconspicuous or absent (**Fig. 10B**).
- It is nonpathogenic.

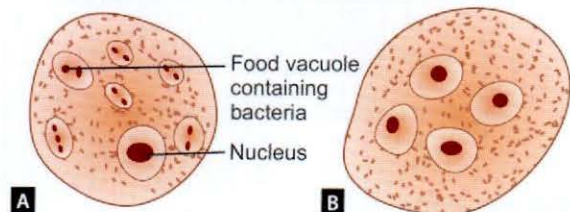
Iodamoeba Butschlii

This is widely distributed, though less common than *E. coli* and *E. nana*.

- The trophozoite is small, 6–12 μm , with conspicuous nucleus (**Fig. 11A**).
- The prominent karyosome is half the size of the nucleus, having bull's eye appearance.

Table 4: Differential features of intestinal *Entamoeba*

	<i>E. histolytica</i>	<i>E. coli</i>	<i>E. hartmanni</i>
<i>Trophozoite</i>			
Size (µm)	12–60	20–50	4–12
Motility	Active	Sluggish	Active
Pseudopodia	Finger-shaped, rapidly extruded	Short, blunt, slowly extruded	Finger-shaped, rapidly extruded
Cytoplasm	Clearly defined into ectoplasm and endoplasm	Differentiation, not distinct	Clearly defined into ectoplasm and endoplasm
Inclusions	Red blood cells (RBCs) present, no bacteria	Bacteria and other particles, no RBCs	Bacteria and other particles, no RBCs
Nucleus	Not clearly visible in unstained films	Visible in unstained films	Not visible in unstained films
Karyosome	Small, central	Large, eccentric	Small, eccentric
Nuclear membrane	Delicate, with fine chromatin dots	Thick, with coarse chromatin granules	Coarse chromatin granules
<i>Cyst</i>			
Size (µm)	10–15	10–30	5–10
Nuclei in mature cyst	4	8	4
Glycogen mass	Seen in uninucleate, but not in quadrinucleate stage	Seen up to quadrinucleate stage	Seen in uninucleate, but not in quadrinucleate stage
Chromidial	1–4 with rounded ends	Splinter-like with angular ends	Many with irregular shape

**Figs 10A and B:** *Endolimax nana*. (A) Vegetative form; and (B) Quadrinucleate cyst

- The cyst is oval, uninucleate and has a prominent iodine staining glycogen mass (*iodophilic body*). Hence, the name *Iodamoeba*. It is nonpathogenic (**Fig. 11B**).

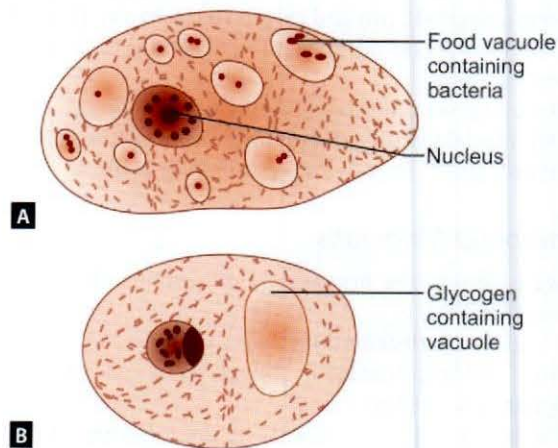
The comparative morphology of amebae infecting humans is illustrated in **Figure 12**.

■ PATHOGENIC FREE-LIVING AMEBAE

Among the numerous types of free-living amebae found in water and soil, a few are potentially pathogenic and can cause human infections.

- Primary amebic meningoencephalitis:** It is caused by ameboflagellate *Naegleria* (*the brain-eating Amoeba*).
- Granulomatous amebic encephalitis and chronic amebic keratitis:** It is caused by *Acanthamoeba*.

A few instances of granulomatous amebic encephalitis (GAE) caused by lyptomyxid ameba like *Balamuthia* have also been reported. While primary amebic meningoencephalitis

**Figs 11A and B:** *Iodamoeba butschlii*. (A) Vegetative form; and (B) Cyst

(PAM) and chronic amebic keratitis (CAK) occur in previously healthy individual, GAE has been associated with immunodeficient patients.

The term *amphizoic* has been used for organisms, which can multiply both in the body of a host (*endozoic*) and in free-living (*exozoic*) conditions.

Naegleria Fowleri

It is the only species of genus *Naegleria*, which infects man.

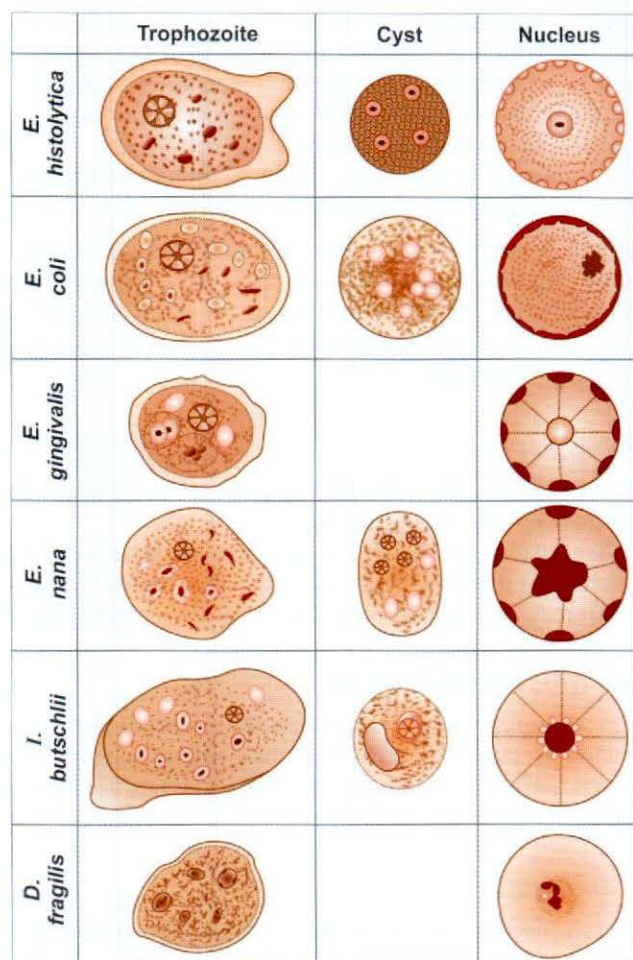


Fig. 12: Comparative morphology of amebae infecting humans, showing trophozoite and cyst stages, as well as enlarged representation of their nuclear structure

N. fowleri causes the disease *primary amebic meningoencephalitis (PAM)*, a brain infection that leads to destruction of brain tissue.

History and Distribution

N. fowleri is named after Malcolm Fowler, who along with Carter described it first from Australia in 1965.

- *N. fowleri* is a heat-loving (**thermophilic**) ameba that thrives in warm water at low oxygen tension and is commonly found in warm freshwater (e.g. lakes, rivers, and springs) and soil.
- It is worldwide in distribution.
- In the last 10 years from 2002 to 2011, 32 infections were reported in the United States (US), and in India, a total of 17 cases have been reported so far.

Morphology

N. fowleri occurs in three forms:

1. Cyst
2. Ameboid trophozoite form
3. Flagellate trophozoite form.

Trophozoite stage: The trophozoites occur in two forms, (1) *ameboid* and (2) *flagellate*.

Ameboid form: The ameboid form is about 10–20 μm , showing rounded pseudopodia (**lobopodia**), a spherical nucleus with big endosome and pulsating vacuoles.

- With electron microscopy, vacuoles appear to be densely granular in contrast to highly vacuolated body of ameba and are called as **amebostomes**. They are used for engulfing RBCs and white blood cells (WBCs) and vary in number, depending on the species.
- Ameboid form is the feeding, growing, and replicating form of the parasite, seen on the surface of vegetation, mud and water.
- It is the invasive stage of the parasite and the infective form of the parasite.

Flagellate form: The biflagellate form occurs when trophozoites are transferred to distilled water.

- This transformation of trophozoites to **biflagellate pear-shaped** form occurs within a minute.
- The flagellate can revert to the ameboid form, hence *N. fowleri* is classified as *ameboflagellate*.

Cyst stage: Trophozoites encyst due to unfavorable conditions like food deprivation, desiccation, cold temperature, etc.

- The cyst is spherical 7–10 μm in diameter and has a smooth double wall.
- They are the resting or the dormant form and can resist unfavorable conditions, such as drying and chlorine up to 50 ppm.
- The cyst can withstand moderate heat (45°C), but die at chlorine levels of 2 ppm and salinity of 0.7%.
- Cysts and flagellate forms of *N. fowleri* have never been found in tissues of cerebrospinal fluid (CSF).

Life Cycle

Typically, infection occurs when people go swimming or diving in warm freshwater river or ponds and poorly maintained swimming pools or nasal irrigation using contaminated tap water (**Fig. 13**).

- The life cycle of *N. fowleri* is completed in the external environment.
- The ameboid form of trophozoite multiplies by binary fission.
- Under unfavorable conditions, it forms a cyst and which undergoes excystation in favorable conditions.

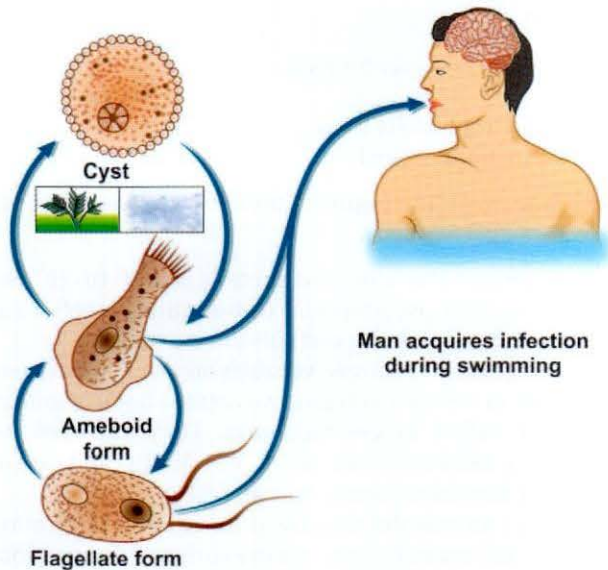


Fig. 13: Life cycle of *Naegleria fowleri*

- Flagellate form of trophozoite helps in the spread of *N. fowleri* to new water bodies. Since the ameboid form is the invasive stage, hence, the flagellate forms revert to ameboid forms to become infective to man.

Pathogenicity and Clinical Features

Patients are mostly previously healthy young adults or children.

- Human infection comes from water containing the amebae and usually follows swimming or diving in ponds.
- The amebae invade the nasal mucosa and pass through the olfactory nerve branches into the cribriform plate into the meninges, and brain to initiate an acute purulent meningitis and encephalitis, called as **primary amebic meningoencephalitis (PAM)**.
- The incubation period varies from 2 days to 2 weeks.
- In the incubation period, the patient experiences anosmia.
- The disease advances rapidly, causing fever, headache, vomiting, stiff neck, ataxia, seizure and coma.
- Cranial nerve palsies, especially of the third, fourth and sixth nerves have also been documented.
- The disease almost always ends fatally within a week (average 5 days).

Laboratory Diagnosis

The diagnosis of PAM is based on the finding of motile *Naegleria* trophozoites in wet mounts of freshly obtained CSF.

Cerebrospinal fluid examination: The CSF is cloudy to purulent, with prominent neutrophilic leukocytosis, elevated protein and low glucose, resembling pyogenic meningitis.

- Wet film examination of CSF may show trophozoites.
- Cysts are not found in CSF or brain.
- At autopsy, trophozoites can be demonstrated in brain histologically by immunofluorescent staining.

Culture: *N. fowleri* can be grown in several kinds of liquid axenic media or nonnutrient agar plates coated with *Escherichia coli*. Both trophozoites and cysts occur in culture.

Molecular diagnosis: Newer tests based on PCR technology are being developed.

Treatment

The drug of choice is **amphotericin B** intravenously. It can also be instilled directly into the brain.

- Treatment combining miconazole and sulfadiazine has shown limited success, only when administered early.
- More than 95% cases of PAM are fatal despite of treatment.

Acanthamoeba Species

A. culbertsoni (formerly, *Hartmannella culbertsoni*) is the species most often responsible for human infection but other species like *A. polyphagia*, *A. castellanii* and *A. astromyx* have also been reported.

Distribution

This is an opportunistic protozoan pathogen found worldwide in the environment in water and soil.

- Approximately, 400 cases have been reported worldwide.

Morphology

Acanthamoeba exists as active trophozoite form and a resistant cystic form.

- The trophozoite is large, 20–50 μm in size and characterized by spine-like pseudopodia (**acanthopodia**).
- It differs from *Naegleria* in not having a flagellate stage and in forming cysts in tissues (**Table 5**).
- The polygonal double-walled cysts are highly resistant.
- The cysts are present in all types of environment, all over the world.

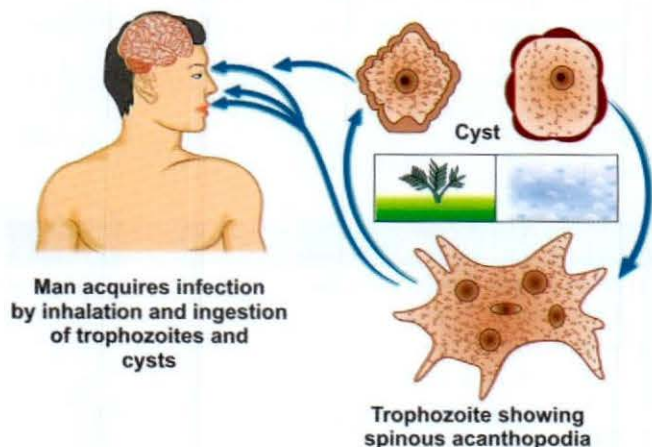
Life Cycle

- Both trophozoites and cysts are infective.
- Human beings acquire by inhalation of cyst or trophozoite, ingestion of cysts, or through traumatized skin or eyes (**Fig. 14**).

Table 5: Differential features of *Naegleria* and *Acanthamoeba*

	<i>Naegleria</i>	<i>Acanthamoeba</i>
Disease	Primary amebic meningoencephalitis (PAM)	Granulomatous amebic encephalitis (GAE) and keratitis
Portal of entry	Nose	Upper respiratory tract, cornea
Clinical course	Acute	Subacute or chronic
Pathogenicity	Acute suppurative inflammation	Granulomatous inflammation
Morphological forms	Three stages: (1) trophozoite, (2) cyst and (3) flagellate form	Two stages: (1) trophozoite and (2) cyst flagellate form absent
Trophozoite	10–20 μm , with a single pseudopodia	20–50 μm , with spine-like pseudopodia
Cyst	7–10 μm , round with smooth wall	15–25 μm , polygonal double-walled with wrinkled surface
Nuclear division	By promitosis, nucleolus divides, nuclear membrane persists	Nuclear membrane dissolves
WBC in CSF	Predominantly neutrophils	Predominantly lymphocytes

Abbreviations: CSF, cerebrospinal fluid; WBC, white blood cell

**Fig. 14:** Life cycle of *Acanthamoeba culbertsoni*

- After inhalation of aerosol or dust containing trophozoites and cysts, the trophozoites reach the lungs and from there, they invade the central nervous system through the bloodstream, producing **granulomatous encephalitis (GAE)**.

Pathogenesis and Clinical Features

- Infection usually occurs in patients with immunodeficiency, diabetes, malignancies, malnutrition, systemic lupus erythematosus (SLE), or alcoholism.

- The parasite spreads hematogenously into central nervous system. Subsequent invasion of the connective tissue and induction of proinflammatory responses lead to neuronal damage that can be fatal within days.
- A postmortem biopsy reveals severe edema and hemorrhagic necrosis.

Clinical Disease

It presents chiefly as two chronic conditions: (1) keratitis and (2) encephalitis.

- Acanthamoeba keratitis*:** An infection of the eye that typically occurs in healthy persons and develops from the entry of the amebic cyst through abrasions on the cornea.
 - Majority of such cases have been associated with the use of contact lenses.
 - The picture resembles that of severe herpetic keratitis with a slow relapsing course, but the eye is severely painful in the amebic infection.
 - Unilateral photophobia, excessive tearing, redness and foreign body sensation are the earliest signs and symptoms; disease is bilateral in some contact lens users.
 - Keratitis and uveitis can result in permanent visual impairment or blindness.
- Granulomatous amebic encephalitis*:** It is a serious infection of the brain and spinal cord that typically occurs in persons with a compromised immune system.
 - Granulomatous amebic encephalitis is believed to follow inhalation of the dried cysts.
 - The incubation period is long and the evolution of the illness is slow.
 - Clinical picture is that of intracranial space-occupying lesions with seizures, pareses and mental deterioration.
- Disseminated infection*:** In immunocompromised states like acquired immunodeficiency syndrome (AIDS), a widespread infection can affect skin, lungs, sinuses, and other organs independently or in combination.

Laboratory Diagnosis

- Diagnosis of amebic keratitis** is made by demonstration of the cyst in corneal scrapings by wet mount, histology and culture. Growth can be obtained from corneal scrapings inoculated on nutrient agar, overlaid with live or dead *Escherichia coli* and incubated at 30°C.
- Rapid diagnosis can be made by identification of ameba or cyst in corneal scraping by fluorescent microscopy using *calcofluor white staining* and *IFA test (IFAT)* procedure.
- Diagnosis of GAE** is made by demonstration of trophozoites and cysts in brain biopsy, culture and immunofluorescence microscopy using monoclonal antibodies.

- Cerebrospinal fluid shows lymphocytic pleocytosis, slightly elevated protein levels, and normal or slightly decreased glucose levels.
- Computed tomography scan of brain provides inconclusive findings.

Treatment

In *Acanthamoeba keratitis*, current therapy involves topical administration of biguanide or chlorhexidine with or without diamidine agent. In severe cases, where vision is threatened, penetrating keratoplasty can be done.

No effective treatment is available for "GAE". Multidrug combinations including pentamidine, sulfadiazine, rifampicin and fluconazole are being used with limited success.

Balamuthia Mandrillaris

B. mandrillaris, a leptomixid free-living amoeba, is a newly identified species reported to cause GAE.

Morphology

It exists in amoeboid trophozoite stage. The flagellate stage is absent.

- It is relatively large (12–60 μm), irregular in shape and actively motile by broad pseudopodia.
- Cyst of *B. mandrillaris* are usually spherical (6–20 μm), surrounded by a three-layered cyst wall: (1) outer irregular ectocyst, (2) a middle mesocyst and (3) an inner endocyst round wall. Under light microscopy, it appears to have two walls: (1) an outer irregular wall and (2) an inner smooth wall.
- Infection is transmitted through respiratory tract, skin lesions, or eyes.
- Life cycle is similar to that of *Acanthamoeba* spp.

Clinical Disease

It causes granulomatous amoebic encephalitis in both healthy and immunocompromised hosts particularly in children and elderly.

Laboratory Diagnosis

Laboratory diagnosis is done by identifying trophozoites of *B. mandrillaris* in the CSF and trophozoites and cysts in brain tissue.

Polymerase chain reaction also gives reliable diagnosis.

KEY POINTS OF AMEBAE

- *E. histolytica* is found in human colon and is mainly asymptomatic.
- Cyst contains glycogen mass and 1–4 chromatid bars.
- Pathogenic strains are identified by genetic markers and zymodeme analysis.
- **Stools:** In amoebic dysentery, stool is copious, foul-smelling, brownish black often with blood-streaked mucus.
- **Amoebic ulcers:** Typical ulcers are discrete, flask-shaped, with ragged undermined margin, found in cecum and sigmoidorectal region.
- Amoebic granuloma or amoeboma may develop from chronic ulcers.
- **Extraintestinal complications:** Amoebic hepatitis and liver abscess are the most common.
- Abscesses in other organs such as lung, brain, spleen and genitourinary tract may result from hematogenous spread or by direct spread from hepatic lesion.
- **Diagnosis:** By demonstration of trophozoites and cyst in stool and also by serological tests and imaging techniques in hepatic amoebiasis.
- **Treatment:** By metronidazole or tinidazole along with paromomycin, diloxanide furoate, or chloroquine.
- *E. hartmanni*, *E. coli*, *E. gingivalis*, *E. nana*, and *Iodamoeba* are commensals and nonpathogenic amoebae.
- *Naegleria* and *Acanthamoeba* are pathogenic free-living amoeba.
- *N. fowleri* occurs in three forms: (1) cyst, (2) trophozoite and (3) flagellate. It causes PAM.
- *Acanthamoeba* species cause amoebic keratitis and also GAE in immunocompromised subjects.

REVIEW QUESTIONS

1. Describe briefly the life cycle and laboratory diagnosis of *Entamoeba histolytica*.
2. Write short notes on:
 - a. Extraintestinal amoebiasis
 - b. Free-living amoebae
3. Differentiate between:
 - a. Amoebic dysentery and bacillary dysentery
 - b. *Entamoeba histolytica* and *Entamoeba coli*
 - c. *Naegleria* and *Acanthamoeba*

MULTIPLE CHOICE QUESTIONS

1. The main reservoir of *Entamoeba histolytica* is
 - a. Man
 - b. Dirty water
 - c. Dog
 - d. Monkey

2. The infective form of *Entamoeba histolytica* is
- Trophozoite
 - Binucleate cyst
 - Quadrinucleate
 - None of the above
3. The pathogenicity of *Entamoeba histolytica* is indicated by
- Zymodeme pattern
 - Size
 - Nuclear pattern
 - ELISA test
4. M/C site for extra intestinal amebiasis is
- Liver
 - Lung
 - Brain
 - Spleen
5. Amoebic liver abscess can be diagnosed by demonstrating
- Cyst in the sterile pus
 - Trophozoites in the pus
 - Cyst in the intestine
 - Trophozoites in the feces
6. Stool of amoebic dysentery has all of the following characteristics except
- Charcot-Leyden crystals
 - Pyknotic bodies
 - RBCs
 - Ghost cell
7. The term ameboma is used to describe
- Amebic liver abscess
 - Skin lesion due to draining amebic abscess
 - Granuloma at ileocecal junction
 - None of the above
8. True statement regarding *Entamoeba histolytica* is
- The trophozoites are infective to man
 - Mature cyst has eccentric nucleolus
 - It can cause primary amebic encephalitis
 - Cyst are resistant to chlorine concentration used in drinking water
9. All are nonpathogenic ameba living in the lumen of large intestine except
- Entamoeba coli*
 - Entamoeba hartmanni*
 - Endolimax nana*
 - Entamoeba gingivalis*
10. Chronic amebic keratitis is seen in
- Entamoeba histolytica*
 - Acanthamoeba*
 - Naegleria fowleri*
 - Hemoflagellates
11. Etiologic agent of granulomatous amebic encephalitis is
- Entamoeba histolytica*
 - Acanthamoeba*
 - Naegleria*
 - Dientamoeba fragilllis*

Answer

- | | | | | | | |
|------|------|-------|-------|------|------|------|
| 1. a | 2. c | 3. a | 4. a | 5. b | 6. d | 7. c |
| 8. d | 9. d | 10. b | 11. b | | | |

Intestinal, Oral and Genital Flagellates

■ INTRODUCTION

Parasitic protozoa, which possess *whip-like flagella* as their organs of locomotion are called as *flagellates* and classified as:

- *Phylum*: Sarcomastigophora
- *Subphylum*: Mastigophora
- *Class*: Zoomastigophora (*mastix: whip*)
- Depending on their habitat, they can be considered under:
 - **Lumen-dwelling flagellates**: Flagellates found in the alimentary tract and urogenital tract (**Table 1**).
 - **Hemoflagellates**: Flagellates found in blood and tissues (**Table 1**).
- Most luminal flagellates are nonpathogenic commensals. Two of them cause clinical diseases: (1) *Giardia lamblia*, which can cause diarrhea, and (2) *Trichomonas vaginalis*, which can produce vaginitis and urethritis.

Table 1: Flagellates

Group	Parasites	Habitat
Lumen-dwelling flagellates	<ul style="list-style-type: none"> • <i>Giardia lamblia</i> • <i>Trichomonas vaginalis</i> • <i>Trichomonas tenax</i> • <i>Trichomonas hominis</i> • <i>Chilomastix mesnili</i> • <i>Enteromonas hominis</i> • <i>Retortamonas intestinalis</i> • <i>Dientamoeba fragilis</i> 	<ul style="list-style-type: none"> • Duodenum and jejunum • Vagina and urethra • Mouth • Large intestine (cecum) • Large intestine (cecum) • Large intestine (colon) • Large intestine (colon) • Large intestine (cecum and colon)
Hemoflagellates	<ul style="list-style-type: none"> • <i>Leishmania</i> spp. • <i>Trypanosoma brucei</i> • <i>Trypanosoma cruzi</i> 	<ul style="list-style-type: none"> • Reticuloendothelial cells • Connective tissue and blood • Reticuloendothelial cells and blood

■ GIARDIA LAMBLIA

History and Distribution

It is one of the earliest protozoan parasites to have been recorded.

- The flagellate was first observed by Dutch scientist Antonie van Leeuwenhoek (1681) in his own stools.
- It is named *Giardia* after Professor Giard of Paris and *lamblia* after Professor Lamble of Prague, who gave a detailed description of the parasite.
- It is the most common protozoan pathogen and is worldwide in distribution.
- Endemicity is very high in areas with low sanitation, especially tropics and subtropics. Visitors to such places frequently develop traveler's diarrhea caused by giardiasis through contaminated water.

Habitat

G. lamblia lives in the *duodenum* and *upper jejunum* and is the only protozoan parasite found in the lumen of the human small intestine (**Box 1**).

Morphology

It exists in two forms:

1. Trophozoite (or vegetative form)
2. Cyst (or cystic form).

Box 1: Protozoa found in small intestine

- *Giardia lamblia*
- *Isospora belli*
- *Cyclospora cayatanensis*
- *Cryptosporidium parvum*
- *Sarcocystis hominis* and *suihominis*

Trophozoite

The trophozoite is in the shape of a tennis racket (**heart-shaped or pyriform-shaped**) and is rounded anteriorly and pointed posteriorly (**Figs 1 and 2A and B**).

- It measures $15\ \mu\text{m} \times 9\ \mu\text{m}$ wide and $4\ \mu\text{m}$ thick.
- Dorsally, it is convex; and ventrally, it has a concave sucking disk, which helps in its attachment to the intestinal mucosa.
- It is bilaterally symmetrical and possesses:
 - One pair of nuclei
 - **Four pairs** of flagella
 - Blepharoplast, from which the flagella arise (four pairs)
 - One pair of axostyles, running along the midline
 - Two sausage-shaped parabasal or median bodies, lying transversely posterior to the sucking disk.
- The trophozoite is motile, with a slow oscillation about its long axis, often resembling **falling leaf**.

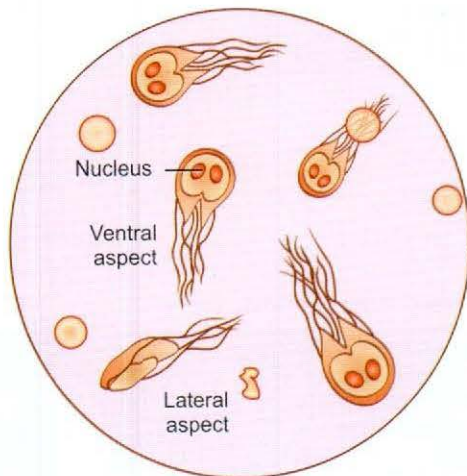
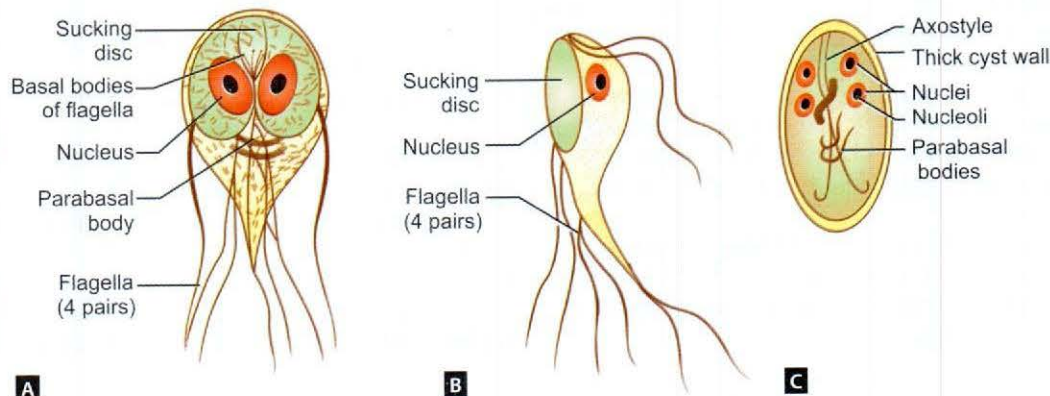


Fig. 1: *Giardia lamblia* in duodenal fluid wet preparation. Magnification 1500X



Figs 2A to C: Trophozoite. (A) Ventral view; (B) Lateral view; and (C) Quadrinucleate cyst

Cyst

It is the infective form of the parasite (**Fig. 2C**).

- The cyst is small and oval, measuring $12\ \mu\text{m} \times 8\ \mu\text{m}$ and is surrounded by a hyaline cyst wall.
- Its internal structure includes two pairs of nuclei grouped at one end. A young cyst contains one pair of nuclei.
- The axostyle lies diagonally, forming a dividing line within cyst wall.
- Remnants of the flagella and the sucking disc may be seen in the young cyst.

Life Cycle

Giardia passes its life cycle in **one host**.

Infective Form

Mature cyst.

Mode of Transmission

- Man acquires infection by ingestion of cysts in contaminated water and food.
- Ingestion of as far as 10 cysts is sufficient to cause infection in a man.
- Children are commonly affected.
- Direct person-to-person transmission may also occur in children, male homosexuals and mentally ill persons.
- Enhanced susceptibility to giardiasis is associated with blood group A, achlorhydria, use of *Cannabis*, chronic pancreatitis, malnutrition, and immune defects such as 19A deficiency and hypogammaglobulinemia.
- Within half an hour of ingestion, the cyst hatches out into two trophozoites, which multiply successively by binary fission and colonize in the duodenum (**Fig. 3**).
- The trophozoites live in the duodenum and upper part of jejunum, feeding by pinocytosis.

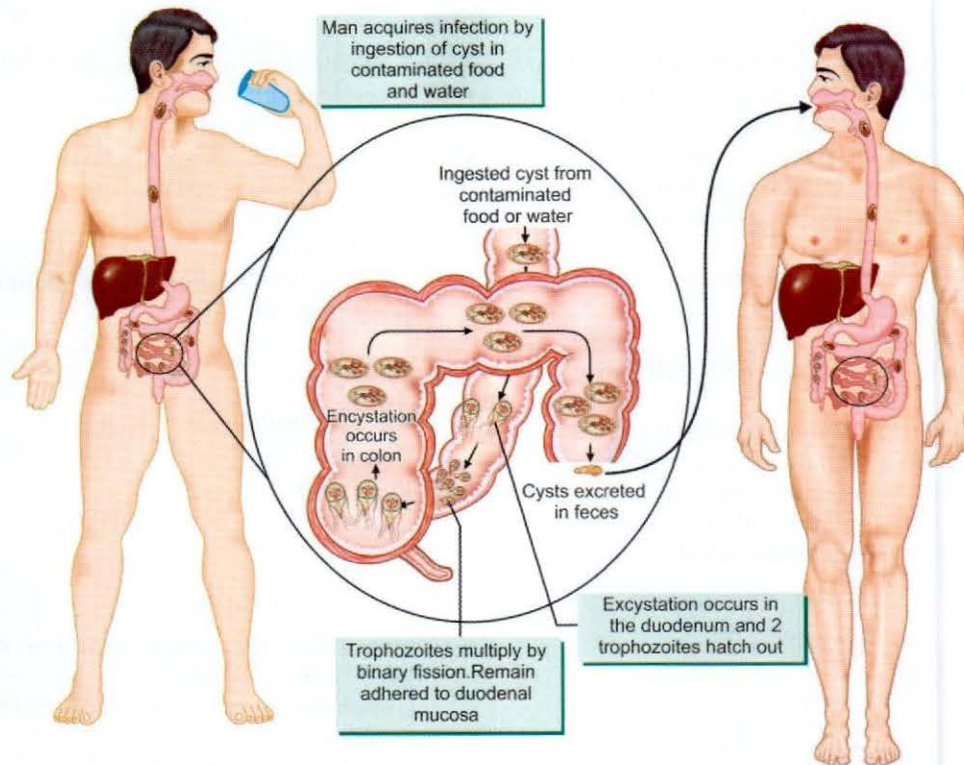


Fig. 3: Life cycle of *Giardia lamblia*

- During unfavorable conditions, encystment occurs usually in colon (**Fig. 3**).
- Cysts are passed in stool and remain viable in soil and water for several weeks.
- There may be 200,000 cysts passed per gram of feces.
- *Infective dose* is 10–100 cysts.

Box 2: Protozoan parasites causing diarrhea

- *Giardia lamblia*
- *Entamoeba histolytica*
- *Cyclospora cayatanensis*
- *Cryptosporidium parvum*
- *Isospora belli*

Pathogenicity and Clinical Features

G. lamblia is typically seen within the crypts of duodenal and jejunal mucosa. It *does not invade the tissue*, but remains tightly adhered to intestinal epithelium by means of the sucking disk.

- They may cause abnormalities of villous architecture by cell apoptosis and increased lymphatic infiltration of lamina propria. Loss of brush border epithelium of intestine leads to deficiency of enzymes including disaccharidases.
- Variant-specific surface proteins (**VSSPs**) of *Giardia* play an important role in virulence and infectivity of the parasite. Antigenic variation helps the parasite in evasion of host immune system.

- Often they are **asymptomatic**, but in some cases, *Giardia* may lead to mucus diarrhea, **fat malabsorption** (steatorrhea), dull epigastric pain, belching and flatulence. The stool contains excess mucus and fat but no blood (**Box 2**).
- Children may develop chronic diarrhea, malabsorption of fat, vitamin A, vitamin B₁₂, folic acid, protein, sugars like xylose disaccharides, weight loss and sprue-like syndrome. Chronic giardiasis may be due to failure to develop immunoglobulin A (IgA) against specific *Giardia* antigen.
- Occasionally, *Giardia* may colonize the gallbladder, causing biliary colic and jaundice.
- **Incubation period** is variable, but is usually about 2 weeks.

Laboratory Diagnosis

Stool Examination

Giardiasis can be diagnosed by identification of cysts of *Giardia lamblia* in the formed stools and the trophozoites and cysts of the parasite in diarrheal stools (**Flow chart 1**).

- On macroscopic examination, fecal specimens containing *G. lamblia* may have an offensive odor, are pale colored and fatty, and float in water.
- On microscopic examination, cysts and trophozoites can be found in diarrheal stools by saline and iodine wet preparations.
- Often multiple specimens need to be examined and concentration techniques like formal ether or zinc acetate are used. In asymptomatic carriers, only the cysts are seen.

Enterotest (String Test)

A useful method for obtaining duodenal specimen is *enterotest*. A coiled thread inside a small weighted gelatin capsule is swallowed by the patient, after attaching the free end of the thread in the cheek. The capsule passes through the stomach to the duodenum. After 2 hours, the thread is withdrawn, placed in saline, and is mechanically shaken. The centrifuged deposit of the saline is examined for *Giardia*. The use of enterotest is not recommended because of the very high cost of the test.

Serodiagnosis

Antigen detection: Enzyme-linked immunosorbent assay (ELISA), immunochromatographic strip tests and indirect immunofluorescence (IIF) tests using monoclonal antibodies have been developed for detection of *Giardia* antigens in feces (**Flow chart 1**).

- The presence of antigen indicates active infection.
- Commercially available ELISA kits (**ProSpect**/*Giardia* kit) detects *Giardia-specific antigen 65* (GSA 65).
- The sensitivity of the test is 95% and specificity is 100%, when compared to conventional microscopy.

- The test may be used for quantification of cysts and in epidemiological and control studies, but not for routine use.

Antibody detection: Indirect immunofluorescence test and ELISA are used to detect antibodies against *Giardia*.

- Demonstration of antibodies is useful in the epidemiological and pathophysiological studies.
- These tests cannot differentiate between recent and past infection and lack sensitivity and specificity.

Molecular Method

Deoxyribonucleic acid (DNA) probes and polymerase chain reaction (PCR) have been used to demonstrate parasitic genome in the stool specimen (**Flow chart 1**).

Treatment

Metronidazole (250 mg, thrice daily for 5–7 days) and tinidazole (2 g single dose) are the drugs of choice.

- Cure rates with metronidazole are more than 90%.
- Tinidazole is more effective than metronidazole.
- Furazolidone (100 mg QID × 7 days) and nitazoxanide (500 mg BD × 3 days) are preferred in children, as they have fewer adverse effects.
- Paromomycin, an oral aminoglycoside, can be given to symptomatic pregnant females (500 mg TDS × 5 days).

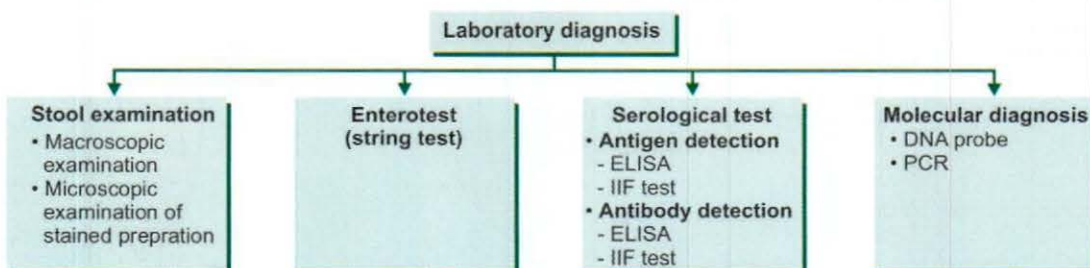
Note: Only symptomatic cases need treatment.

Prophylaxis

Giardiasis can be prevented by following measures:

- Proper disposal of waste water and feces.
- Practice of personal hygiene like handwashing before eating and proper disposal of diapers.
- Prevention of food and water contamination. Community chlorination of water is ineffective for inactivating cysts. Boiling of water and filtration by membrane filters are required.

Flow chart 1: Laboratory diagnosis of *Giardia lamblia*



Abbreviations: DNA, deoxyribonucleic acid; ELISA, enzyme-linked immunosorbent assay; IIF, indirect immunofluorescence; PCR, polymerase chain reaction

KEY POINTS OF *GIARDIA LAMBLIA*

- *Giardia* is the only protozoan parasite found in the lumen of the human small intestine (duodenum and jejunum).
- Trophozoites are pear-shaped, bilaterally symmetrical with two nuclei, four pairs of flagella and a ventral concave sucking disk. They exhibit motility resembling a "falling leaf".
- Ellipsoid cysts contain four nuclei with remnants of flagella.
- **Infective form:** Ellipsoid cysts.
- **Clinical features:** Mostly asymptomatic but in some cases may cause diarrhea, dull epigastric pain and malabsorption. Stool contains excess mucus but no blood.
- **Diagnosis:** By microscopic demonstration of trophozoites or cysts in stool, enterotest and serodiagnosis by ELISA (ProSpecT/*Giardia* antigen assay).
- **Treatment:** Metronidazole and tinidazole are the drugs of choice.

■ TRICHOMONAS

Trichomonas differs from other flagellates, as they exist only in trophozoite stage. Cystic stage is not seen.

- Genus *Trichomonas* has three species, which occur in humans (Figs 4A to C):
 1. *T. vaginalis* (Fig. 4A)
 2. *T. hominis* (Fig. 4B)
 3. *T. tenax* (Fig. 4C)

Trichomonas Vaginalis

History and Distribution

T. vaginalis was first observed by Donne (1836) in vaginal secretion.

- Prevalence of trichomoniasis varies from 5% patients at hospitals to 75% in sexual workers.

Morphology

It is **pear-shaped** or ovoid and measures 10–30 μm in length and 5–10 μm in breadth with a short undulating membrane reaching up to the middle of the body (Fig. 4A).

- It has four anterior flagella and fifth running along the outer margin of the undulating membrane, which is supported at its base by a flexible rod, **costa**.
- A prominent **axostyle** runs throughout the length of the body and projects posteriorly like a tail.
- The cytoplasm shows prominent siderophilic granules, which are most numerous alongside the axostyle and costa.
- It is motile with a rapid **jerky or twitching** type movement.

Habitat

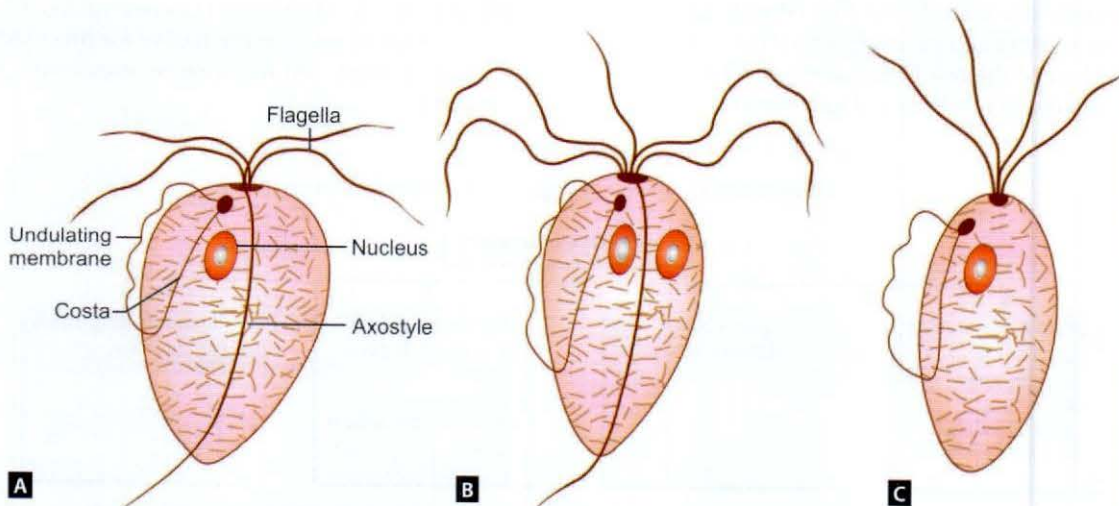
In females, it lives in vagina and cervix and may also be found in Bartholin's glands, urethra and urinary bladder. In males, it occurs mainly in the anterior urethra, but may also be found in the prostate and preputial sac.

Life Cycle

Life cycle of *T. vaginalis* is completed in a **single host** either male or female.

Mode of transmission:

- The trophozoite cannot survive outside and so infection has to be transmitted directly from person-to-person. **Sexual transmission** is the usual mode of infection (Box 3).
- Trichomoniasis often coexists with other sexually transmitted diseases like candidiasis, gonorrhoea, syphilis, or human immunodeficiency virus (HIV).
- Babies may get infected during birth.
- Vaginal pH of more than 4.5 facilitates infection.



Figs 4A to C: *Trichomonas* species. (A) *T. vaginalis*; (B) *T. hominis*; and (C) *T. tenax*

Box 3: Protozoa transmitted by sexual contact

- *Trichomonas vaginalis*
- *Giardia lamblia*
- *Entamoeba histolytica*

- Fomites such as towels have been implicated in transmission.
- Trophozoites divide by *binary fission*.
- As cysts are not formed, the *trophozoite* itself is the *infective form*.
- **Incubation** period is roughly 10 days.

Pathogenesis

T. vaginalis particularly infects squamous epithelium and not columnar epithelium. It secretes cysteine proteases, adhesins, lactic acid and acetic acid, which disrupt the *glycogen levels* and lower the *pH* of the vaginal fluid.

- It is an **obligate parasite** and cannot live without close association with the vaginal, urethral, or prostatic tissues.
- Parasite causes petechial hemorrhage and mucosal capillary dilation (**strawberry mucosa**), metaplastic changes and desquamation of the vaginal epithelium.
- Intracellular edema and so called *chicken-like epithelium*, is the characteristic feature of trichomoniasis.

Clinical Features

Infection is often asymptomatic, particularly in males, although some may develop urethritis, epididymitis and prostatitis.

- In females, it may produce severe pruritic vaginitis with an offensive, yellowish green, often frothy discharge, dysuria and dyspareunia. Cervical erosion is common. Endometritis and pyosalpingitis are infrequent complications.
- Rarely, neonatal pneumonia and conjunctivitis have been reported in infants born to infected mothers.
- The incubation period of trichomoniasis is 4 days to 4 weeks.

Laboratory Diagnosis**Microscopic examination**

Wet mount:

- Vaginal or urethral discharge is examined microscopically in saline wet mount preparation for characteristic jerky and twitching motility and shape. In males, trophozoites may be found in urine or prostatic secretions. An abundance of leukocytes is seen.

Permanent stain:

- Fixed smears may be stained with acridine orange, Papanicolaou and Giemsa stains.

Direct fluorescent antibody:

- Direct fluorescent antibody (DFA) is another method of detection of parasite and is more sensitive than the wet mount.

Culture: Culture is recommended when direct microscopy is negative and is considered as a "gold standard" as well as the most sensitive (95%) method for the diagnosis of *T. vaginalis* infection.

- It grows best at 35–37°C under anaerobic conditions. The optimal pH for growth is 5.5–6.0.
- It can be grown in a variety of solid or liquid media, tissue culture and eggs. Cysteine-peptone-liver-maltose (CPLM) medium and plastic envelope medium (PEM) are often used.

Serology: Enzyme-linked immunosorbent assay is used for demonstration of *T. vaginalis* antigen in vaginal smear using a monoclonal antibody for 65 kDA surface polypeptide of *T. vaginalis*.

Rapid immunochromatographic tests (ICTs) are now available for detection of *Antigen* like OSOM Trichomonas rapid test, Xenostrip-Tv.

Molecular method: Deoxyribonucleic acid hybridization and PCR are also highly sensitive (97%) and specific (98%) tests for the diagnosis of trichomoniasis.

Sensitive and specific commercially available Nucleic acid amplification test (NAAT) has been developed (Aptima *Trichomonas vaginalis* assay).

Treatment

Simultaneous treatment of both partners is recommended as it is an STD.

- Metronidazole 2 g orally as a single dose or 500 mg orally twice a day for 7 days is the drug of choice.
- In patients not responding to treatment with standard regime, the dose of metronidazole may be increased or it may be administered parenterally.
- In pregnancy, metronidazole is safe in 2nd and 3rd trimesters.

Prophylaxis

Prevention is same as for other sexually transmitted diseases.

- Avoidance of sexual contact with infected partners and use of barrier method during intercourse prevent the disease.
- Patient's sexual partner should be tested for *T. vaginalis* when necessary.

Trichomonas Tenax

T. tenax, also known as *T. buccalis*, is a harmless commensal which lives in mouth, in the periodontal pockets, carious tooth cavities and, less often, in tonsillar crypts.

- It is *smaller* (5–10 μm) than *T. vaginalis*.
- It is transmitted by kissing, through salivary droplets and fomites. There are sporadic reports of its involvement in respiratory infections and thoracic abscesses.
- Better oral hygiene rapidly eliminates the infection and no therapy is indicated.

Trichomonas Hominis

T. hominis measures 8–12 μm , **pyriform-shaped**, and carries **five anterior flagella** and an undulating membrane that extends the full length of the body.

- It is a **very harmless commensal** of the cecum.
- Microscopic examination of stool will reveal motile trophozoite of *T. hominis*.
- Transmission occurs in trophic form by fecal–oral route.

KEY POINTS OF TRICHOMONAS

- Trichomonas occurs only in trophozoite form, which is **pear-shaped**, with **five flagella** and an undulating membrane.
- The motility is rapid jerky or twitching type.
- **Habitat:** Vagina and cervix in female and urethra in males.
- **Clinical features:** Often asymptomatic in males. In females, it leads to pruritic vaginitis with greenish yellow discharge, strawberry mucosa and dysuria.
- **Diagnosis:** By wet mount microscopy of vaginal or urethral discharge, culture (gold standard), PCR and by demonstration of antigen in vaginal smear by ELISA.
- **Treatment:** Metronidazole is the drug of choice and simultaneous treatment of both partners is recommended.

CHILOMASTIX MESNILI

This occurs as trophozoites and cysts (Fig. 5).

- The trophozoite is **pear-shaped** measuring 5–20 μm in length and 5–10 μm in breadth.

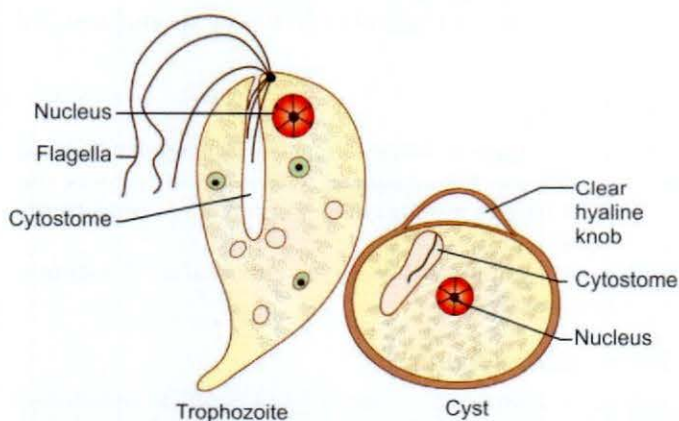


Fig. 5: Trophozoite and egg of *Chilomastix mesnili*

- At the anterior end, it has a **spherical nucleus**.
- A distinct spiral groove is seen on one side of the nucleus.
- The cysts are **lemon-shaped** having a spiral projection at the anterior end. It measures 5–10 μm in length and 4–6 μm in breadth and is surrounded by a thick cyst wall.
- Both trophozoites and cysts are demonstrated in the semi-formed stool.
- It is a **harmless commensal** of cecum where the organism feeds on bacteria and food debris. Since infection is acquired through ingestion of cysts, prevention depends on improved personal hygiene.

ENTEROMONAS HOMINIS

E. hominis is a **nonpathogenic commensal** that lives in the large intestine, mainly in the cecum.

- It exists in two forms: (1) **trophozoite**, and (2) **cyst** (Fig. 6).
- The trophozoite is **pear-shaped**, with three anterior and one posterior flagella.
 - It measures 5–10 μm in length and 3–6 μm in breadth.
 - The cytoplasm contains numerous bacteria and an anteriorly placed nucleus but no cytostoma.
 - It shows jerky forward movements.
- The **cyst** is oval in shape, measuring 5–8 μm in length and 4–6 μm in breadth.
 - It contains 2–4 nuclei.
 - The cyst of *E. hominis* may mimic a two-nucleated cyst of *E. nana*.
- Infection occurs through fecal–oral route by ingestion of cysts in contaminated food and water.
- Diagnosis is made by identification of trophozoites or cysts in the stool by iron hematoxylin stain.

RETORTAMONAS INTESTINALIS

Wenyon and O'Connor first observed the parasite in stool in Egypt.

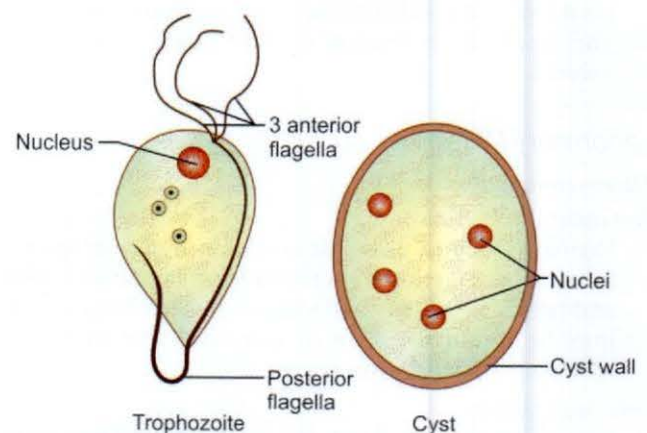


Fig. 6: Trophozoite and cyst of *Enteromonas hominis*

- *R. intestinalis* is a small nonpathogenic flagellate found in the large intestine.
- It also exists in two forms: (1) trophozoite, and (2) cyst.
- The trophozoite is elongated, pyriform in shape, measuring 5–10 μm in length and 3–4 μm in breadth.
 - The cytoplasm is granular and vacuolated.
 - It has a cleft-like cytosome, spherical nucleus and central karyosome.
 - Two minute blepharoplasts are present near nucleus, from which two flagella originate.
 - The trophozoite multiplies by binary fission.
- The cyst is ovoid or pyriform in shape, measuring 6 μm in length and 3 μm in breadth.
- Water and food contaminated by cysts are the main source of infection.
- Diagnosis is made by identifying the cysts and trophozoites in the direct wet mount and iron hematoxylin-stained specimen of stool.

■ DIENTAMOEBIA FRAGILIS

D. fragilis was previously considered as an amoeba but has now been reclassified as an *amoeboflagellate*, based on electron microscopic study and antigenic similarity to *Trichomonas*.

- It is unique as it has *only trophozoite stage* but *no cyst stage*.
- The name *Dientamoeba fragilis* is derived from the binucleate nature of trophozoite (*Dientamoeba*) and the fragmented appearance (*fragilis*) of its nuclear chromatin.
- It is seen worldwide and is reported to be the most common intestinal protozoan parasite in Canada.
- It lives in colonic mucosal crypts, feeding on bacteria. It does not invade tissues, but may rarely ingest red blood cells (RBCs).
- The trophozoite is 7–12 μm in diameter. It is motile with broad hyaline leaf-like pseudopodia. They have 1–4 nuclei; the binucleate form being the most common (Fig. 7). The nuclear chromatin is present as 3–5 granules in the center, with no peripheral chromatin on the nuclear membrane.
- In the absence of cyst stage, its mode of transmission is not clear. Possibly, it is transmitted from person-to-person by the fecal–oral route or by the eggs of *Enterobius vermicularis* and other nematodes, which may serve as a vector.
- Formerly believed to be nonpathogenic, it has now been associated with a variety of symptoms like intermittent diarrhea, abdominal pain, flatulence, anorexia, nausea, malaise and fatigue.
- High incidence is seen among children between 2 years and 10 years of age.

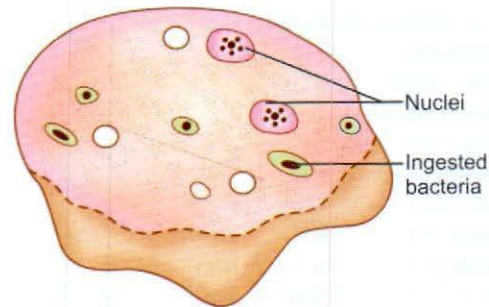


Fig. 7: Trophozoite of *Dientamoeba fragilis*

- Laboratory diagnosis is made by demonstration of trophozoites in stool. At least three stool specimens should be collected over a period of 7 days.
- Metronidazole, iodoquinol, paromomycin and tetracycline have been used for treatment.

REVIEW QUESTIONS

1. Describe briefly the life cycle and laboratory diagnosis of *Giardia lamblia*.
2. Write short notes on:
 - a. *Trichomonas vaginalis*
 - b. *Dientamoeba fragilis*

MULTIPLE CHOICE QUESTIONS

1. Normal habitat of *Giardia* is
 - a. Duodenum and jejunum
 - b. Stomach
 - c. Cecum
 - d. Ileum
2. All of the following protozoans are found in small intestine except
 - a. *Giardia lamblia*
 - b. *Balantidium coli*
 - c. *Cyclospora caytanensis*
 - d. *Isospora belli*
3. The following is true of giardiasis except
 - a. Fever and presence of blood and mucus in stool
 - b. Acute or chronic diarrhea
 - c. Duodenum and jejunum are the prime sites of involvement
 - d. *Giardia* cysts are resistant to dessication
4. *Giardia lamblia* was discovered by
 - a. Giard
 - b. Robert hook
 - c. Leeuwenhoek
 - d. Losch

5. Drug of choice in giardiasis is
- Metronidazole
 - Albendazole
 - Thiabendazole
 - Diloxanide furoate
6. True about *Giardia* is
- May cause traveller's diarrhea
 - Giardia* inhabits ileum
 - Trophozoites are infective to man
 - Encystment of trophozoites occur in jejunum
7. Which one following test is used for diagnosis of *Giardia lamblia* infections
- Enterotest
 - Casoni's test
 - Parasight F test
 - Napier's test
8. Motility of *Trichomonas vaginalis* is described as
- Amoeboid
 - Jerky
 - Falling leaf
 - Lashing
9. Vaginal discharge in *Trichomonas vaginitis* is
- Colorless
 - Yellow
 - Curd-white
 - Blood stained
10. All of the following protozoan can be transmitted by sexual contact except
- Trichomonas vaginalis*
 - Entamoeba histolytica*
 - Enteromonas hominis*
 - Giardia lamblia*

Answer

1. a 2. b 3. a 4. c 5. a 6. a 7. a
8. b 9. b 10. c

Hemoflagellates

■ INTRODUCTION

The blood and tissue flagellates belong to the family *Trypanosomatidae*.

The family consists of six genera, of which two genera *Trypanosoma* and *Leishmania* are pathogenic to humans.

■ ZOOLOGICAL CLASSIFICATION OF FLAGELLATES

Phylum: Sarcomastigophora

Subphylum: Mastigophora

Class: Kinetoplastida

Order: Trypanosomatida

Family: Trypanosomatidae

Genera: *Leishmania* and *Trypanosoma*

■ GENERAL CHARACTERISTICS

- They live in the blood and tissues of man and other vertebrate hosts and in the gut of the insect vectors.
- Members of this family have a single nucleus, a kinetoplast and a single flagellum (Fig. 1).
- **Nucleus** is round or oval and is situated in the central part of the body.
- **Kinetoplast** consists of a deeply staining parabasal body and adjacent dot-like blepharoplast. The parabasal body and blepharoplast are connected by one or more thin fibrils (Fig. 1).
- **Flagellum** is a thin, hair-like structure, which originates from the blepharoplast. The portion of the flagellum, which is inside the body of the parasite and extends from the blepharoplast to surface of the body is known as **axoneme**. A free flagellum at the anterior end traverses on the surface of the parasite as a narrow undulating membrane (Fig. 1).
- Hemoflagellates exist in two or more of four morphological stages. These forms were formerly called the

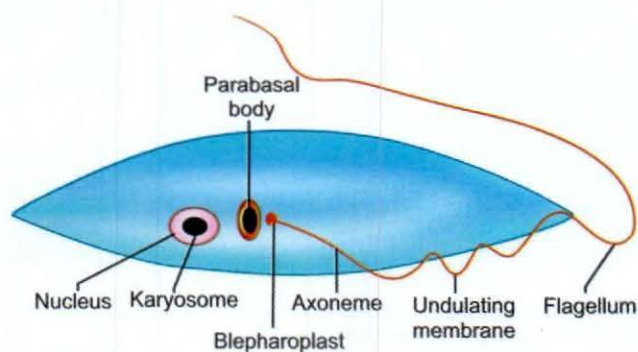
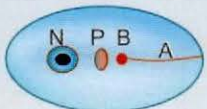
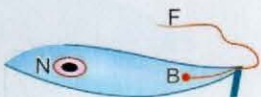
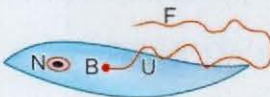
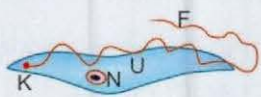


Fig. 1: Basic morphology of hemoflagellates
Note: Parabasal body and blepharoplast together constitute the kinetoplast.

leishmanial, *leptomonad*, *crithidial* and *trypanosomal* stages. But as these names are also given to different genera within the family, they were changed to *amastigote*, *promastigote*, *epimastigote* and *trypomastigote*. The names of the stages are formed by the suffix *mastigote*, combined with various prefixes, referring to the arrangement of the flagella in relation to the position of the nucleus and its point of emergence from the cells (Table 1).

- **Staining characteristics of trypanosomes:** For smears of body fluids, Romanowsky's Wrights stain, Giemsa stain and Leishman's stain are suitable for identifying internal structures. The cytoplasm appears blue, the nucleus and flagellum appear pink, and the kinetoplast appears deep red. For tissue section, hematoxylin-eosin staining is done for demonstrating structures of the parasite.
- All members of the family have similar life cycles. They all require an insect vector as an intermediate host.
- Multiplication in both the vertebrate and invertebrate host is by binary fission. No sexual cycle is known.

Table 1: Differences between various morphological stages of hemoflagellates

	<i>Amastigote</i>	<i>Promastigote</i>	<i>Epimastigote</i>	<i>Trypomastigote</i>
Morphological characteristics	Rounded or ovoid, without any external flagellum. The nucleus, kinetoplast and axial filaments can be seen. The axoneme extends up to the anterior end of the cell	Lanceolate in shape. Kinetoplast is anterior to the nucleus (antinuclear kinetoplast) near the anterior end of the cell, from which flagellum emerges. There is no undulating membrane	Elongated, with the kinetoplast placed more posteriorly, though close to and in front of the nucleus (juxtannuclear kinetoplast). The flagellum runs alongside the body as a short undulating membrane, before emerging from the anterior end	This stage is elongated, spindle-shaped with a central nucleus. The kinetoplast is posterior to the nucleus (postnuclear kinetoplast) and situated at the posterior end of the body. The flagellum runs alongside the entire length of the cell to form a long undulating membrane before emerging as a free flagellum from the anterior end
Seen in	<i>Trypanosoma cruzi</i> and <i>Leishmania</i> as intracellular form in vertebrate host	It is the infective stage of <i>Leishmania</i> , found in the insect vector as well as in cultures <i>in vitro</i>	It is the form in which <i>Trypanosoma brucei</i> occur in salivary gland of the vector tsetse fly and <i>Trypanosoma cruzi</i> in the midgut of the vector reduviid bug. Note: This stage is lacking in <i>Leishmania</i>	This is the infective stage of trypanosomes found in arthropod vector and in the blood of infected vertebrate. Note: This stage is lacking in <i>Leishmania</i>
Schematic illustration				

Abbreviations: A, axoneme; B, blepharoplast; F, flagellum; K, kinetoplast; N, nucleus; P, parabasal body; U, undulating membrane

Note: Besides the stages described in the table, some transitional stages have been recognized. These include the *spheromastigote*, a motile round form with free flagellum, which is a transitional stage from amastigote to promastigote, seen in the genus *Trypanosoma* and the *paramastigote*, a transitional form leading to the infective promastigote in *Leishmania*.

■ TRYPANOSOMES

General Characters

All members of the genus *Trypanosoma* (*trypanes*: to bore, *soma*: body), exist at sometime in their life cycle, as **trypomastigote** stage with an elongated spindle-shaped body, central nucleus, a posterior kinetoplast and long-undulating membrane. Volutin granules are found in cytoplasm. Some trypanosomes such as *T. cruzi* assume **amastigote** forms in vertebrate hosts. In addition to the typical forms, cells with atypical features are frequently found, a condition known as *polymorphism*.

- *Trypanosoma* pass their life cycle in two hosts: (1) vertebrate hosts (definitive hosts) and (2) insect vectors (intermediate hosts). Therefore called as **digenetic** parasites. The vector becomes infective to the vertebrate host only after an extrinsic incubation period, during which the parasite undergoes development and multiplication.
- In the vector, the trypanosomes follow one or two modes of development and are accordingly classified into two groups: (1) *Salivaria* and (2) *Stercoraria*.
 1. **Salivaria** (*anterior station*): In salivaria, the trypanosomes migrate to mouth parts of the vectors, so that infection is transmitted by their bite (*inoculative transmission*). Examples are *T. gambiense* and

T. rhodesiense causing African trypanosomiasis, which are transmitted by the bite of tsetse flies.

2. **Stercoraria** (*posterior station*): In stercoraria, the trypanosomes migrate to the hindgut and are passed in feces (stercorarian transmission), e.g. *T. cruzi* causing Chagas disease, which is acquired by rubbing the feces of the vector bug into the wound caused by its bite and *T. lewisi*, the rat trypanosome, which is transmitted by ingestion of feces of infected rat fleas.
- **Distribution:** Human trypanosomiasis is strictly restricted to certain geographical regions; the African and South American trypanosomiasis being seen only in the respective continents. This is due to the vector being confined to these places alone.
 - African trypanosomiasis (**sleeping sickness**)
 - South American trypanosomiasis (**Chagas disease**).

Classification of Trypanosomes

Trypanosomes Infecting Man

- **Trypanosoma brucei complex**, causing African trypanosomiasis or sleeping sickness, subspecies are:
 - *Trypanosoma brucei gambiense*: It causing West African sleeping sickness.

- *Trypanosoma brucei rhodesiense*: It causing East African sleeping sickness.
- *Trypanosoma cruzi*, causing South American trypanosomiasis or Chagas disease.
- *Trypanosoma rangeli*, a nonpathogenic trypanosome causing human infection in South America.

Trypanosomes of Animals

- *Trypanosoma brucei brucei*, causing the economically important disease “**nagana**” in African cattle.
- *Trypanosoma evansi*, causing the disease “**surra**” in horses, camels and elephants. It is transmitted mechanically by biting flies and also by vampire bats. This infection is found in India.
- *Trypanosoma equiperdum*, causing “**stallion’s disease**” in horses and mules. It is transmitted by sexual contact, without the need for an insect vector.
- *Trypanosoma lewisi*, causing harmless infection of rats all over the world. The vector is rat flea. A trypanosome resembling *Trypanosoma lewisi* was reported from Madhya Pradesh in India in peripheral blood of two persons with short-term fever.

Trypanosoma Brucei Gambiense (West African Trypanosomiasis)

History and Distribution

Trypanosomiasis is believed to have been existing in tropical Africa from antiquity (Fig. 2).

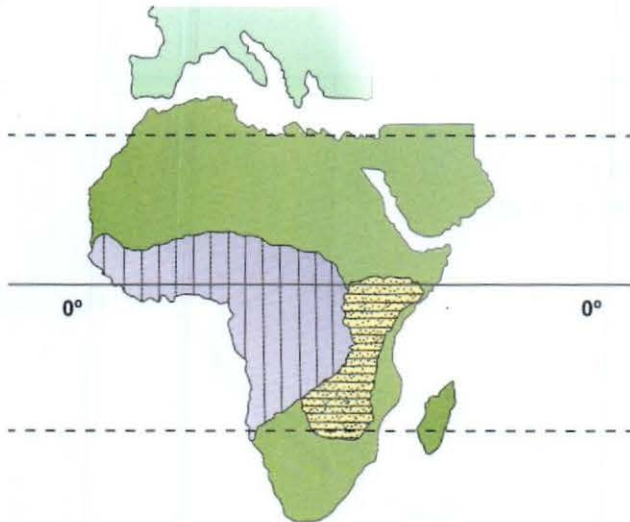


Fig. 2: Geographical distribution of trypanosomiasis in Africa. Lines indicate areas endemic for *Trypanosoma gambiense* and dots represent *Trypanosoma rhodesiense*

- Trypanosome was first isolated from the blood of a steamboat captain on the Gambia river in 1901 (hence, the name *gambiense*) by Forde.
- Dutton, in 1902, proposed the name *Trypanosoma gambiense*.
- It is endemic in scattered foci in West and Central Africa between 15°N and 18°S latitudes.

Habitat

Trypanosomes live in man and other vertebrate host. They are essentially a parasite of connective tissue, where they multiply rapidly and then invade regional lymph nodes, blood and finally may involve central nervous system.

Morphology

Vertebrate forms: In the blood of vertebrate host, *T. brucei gambiense* exists as trypomastigote form, which is highly pleomorphic.

- It occurs as a long slender form, a stumpy short broad form with attenuated or absent flagellum and an intermediate form.
- The trypomastigotes are about 15–40 μm long and 1.5–3.5 μm broad.
- In fresh blood films, trypomastigotes are seen as colorless, spindle-shaped bodies that move rapidly, spinning around the red cells.
- In smears stained with Giemsa or other Romanowsky’s stain, the cytoplasm appears pale blue and the nucleus appears red. The kinetoplast appears as a deep red dot and volutin granules stain deep blue. The undulating membrane appears pale blue and the flagellum red.

Insect forms: In insects, it occurs in two forms:

1. Epimastigotes
2. Metacyclic trypomastigote forms.

Antigenic Variation

Trypanosomes exhibit unique antigenic variation of their glycoproteins.

- There is a cyclical fluctuation in the trypanosomes in the blood of infected vertebrates after every 7–10 days.
- Each successive wave represents a *variant antigenic type (VAT)* of trypomastigote possessing *variant-specific surface antigens (VSSAs)* or *variant surface glycoprotein (VSG)* coat antigen.
- It is estimated that a single trypanosome may have as many as 1,000 or more VSG genes that help to evade immune response. Besides this, trypanosomes have other mechanisms also that help them to evade host immune responses.

Life Cycle

Host: *T. brucei gambiense* passes its life cycle in two hosts:

1. **Vertebrate host:** Man, game animals and other domestic animals.
2. **Invertebrate host:** Tsetse fly.

Both male and female tsetse fly of *Glossina* species (*G. palpalis*) are capable of transmitting the disease to humans. These flies dwell on the banks of shaded streams, wooded Savanna and agricultural areas.

Infective form: Metacyclic trypomastigote forms are infective to humans.

Mode of transmission:

- By bite of tsetse fly.
- Congenital transmission has also been recorded.

Reservoirs: Man is the only reservoir host, although pigs and others domestic animals can act as chronic asymptomatic carriers of the parasite.

Development in man and other vertebrate hosts:

- **Metacyclic stage** (infective form) of trypomastigotes are inoculated into a man (definitive host) through skin when an infected tsetse fly takes a blood meal (**Fig. 3**).

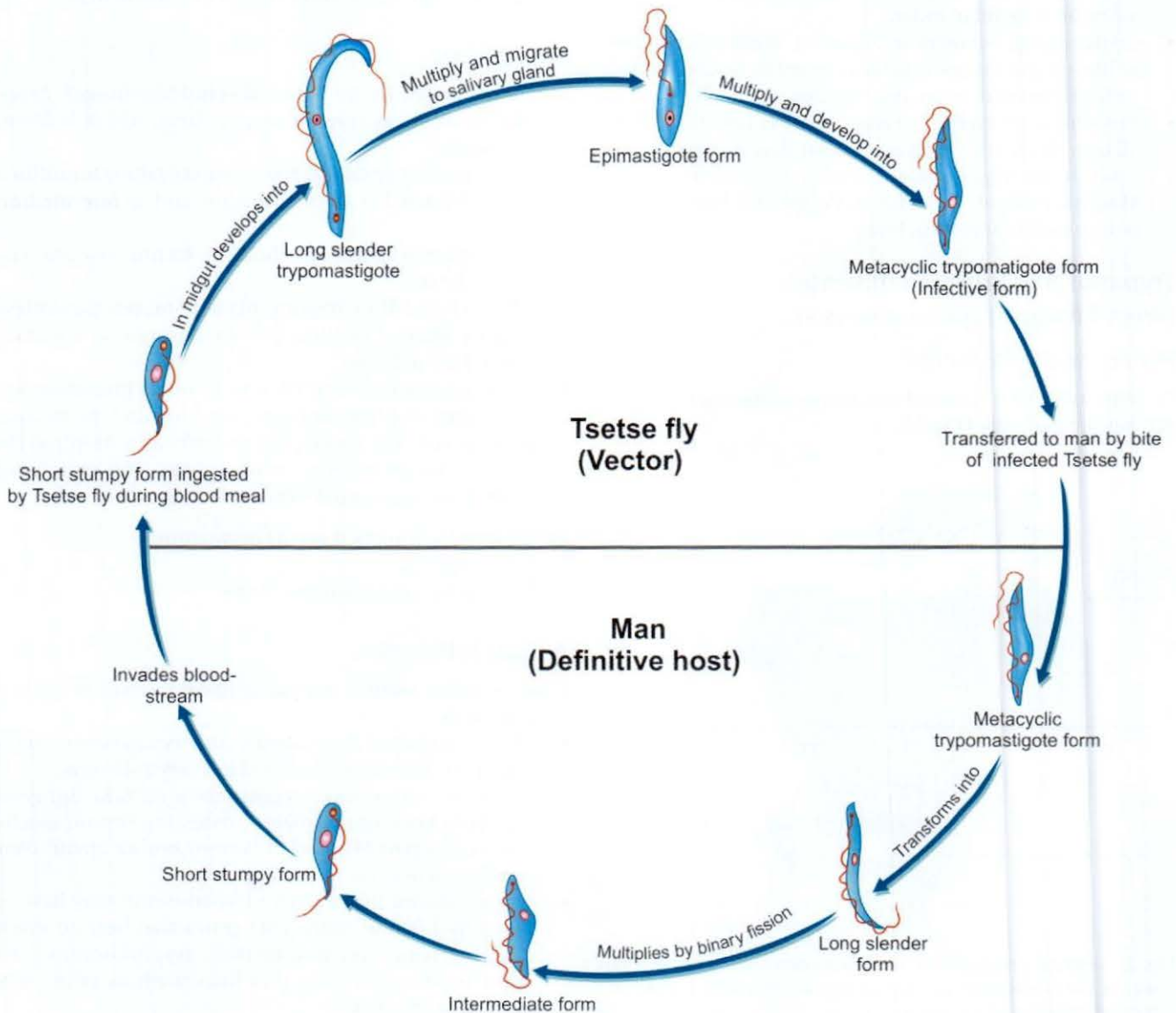


Fig. 3: Life cycle of *Trypanosoma brucei*

- The parasite transforms into **slender** forms that multiply asexually for 1–2 days before entering the peripheral blood and lymphatic circulation.
- These become “**stumpy**” via intermediate forms and enter the bloodstream.
- In chronic infection, the parasite invades the central nervous system.
- Trypomastigotes (short plumpy form) are ingested by tsetse fly (male or female) during blood meal.

Development in tsetse fly:

- In the midgut of the fly, short stumpy trypomastigotes develop into long, slender forms and multiply.
- After 2–3 weeks, they migrate to the salivary glands, where they develop into **epimastigotes**, which multiply and fill the cavity of the gland and eventually transform into the infective **metacyclic trypomastigotes** (**Fig. 3**).
- Development of the infective stage within the tsetse fly requires 25–50 days (**extrinsic incubation period**).
- Thereafter, the fly remains infective throughout its life of about 6 months.

Pathogenicity and Clinical Features

T. brucei gambiense causes African trypanosomiasis (West African sleeping sickness).

The illness is *chronic* and can persist for many years.

- There is an initial period of parasitemia, following which parasite is localized predominantly in the lymph nodes.
- A **painless chancre (trypanosomal chancre)** appears on skin at the site of bite by tsetse fly, followed by intermittent fever, chills, rash, anemia, weight loss and headache.
- Systemic trypanosomiasis without central nervous system involvement is referred to as **stage I disease**. In this stage, there is hepatosplenomegaly and lymphadenopathy, particularly in the posterior cervical region (**Winterbottom’s sign**).
- **Myocarditis** develops frequently in patients with stage I disease and is especially common in *T. brucei rhodesiense* infections.
- **Hematological manifestations** seen in stage I include anemia, moderate leukocytosis and thrombocytopenia. High levels of immunoglobulins mainly immunoglobulin M (IgM) are a constant feature.
- **Stage II disease** involves invasion of central nervous system. With the invasion of central nervous system, which occurs after several months, the “sleeping sickness” starts. This is marked by increasing headache, mental dullness, apathy and day time sleepiness. The patient falls into profound coma followed by death from asthenia (**Box 1**).
- **Histopathology** shows chronic meningoencephalitis. The meninges are heavily infiltrated with lymphocytes, plasma cells and morula cells, which are atypical plasma cells containing **mulberry-shaped** masses of IgA. Brain vessels

show perivascular cuffing. This is followed by infiltration of the brain and spinal cord, neuronal degeneration and microglial proliferation.

- Abnormalities in cerebrospinal fluid (CSF) include raised intracranial pressure, pleocytosis and raised total protein concentrations.

Trypanosoma Brucei Rhodesiense (East African Trypanosomiasis)

- It is found in Eastern and Central Africa (Uganda, Tanzania, Zambia and Mozambique) (**Fig. 2**).
- Stephens and Fantham discovered *T. brucei rhodesiense* in 1910 from the blood of a patient in Rhodesia suffering from sleeping sickness.
- The principal vector is *G. morsitans*, *G. palpalis* and *G. swynnertoni*, which live in the open savannah countries.
- Although the disease is usually transmitted by the vector from man-to-man, the disease is actually a zoonosis, with the reservoir being wild game animals like bush buck, antelope and domestic animals like cattle.
- Its morphology, habitat and life cycle is similar to *T. brucei gambiense* (**Fig. 3**).
- The difference between *T. brucei gambiense* and *T. brucei rhodesiense* are detailed in **Table 2**.

Box 1: Clinical staging of human African trypanosomiasis (HAT)

- **Stage I:** Characterized by hematogenous and lymphatic dissemination of the disease.
- **Stage II:** Characterized by central nervous system involvement.

Table 2: Differences between West African and East African trypanosomiasis

Characteristics	West African	East African
Organism	<i>T. brucei gambiense</i>	<i>T. brucei rhodesiense</i>
Distribution	West and Central Africa	East and Central Africa
Vector	Tsetse fly (<i>Glossina palpalis</i> group)	Tsetse fly (<i>Glossina morsitans</i> group)
Reservoir	Mainly humans	Wild and domestic animals
Virulence	Less	More
Course of disease	Chronic (late central nervous system invasions); months to years	Acute (early central nervous system invasion); less than 9 months
Parasitemia	Low	High and appears early
Lymphadenopathy	Early, prominent	Less common
Isolation in rodents	No	Yes
Mortality	Low	High

Pathogenesis and Clinical Features

T. brucei rhodesiense causes East African sleeping sickness (Table 2).

- East African trypanosomiasis is more **acute** than the Gambian form and appears after an incubation period of 4 weeks.
- It may end fatally within an year of onset, before the involvement of central nervous system develops.
- Pathological features are similar in both diseases with some variations:
 - Edema, myocarditis and weakness are more prominent in East African sickness (Box 2).
 - Headache, diffuse muscle and joint pain are present in majority of the patients.
 - Lymphadenitis is less prominent.
 - Febrile paroxysms are more frequent and severe.
 - There is a larger quantity of parasite in the peripheral blood.
 - Central nervous system involvement occurs early. Mania and delusions may occur but the marked somnolence, which occurs in *T. brucei gambiense* infection is lacking.

Laboratory Diagnosis

The diagnosis of both types of African trypanosomiasis is similar (Flow chart 1).

Box 2: Parasites causing myocarditis

- *Trypanosoma brucei rhodesiense*
- *Trypanosoma cruzi*
- *Toxoplasma gondii*
- *Echinococcus granulosus*
- *Trichinella spiralis*

Nonspecific findings:

- Anemia and monocytosis.
- Raised erythrocyte sedimentation rate (ESR) due to rise in gamma globulin levels.
- Reversal of albumin:globulin ratio.
- Increased CSF pressure and raised cell count and proteins in CSF.

Specific findings: Definitive diagnosis of sleeping sickness is established by the demonstration of trypanosomes in peripheral blood, bone marrow, lymph node, CSF and chancre fluid.

Microscopy:

- **Wet mount** preparation of lymph node aspirates and chancre fluid are used as a rapid method for demonstration of trypanosomes. These specimens are also examined for parasites after fixing and staining with Giemsa stain.
- Examination of Giemsa-stained thick peripheral blood smears reveals the presence of the trypomastigotes (Fig. 4).

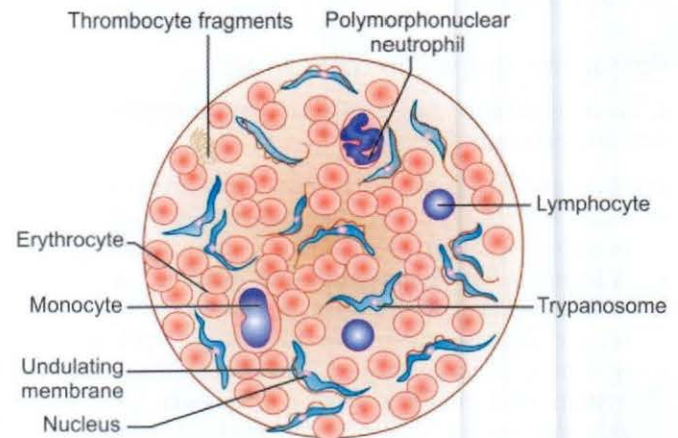
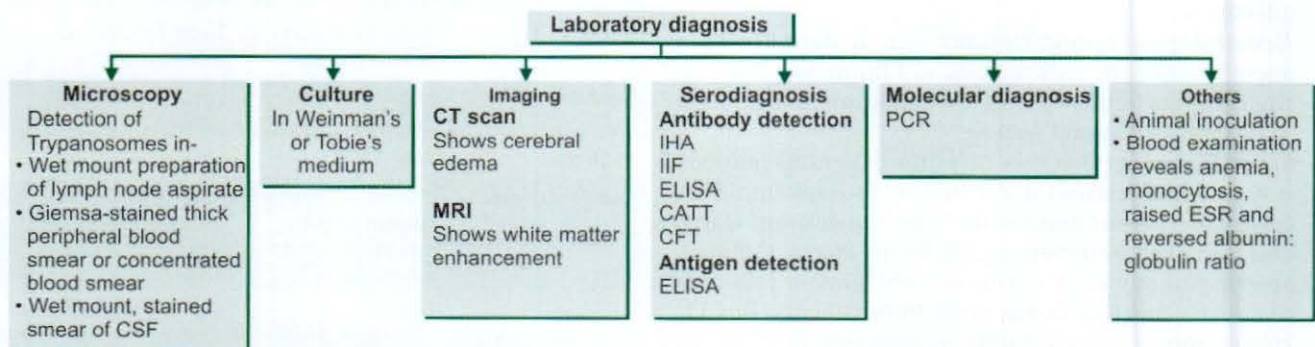


Fig. 4: *Trypanosoma rhodesiense*, blood smear Giemsa stain, magnification 1100X

Flow chart 1: Laboratory diagnosis of trypanosomiasis



Abbreviations: CATT, card agglutination trypanosomiasis test; CT, computed tomography; CFT, complement fixation test; CSF, cerebrospinal fluid; ELISA, enzyme-linked immunosorbent assay; ESR, erythrocyte sedimentation rate; IHA, indirect hemagglutination; IIF, indirect immunofluorescence; MRI, magnetic resonance imaging; PCR, polymerase chain reaction

- If parasitemia is low, then examination of concentrated blood smear is a highly sensitive method. Different concentration techniques employed are buffy coat examination, differential centrifugation, membrane filtration and ion exchange column chromatography.
- Examination of wet mount and stained smear of the CSF may also show trypanosomes (**Flow chart 1**).

Culture: The organisms are difficult to grow, hence culture is not routinely used for primary isolation of the parasite. However, it can be cultivated in Weinman's or Tobie's medium.

Animal inoculation: Inoculation of specimens from suspected cases to white rat or white mice is a highly sensitive procedure for detection of *T. brucei rhodesiense* infection.

Serodiagnosis:

Antibody detection: Almost all patients with African trypanosomiasis have very high levels of total serum IgM antibodies and later, CSF IgM antibodies. Various serological methods have been developed to detect these antibodies and are as follows:

- Indirect hemagglutination (IHA)
- Indirect immunofluorescence (IIF)
- Enzyme-linked immunosorbent assay (ELISA)
- Card agglutination trypanosomiasis test (CATT)
- Complement fixation test (CFT)

Specific antibodies are detected by these tests in serum within 2–3 weeks of infection. Specific antibodies in CSF are demonstrated by IIF and ELISA. These serological tests are useful for field use and mass screening (**Flow chart 1**).

Antigen detection: Antigens from serum and CSF can be detected by ELISA.

Molecular diagnosis: Polymerase chain reaction (PCR) assays for detecting African trypanosomes in humans have been developed, but none is commercially available.

Imaging: Computed tomography (CT) scan of the brain shows cerebral edema and magnetic resonance imaging (MRI) shows white matter enhancement in patients with late stage central nervous systems involvement (**Flow chart 1**).

Blood incubation infectivity test: For differentiation between the "human strains" and "animal strains" of *T. brucei*, the **blood incubation infectivity test (BIIT)** had been widely used.

- The strain is incubated with oxalated human blood and then inoculated into the multimammate rat or other susceptible rodents.
- The infectivity of "animal strains" will be neutralized by human blood, while "human strains" retain infectivity after incubation with human blood.
- *In vitro* culture systems are now employed instead of rodents for testing infectivity.

Table 3: Treatment of human African trypanosomiasis

Causative organism	Clinical stage	
	I (normal CSF)	II (abnormal CSF)
<i>T. brucei gambiense</i> (West African)	Pentamidine	Eflornithine
<i>T. brucei rhodesiense</i> (East African)	Suramin	Melarsoprol

Abbreviation: CSF, cerebrospinal fluid

Isoenzyme study: More recently their differentiation is based on isoenzymes, deoxyribonucleic acid (DNA) and ribonucleic acid (RNA) characteristics (**Flow chart 1**).

Treatment

In the initial stages, when central nervous system is not involved, i.e. stage I, pentamidine is the drug of choice for *gambiense* human African trypanosomiasis (HAT) and suramin is the drug of choice for *rhodesiense* HAT.

Dose:

- **Pentamidine:** Dose 3–4 mg/kg of body weight, intramuscularly daily for 7–10 days.
- **Suramin:** Dose 20 mg/kg of body weight in a course of five injections intravenously, at an interval of 5–7 days. Suramin does not cross blood-brain barrier but it is nephrotoxic.
- In patients with central nervous system involvement, **melarsoprol** (Mel-B) is the drug of choice, as it can cross the blood-brain barrier. Dose: 2–3 mg/kg/per day (maximum 40 mg) for 3–4 days (**Table 3**).

Prophylaxis

Control is based on early diagnosis and treatment of cases to reduce the reservoir of infection.

- Control of tsetse fly population (most important preventive measure) by wide spraying of insecticides, traps and baits impregnated with insecticides.
- No vaccine is available.

Trypanosoma Cruzi

T. cruzi is the causative organism of **Chagas disease** or South American trypanosomiasis.

History and Distribution

It is a zoonotic disease and is limited to South and Central America.

- **Carlos Chagas**, investigating malaria in Brazil in 1909, accidentally found this trypanosome in the intestine of a

triatomine bug and then in the blood of a monkey bitten by the infected bugs.

- Chagas named the parasite *T. cruzi* after his mentor **Oswaldo Cruz** and the disease was named as Chagas disease in his honor.

Habitat

- In humans, *T. cruzi* exists in both *amastigote* and *trypomastigote* forms:
 - Amastigotes are the intracellular parasites. They are found in muscular tissue, nervous tissue and reticuloendothelial system (**Box 3**).
 - Trypomastigotes are found in the peripheral blood.
- In *reduviid* bugs, epimastigote forms are found in the midgut and metacyclic trypomastigote forms are present in hindgut and feces.

Morphology

Amastigote: Amastigotes are oval bodies measuring 2–4 μm in diameter having a nucleus and kinetoplast (**Fig. 5A**).

- Flagellum is absent.
- Morphologically, it resembles the amastigote of *Leishmania* spp., hence, it is frequently called as *leishmanial* form.
- Multiplication of the parasite occurs in this stage.
- This form is found in muscles, nerve cells and reticuloendothelial systems.

Trypomastigote: Trypomastigotes are nonmultiplying forms found in the peripheral blood of man and other mammalian hosts (**Fig. 5B**).

- In the blood, they appear either as long, thin flagellates about (20 μm long) or short stumpy form (15 μm long).
- Posterior end is wedge-shaped.
- In stained blood smears, they are shaped-like alphabet "C", "U", or "S", having a free flagellum of about one-third the length of the body.
- These forms do not multiply in humans and are taken up by the insect vectors.

Epimastigote form: Epimastigote forms are found in the insect vector, the reduviid bug and in culture also (**Fig. 5C**).

- It has a kinetoplast adjacent to the nucleus.
- An undulating membrane runs along the anterior half of the parasite.
- Epimastigotes divide by binary fission in hindgut of the vector.

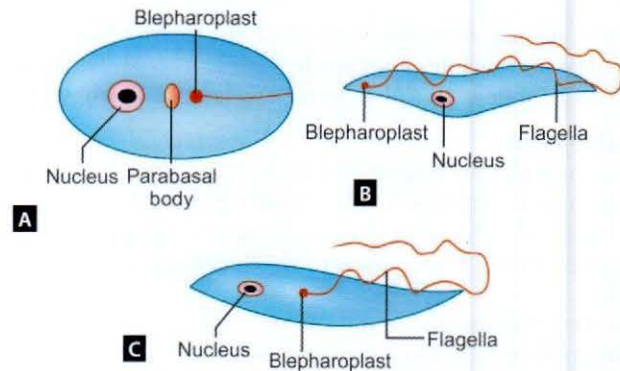
Life Cycle

Host: *T. cruzi* passes its life cycle in two hosts (**Fig. 6**):

1. **Definitive host:** Man.
2. **Intermediate host (vector):** Reduviid bug or triatomine bugs.

Box 3: Obligate intracellular parasites

- *Trypanosoma cruzi*
- *Leishmania* spp.
- *Plasmodium* spp.
- *Babesia* spp.
- *Toxoplasma gondii*
- *Microsporidia*



Figs 5A to C: *Trypanosoma cruzi*. (A) Amastigote; (B) Trypomastigote; and (C) Epimastigote

Reservoir host: Armadillo, cat, dog and pigs.

Infective form: Metacyclic trypomastigotes forms are the infective forms found in feces of reduviid bugs.

- The parasite occurs in three different but overlapping infection cycles, a *sylvatic zoonosis* in wild animals such as armadillos and opossums, *peridomestic cycle* in dogs, cats, and other domestic animals and *domestic cycle* in humans. Different vector species are active in these infection cycles.
- The vectors important in human infection are the **reduviid bugs** adapted to living in human habitations, mainly *Triatoma infestans*, *Rhodnius prolixus* and *Panstrongylus megistus*. These are large (up to 3 cm long) night-biting bugs, which typically defecate while feeding. The feces of infected bugs contain the metacyclic trypomastigote.

Mode of transmission:

- Transmission of infection to man and other reservoir hosts takes place when mucus membranes, conjunctiva, or wound on the surface of the skin is contaminated by feces of the bug containing metacyclic trypomastigotes.
- *T. cruzi* can also be transmitted by the blood transfusion, organ transplantation and vertical transmission, i.e. from mother to fetus or very rarely by ingestion of contaminated food or drink.

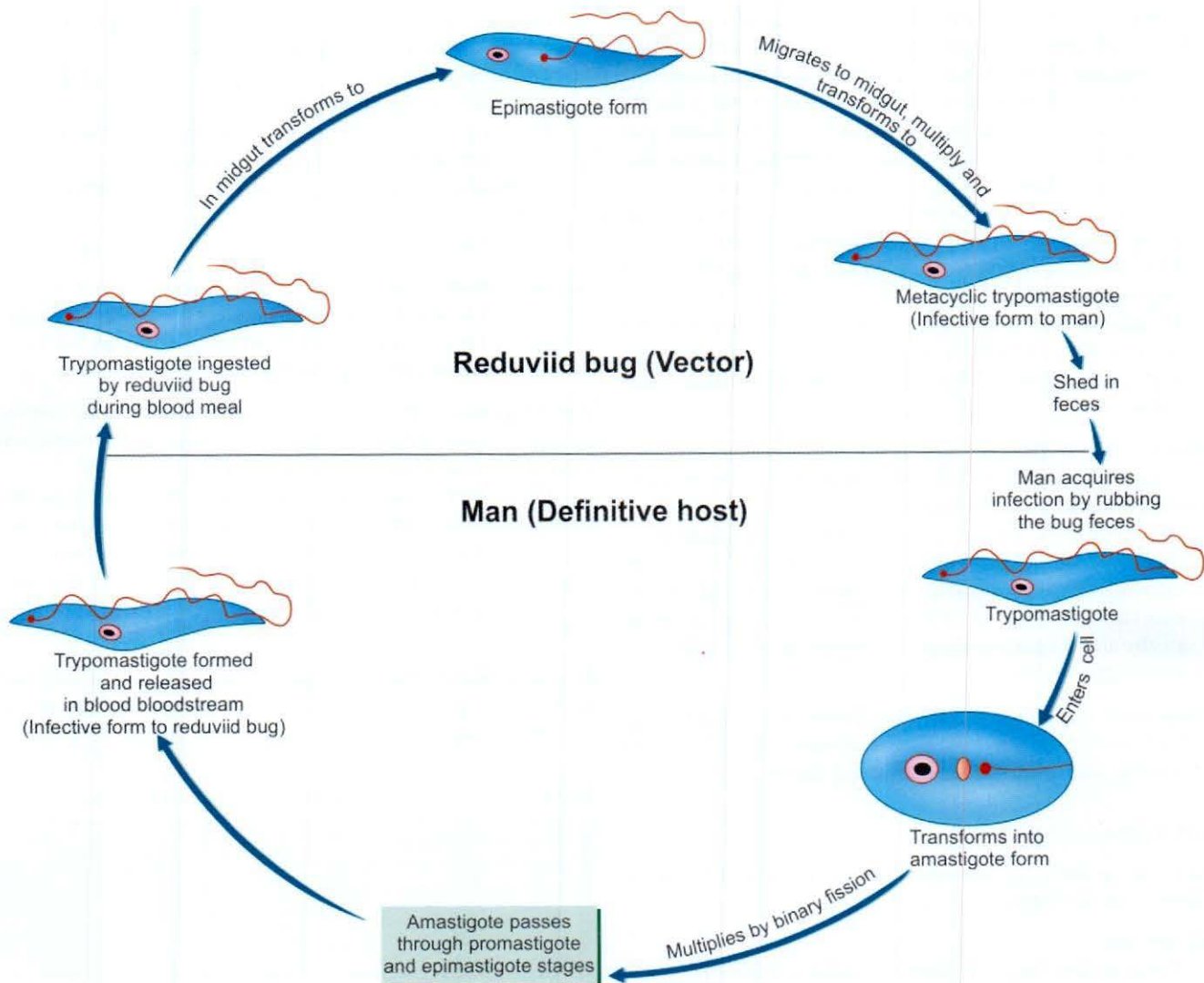


Fig. 6: Life cycle of *Trypanosoma cruzi*

Development in man:

- The *metacyclic trypomastigotes* introduced in human body by bite of reduviid bugs invade the reticuloendothelial system and spread to other tissues.
- After passing through promastigote and epimastigote forms, they again become trypomastigotes, which are released into the bloodstream and are the infective stage for triatomine bug. No multiplication occurs in this stage. Multiplication takes place only intracellularly in the amastigote form and to some extent as promastigote or epimastigotes (Fig. 6).

Development in reduviid bugs:

- Bugs acquire infection by feeding on an infected mammalian host.
- Most triatomine bugs are nocturnal.

- The trypomastigotes are transformed into epimastigotes in the midgut, from where they migrate to the hindgut and multiply.
- These, in turn, develop into *nondividing metacyclic trypomastigotes* (infective form), which are excreted in feces (stercorarian transmission).
- The development of *T. cruzi* in the vector takes 8–10 days, which constitutes the extrinsic incubation period.

Pathogenicity and Clinical Features

The incubation period of *T. cruzi* in man is 1–2 weeks. The disease manifests in acute and chronic form.

Acute chagas disease: Acute phase occurs soon after infection and may last for 1–4 months.

- It is seen often in children under 2 years of age.
- First sign appears within a week after invasion of parasite.
- "Chagoma" is the typical subcutaneous lesion occurring at the site of inoculation. Inoculation of the parasite in conjunctiva causes unilateral, painless edema of periocular tissues in the eye called as **Romana's sign**. This is a classical finding of the acute Chagas disease.
- In few patients, there may be generalized infection with fever, lymphadenopathy and hepatosplenomegaly.
- The patient may die of acute myocarditis and meningoencephalitis.
- Usually within 4–8 weeks, acute signs and symptoms resolve spontaneously and patients, then enter the asymptomatic or indeterminate phase of chronic *T. cruzi* infection.

Chronic chagas disease: The chronic form is found in adults and older children and becomes apparent years or even decades after the initial infection.

- In chronic phase, *T. cruzi* produces inflammatory response, cellular destruction and fibrosis of muscles and nerves that control tone of hollow organs like heart, esophagus, colon, etc. Thus, it can lead to cardiac **myopathy** and **megaesophagus** and **megacolon** (dilatation of esophagus and colon).

Congenital infection: Congenital transmission is possible in both acute and chronic phase of the disease causing myocardial and neurological damage in the fetus.

Laboratory Diagnosis

Diagnosis is done by demonstration of *T. cruzi* in blood or tissues or by serology.

Microscopy:

- The diagnosis of acute Chagas disease requires detection of parasites.
- Microscopic examination of fresh anticoagulated blood or the buffy coat is the simplest way to see motile organisms.
- In wet mount, trypomastigotes are faintly visible but their snake-like motion against red blood cells (RBCs) makes their presence apparent.
- Trypomastigotes can also be seen in thick and thin peripheral blood smear, stained with Giemsa stain (**Box 4**) (**Fig. 7**).
- Microhematocrit containing acridine orange as a stain can also be used.
- When used by experienced personnel, all these methods yield positive results in a high proportion of cases of acute Chagas disease.

Note: Serologic testing plays no role in diagnosing acute Chagas disease.

Culture: Novy, MacNeal and Nicolle (NNN) medium or its modifications are used for growing *T. cruzi*.

- This medium is inoculated with blood and other specimens and incubated at 22–24°C.
- The fluid from the culture is examined microscopically by 4th day and then every week for 6 weeks.
- Epimastigotes and trypomastigotes are found in the culture.
- Culture is more sensitive than smear microscopy.

Animal inoculation: Guinea pig or mice inoculation may be done with blood, CSF, lymph node aspirate, or any other tissue material and the trypomastigote is looked for in its blood smears in a few days after successful inoculation.

Xenodiagnosis: This is the method of choice in suspected Chagas disease, if other examinations are negative, especially during the early phase of the disease onset.

The reduviid bugs are reared in a trypanosome-free laboratory and starved for 2 weeks. They are then fed on patient's blood. If trypomastigotes are ingested, they will multiply and develop into epimastigotes and trypomastigotes, which can be found in the feces of the bug 2 weeks later.

Histopathology: Biopsy examination of lymph nodes and skeletal muscles and aspirate from chagoma may reveal amastigotes of *T. cruzi*.

Box 4: Protozoan parasites detected in peripheral blood film

- *Trypanosoma cruzi*
- *Trypanosoma brucei rhodesiense*
- *Trypanosoma brucei gambiense*
- *Leishmania* spp.
- *Plasmodium* spp.
- *Babesia* spp.

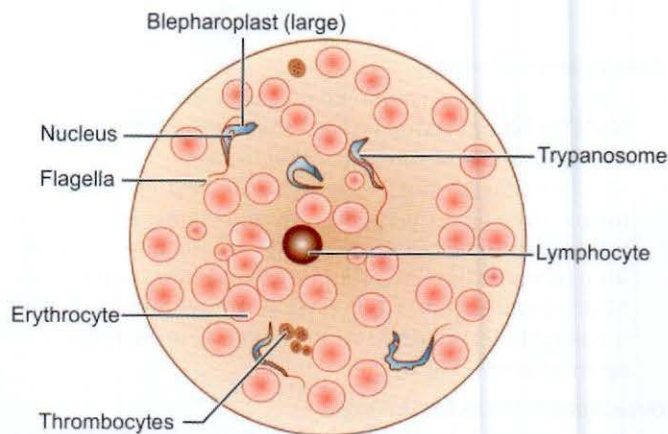


Fig. 7: *Trypanosoma cruzi*, blood smear Giemsa stain, magnification 1100X

Serology:

Antigen detection: *T. cruzi* antigen can be detected in urine and sera in patients with chronic Chagas disease. ELISA has been developed for detection of antigens.

Antibody detection: Antibodies (IgG) against *T. cruzi* may be detected by the following tests:

- Indirect hemagglutination
- Complement fixation test (Machado-Guerreiro test)
- Enzyme-linked immunosorbent assay
- Indirect immunofluorescence
- *Direct agglutination test (DAT)*: It is a simple test being recommended for field use.
- Chagas radioimmune precipitation assay (RIPA) is a highly sensitive and specific confirmatory method for detecting antibodies of *T. cruzi*.

The disadvantage of the antibody based tests is that they may be false positive with other disease like leishmaniasis and syphilis.

Intradermal test: The antigen "**cruzin**" is prepared from *T. cruzi* culture and used for the intradermal test. A delayed hypersensitivity reaction is seen.

Molecular diagnosis: Polymerase chain reaction is available that detects specific primers, which have been developed against *T. cruzi* kinetoplastic or nuclear DNA. The disadvantage of the test is that it is not commercially available.

Other tests:

- **Electrocardiography (ECG)** and chest X-ray are useful for diagnosis and prognosis of cardiomyopathy seen in chronic Chagas disease. The combination of right bundle branch block (RBBB) and left anterior fascicular block is a typical feature of Chagas heart disease.
- **Endoscopy** helps in visualization of megaesophagus in Chagas disease.

Treatment

No effective specific treatment is available for treating Chagas disease. Nifurtimox and benznidazole have been used with some success in both acute and chronic Chagas disease. These drugs kill only the extracellular trypanosomes but not the intracellular forms.

Dose: Nifurtimox: 8–10 mg/kg for adults and 15 mg/kg for children. The drug should be given orally in four divided doses each day for 90–120 days.

Benznidazole: 5–10 mg/day orally for 60 days.

Prophylaxis

- Application of insecticide to control the vector bug.
- Personal protection using insect repellent and mosquito net.

Table 4: Differences between *T. cruzi* and *T. rangeli*

<i>Trypanosoma cruzi</i>	<i>Trypanosoma rangeli</i>
• Pathogenic	Nonpathogenic
• 15–20 µm long	30 µm long, more slender and longer
• C or U-shaped	Not C or U-shaped
• <i>Kinetoplast</i> : Large and terminal	<i>Kinteoplast</i> : Small and subterminal
• Primary reservoirs: Opossums, dog, cats and wild rodents	• Primary reservoir: Wild rodents

- Improvement in rural housing and environment to eliminate breeding places of bugs.

Trypanosoma Rangeli

T. rangeli was first described by Tejera in 1920 while examining the intestinal content of reduviid bug (*R. prolixus*).

- It is nonpathogenic.
- *T. rangeli* infections are encountered in most areas where *T. cruzi* infection also occurs (Mexico, Central America and northern South America).
- Morphologically, it is similar to *T. cruzi*, except that it is slender and long (26–36 µm long) and has a smaller kinetoplast (**Table 4**).
- It is commonly found in dogs, cats and humans.
- Infection is transmitted by both bite of triatomine bug and fecal contamination from reduviid bug.
- *T. rangeli* multiplies in human blood by binary fission. Intracellular stage is typically absent.
- *T. rangeli* can circulate in blood of infected animals for a long period, unlike *T. cruzi*.
- Although *T. rangeli* appears to be a normal commensal, they do reduce the life span of reduviid bug.
- Diagnostic methods are similar to that of *T. cruzi*.

KEY POINTS OF TRYPANOSOMES

- Trypanosomes follow one of the two developmental modes in vectors. *In Salivaria*: The trypanosomes migrate to mouth parts of vector tsetse fly, e.g. *T. gambiense*, *T. rhodesiense*. *In Stercoraria*: The trypanosomes migrate to hindgut of vector bug, e.g. *T. cruzi*.
- *T. brucei gambiense* causes West African sleeping sickness manifested by fever, hepatosplenomegaly and posterior cervical lymphadenopathy with chronic central nervous system invasion.
- *T. brucei rhodesiense* causes East African sleeping sickness manifested by fever, early and acute central nervous system invasion, with loss of weight and myocarditis.
- **Diagnosis:** By detection of trypanosomes in wet mount preparations of lymph node aspirates or blood or by serology and PCR.

- **Drug of choice:** For stage I, HAT by *T. brucei gambiense* is pentamidine and by *T. brucei rhodesiense* is suramin. In stage II, the drug of choice is melarsoprol in both cases.
- South American trypanosomiasis (Chagas disease) is caused by *T. cruzi*.
- It is transmitted by wound or conjunctival contamination of feces of the reduviid bugs.
- **Clinical features:** "Chagoma" is the typical subcutaneous lesion commonly on face (Romana's sign) in Chagas disease. Damage to nerve cells and muscles leads to megaesophagus, megacolon and cardiac myopathy.
- **Diagnosis:** By demonstration of *T. cruzi* in blood or tissue or by serology and xenodiagnosis.
- **Treatment:** Nifurtimox and benznidazole.

LEISHMANIA

General Characteristics

The genus *Leishmania* is named after Sir William Leishman, who discovered the flagellate protozoa causing kala-azar, the Indian visceral leishmaniasis (VL).

- All members of the genus *Leishmania* are *obligate intracellular parasites* that pass their life cycle in **two hosts**: (1) The mammalian host, and (2) the insect vector, female sandfly.
- In humans and other mammalian hosts, they multiply within macrophages, in which they occur exclusively in the **amastigote form**, having an ovoid body containing a nucleus and kinetoplast.
- In the sandfly, they occur in the **promastigote form**, with a spindle-shaped body and a single flagellum arising from anterior end.
- Leishmaniasis has an immense geographical distribution in the tropics and subtropics of the world, extending through most of the Central and South America, part of North America, Central and South-East Asia, India, China, the Mediterranean region and Africa.
- The disease affects the low socioeconomic group of people. Overcrowding, poor ventilation and collection of organic material inside house facilitate its transmission.
- Across the tropics, three different diseases are caused by various species of genus *Leishmania*. These are:
 1. **Visceral leishmaniasis:** The species *L. donovani* complex infecting internal organs (liver, spleen and bone marrow) of human is the causative parasite.
 2. **Cutaneous leishmaniasis:** The species *L. tropica* complex, *L. aethiops*, *L. major* and *L. mexicana* complex are the causative parasite.
 3. **Mucocutaneous leishmaniasis:** It is caused by the *L. braziliensis* complex.

Classification

The genus *Leishmania* includes a number of different varieties and subspecies, which differ in several features such as antigenic structure, isoenzymes, and other biochemical characteristics, growth properties, host specificity, etc. (Table 5).

Leishmania species can also be classified on the basis of geographical distribution as given in Tables 5 and 6.

The various manifestations of leishmaniasis and *Leishmania* species causing them have been summarized in Flow chart 2.

Old World Leishmaniasis

Leishmania Donovanii

L. donovani causes VL or **kala-azar**. It also causes the condition, **Post-kala-azar dermal leishmaniasis (PKDL)**.

History and distribution: Sir William Leishman in 1900, observed the parasite in spleen smears of a soldier who died of "dumdum fever" or kala-azar contracted at Dum Dum, Calcutta. **Leishman** reported this finding from London in 1903. In the same year, **Donovan** also reported the same parasite in spleen smears of patients from Madras. The name *Leishmania donovani* was, therefore given to this parasite. The amastigote forms of the parasite as seen in smears from patients are called *Leishman-Donovan (LD)* bodies.

- Visceral leishmaniasis or kala-azar is a major public health problem in many parts of world. According to the World Health Organization (WHO), a total of 500,000 cases of VL occur every year. Of these new cases, 90% are found in the Indian subcontinent and Sudan and Brazil.
- The disease occurs in endemic, epidemic, or sporadic forms. Major epidemics of the disease are currently found in India, Brazil and Sudan (Fig. 8).
- The resurgence of kala-azar in India, beginning in the mid 1970s, assumed epidemic proportions in 1977 and involved over 110,000 cases in humans. Initially, the disease was confined to Bihar (Muzaffarpur, Samastipur, Vaishali and Sitamarhi). Since then, the cases are increasing and involving newer areas. The epidemic extended to West Bengal and first outbreak occurred in 1980 in Malda district.
- At present, the disease has established its endemicity in 31 districts in Bihar, 11 districts in West Bengal, five districts in Jharkhand and three districts in Uttar Pradesh. Sporadic cases have been reported from Tamil Nadu, Maharashtra, Karnataka and Andhra Pradesh.

Habitat: The amastigote (LD body) of *L. donovani* is found in the reticuloendothelial system. They are found mostly within

Table 5: *Leishmania* species involved in human disease

Species	Disease	Geographical distribution	Vector	Reservoir	Transmission
<i>Leishmania donovani</i>	Visceral leishmaniasis (kala-azar or dum-dum fever)	Middle East, Africa and Indian subcontinent	<i>Phlebotomus argentipes</i> , <i>Phlebotomus orientalis</i>	Humans	Anthroponotic, occasionally zoonotic
<i>Leishmania infantum</i>	Visceral leishmaniasis, cutaneous leishmaniasis	Mediterranean coast, Middle East and China	<i>Phlebotomus perniciosus</i> , <i>Phlebotomus ariasi</i> , <i>Phlebotomus papatasi</i>	Dog, fox, jackal and wolf	Zoonotic
<i>Leishmania chagasi</i>	Visceral leishmaniasis	Tropical South America	<i>Lutzomyia longipalpis</i>	Fox and wild canines	Zoonotic
<i>Leishmania tropica</i>	Cutaneous leishmaniasis (oriental sore, Baghdad boil)	Middle East and Central Asia	<i>Phlebotomus sergenti</i>	Humans	Anthroponotic
<i>Leishmania major</i>	Cutaneous leishmaniasis	Africa, Indian subcontinent and Central Asia	<i>Phlebotomus papatasi</i> , <i>Phlebotomus dubosqi</i>	Gerbil	Zoonotic
<i>Leishmania aethiopica</i>	Cutaneous and diffuse cutaneous leishmaniasis	Ethiopia and Kenya	<i>Phlebotomus longipes</i> , <i>Phlebotomus pedifer</i>	Hydraxes	Zoonotic
<i>Leishmania braziliensis</i> complex	Mucocutaneous leishmaniasis (Espundia)	Tropical South America	<i>Lutzomyia umbratilis</i>	Forest rodents and peridomestic animals	Zoonotic
<i>Leishmania mexicana</i> complex	Mucocutaneous leishmaniasis (Chiclero's ulcer)	Central America and Amazon basin	<i>Lutzomyia olmeca</i> , <i>Lutzomyia flaviscutellata</i>	Forest rodents and marsupials	Zoonotic

Table 6: Classification of *Leishmania* based on geographical distribution

Old world leishmaniasis	New world leishmaniasis
• <i>Leishmania donovani</i>	• <i>Leishmania braziliensis</i> complex
• <i>Leishmania infantum</i>	• <i>Leishmania mexicana</i> complex
• <i>Leishmania tropica</i>	• <i>Leishmania chagasi</i>
• <i>Leishmania major</i>	• <i>Leishmania peruviana</i>
• <i>Leishmania aethiopica</i>	

the macrophages in the spleen, liver, bone marrow and less often in other locations such as skin, intestinal mucosa and mesenteric lymph nodes.

Morphology: The parasite exists in two forms (Figs 9A and B):

1. *Amastigote form:* In humans and other mammals.
2. *Promastigote form:* In the sandfly and in artificial culture.

Amastigote: The amastigote form (LD body) is an ovoid or rounded cell, about 2–4 µm in size (Fig. 9A).

- It is typically intracellular, being found inside macrophages, monocytes, neutrophils, or endothelial cells.
- They are also known as **LD bodies**.

- Smears stained with Leishman, Giemsa, or Wright's stain show a pale blue cytoplasm enclosed by a limiting membrane.
- The large oval nucleus is stained red. Lying at the right angles to nucleus, is the red or purple-stained **kinetoplast**.
- In well-stained preparations, the kinetoplast can be seen consisting of a **parabasal body** and a dot-like **blepharoplast** with a delicate thread connecting the two. The **axoneme** arising from the blepharoplast extends to the anterior tip of the cell.
- Alongside the kinetoplast a clear unstained **vacuole** can be seen.
- Flagellum is absent.

Promastigote: It is a flagellar stage and is present in insect vector, sandfly and in cultures.

- The promastigotes, which are initially short, oval or pear-shaped forms, subsequently become long spindle-shaped cells, 15–25 µm in length and 1.5–3.5 µm in breadth (Fig. 9B).
- A single nucleus is situated at the center. The kinetoplast lies transversely near the anterior end.
- The flagellum is single, delicate and measures 15–28 µm.

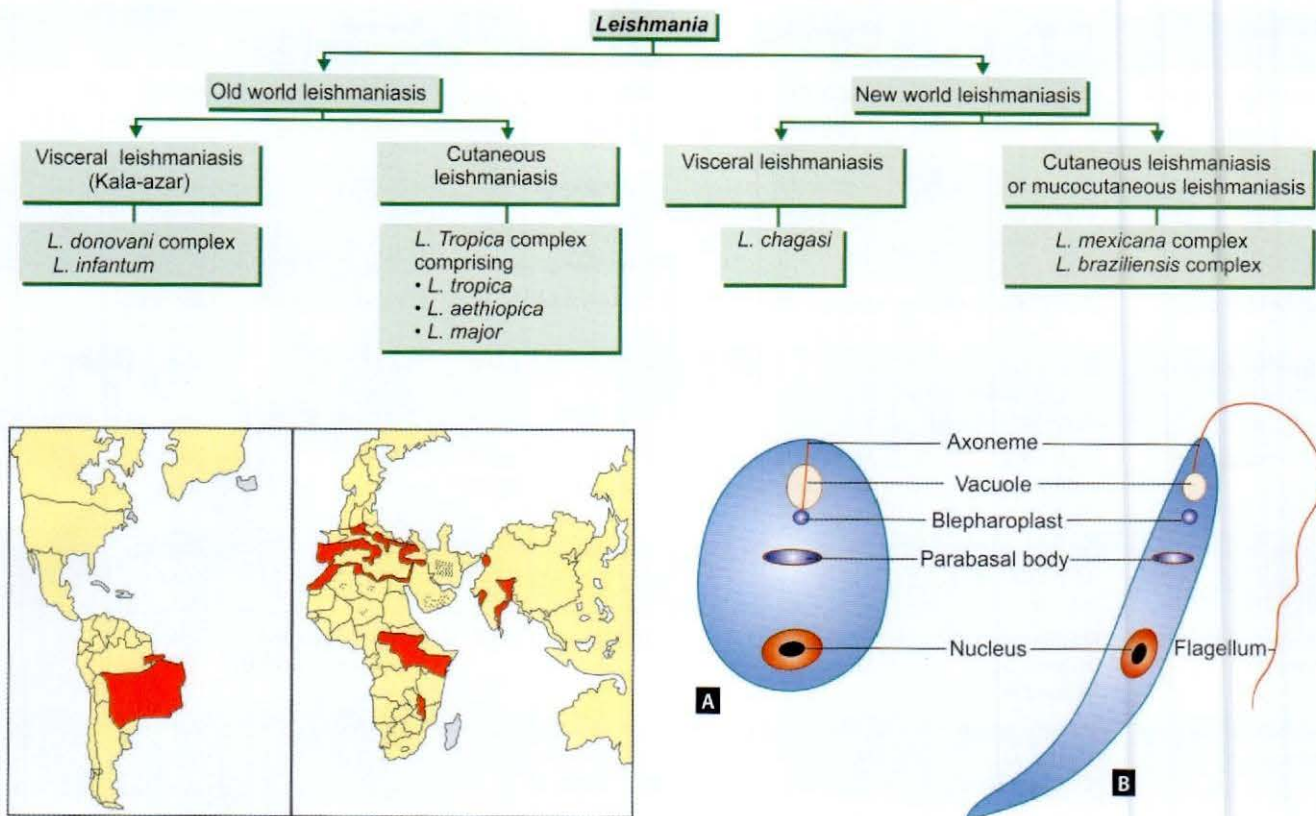
Flow chart 2: Distribution and disease caused by *Leishmania* spp.

Fig. 8: Geographical distribution of visceral leishmaniasis. Endemic areas shaded; dots indicate sporadic cases

Figs 9A and B: Morphology of *Leishmania donovani*. (A) Amastigote [Leishman-Donovan (LD) body]; and (B) Promastigote

- Giemsa or Leishman-stained films show pale blue cytoplasm with a pink nucleus and bright red kinetoplast.
- A vacuole is present near the root of the flagellum.
- There is no undulating membrane.
- Promastigote forms, which develop in artificial cultures, have the same morphology as in the sandfly.

Life cycle: *L. donovani* completes its life cycle in two hosts (Fig. 10):

1. **Definitive host:** Man, dog and other mammals.
2. **Vector:** Female sandfly (*Phlebotomus* species) (Table 7).

Infective form: Promastigote form present in midgut of female sandfly.

Mode of transmission:

- Humans acquire by bite of an infected female sandfly.
- It can also be transmitted vertically from mother to fetus, by blood transfusion and accidental inoculation in the laboratory.

Incubation period: Usually 2–8 months, occasionally, it may be as short as 10 days or as long as 2 years.

- The sandfly regurgitates the promastigotes in the wound caused by its proboscis.
- These are engulfed by the cells of reticuloendothelial system (macrophages, monocytes and polymorphonuclear leukocytes) and change into amastigote (LD body) within the cells.
- The amastigote multiplies by binary fission, producing numerous daughter cells that distend the macrophage and rupture it. The liberated daughter cells are in turn, phagocytosed by other macrophages and histiocytes. Small number of LD bodies can be found in peripheral blood inside neutrophils or monocytes (Fig. 10).
- When a vector sandfly feeds on an infected person, the amastigotes present in peripheral blood and tissue fluids enter the insect along with its blood meal. In the midgut (stomach) of the sandfly, the amastigote elongates and develops into the promastigote form (Fig. 10).
- The promastigote multiplies by longitudinal binary fission and reaches enormous numbers. They may be seen as large rosettes with their flagella entangled.

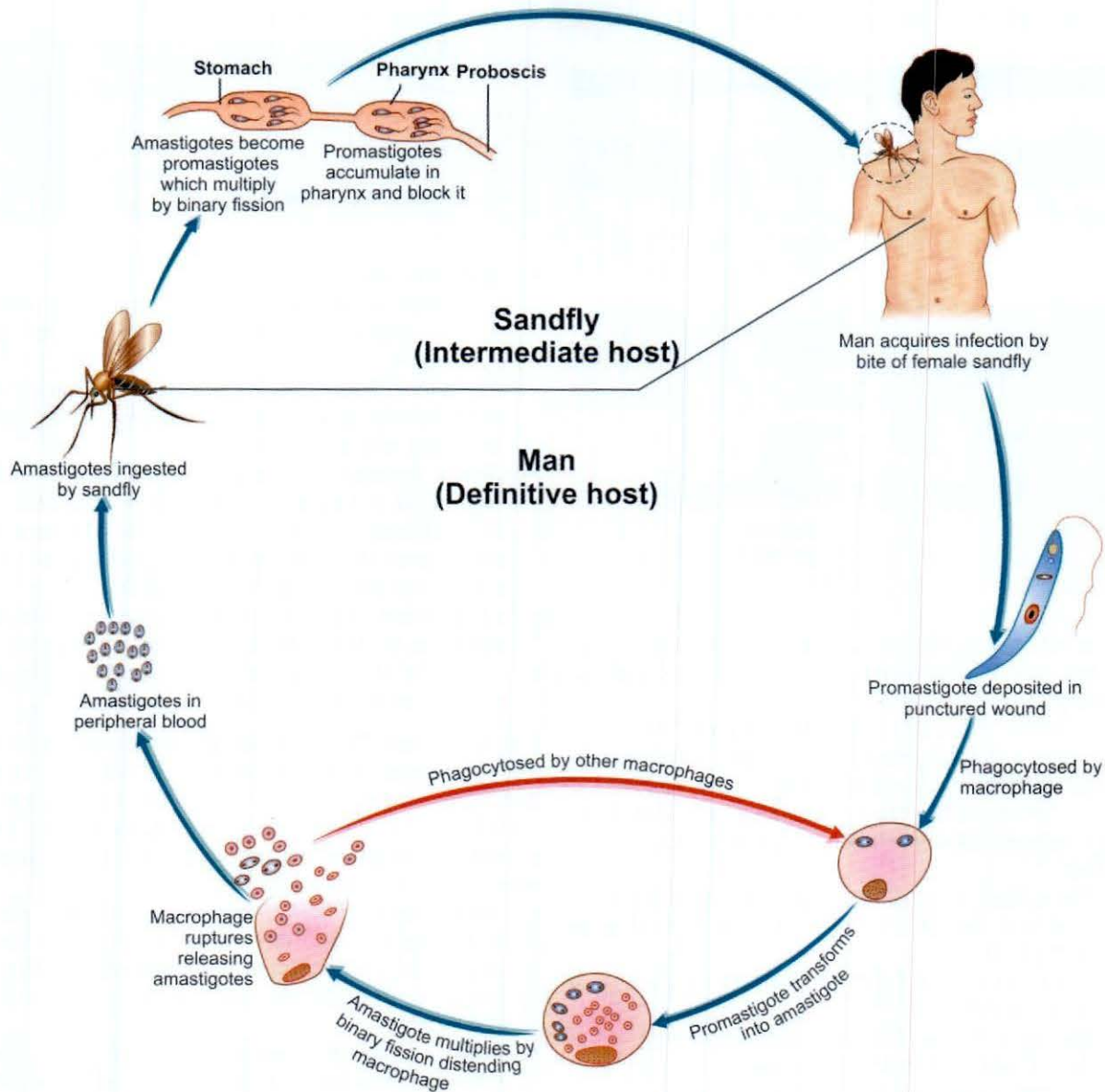


Fig. 10: Life cycle of *Leishmania donovani*

- In the sandfly, they migrate from the midgut to the pharynx and hypostome, where they accumulate and block the passage.
- Such **blocked sandflies** have difficulty in sucking blood. When they bite a person and attempt to suck blood, plugs of adherent parasites may get dislodged from the pharynx and they are deposited in the punctured wound. It takes about **10 days** for the promastigotes to reach adequate numbers after ingestion of the amastigotes, so as to block the buccal cavity and pharynx of the sandfly. This is, therefore, the duration of **extrinsic incubation period**.

This period is also synchronous with the gonadotropic cycle of the vector, so that amastigotes ingested during a single blood meal, are ready to be transmitted when the sandfly takes the next blood meal after its eggs have been laid.

Pathogenicity: *L. donovani* causes VL or kala-azar.

- Kala-azar is a reticuloendotheliosis resulting from the invasion of reticuloendothelial system by *L. donovani*.
- The parasitized macrophages disseminate the infection to all parts of the body.
- Three major surface membrane proteins of *Leishmania*, namely (1) *gp63*, (2) *lipophosphoglycan (LPG)* and

Table 7: Vector species responsible for transmission of *Leishmania donovani*

Country	<i>Phlebotomus</i> species
India	• <i>P. argentipes</i>
China, Bangladesh	• <i>P. chinensis</i> • <i>P. sergenti</i>
Sudan and Africa	• <i>P. perniciosus</i> • <i>P. orientalis</i> (Sudan) • <i>P. longicuspis</i> • <i>P. sergenti</i>
Mediterranean countries	• <i>P. perniciosus</i> • <i>P. papatasi</i> • <i>P. major</i> • <i>P. tobbi</i>
Middle East and Russia	• <i>P. perfulvievi</i> • <i>P. papatasi</i>
Central Asia	• <i>P. papatasi</i>
South America	• <i>P. longipalpis</i> • <i>P. intermudias</i> • <i>P. lutzi</i>

(3) *glycosylphosphatidylinositols* (GPIs) give protection against hydrolytic enzymes of macrophage phagolysosome.

- In the spleen, liver and bone marrow particularly, the amastigotes multiply enormously in the fixed macrophages to produce a "blockade" of the reticuloendothelial system. This leads to a marked proliferation and destruction of reticuloendothelial tissue in these organs.
- **Spleen:**
 - The spleen is the most affected organ. It is *grossly enlarged* and the capsule is thickened due to perisplenitis.
 - Spleen is *soft and friable* and cuts easily due to absence of fibrosis.
 - The cut section is *red or chocolate* in color due to the dilated and engorged vascular spaces.
 - The trabeculae are thin and atrophic.
 - Microscopically, the reticulum cells are greatly increased in numbers and are loaded with LD bodies.
 - Lymphocytic infiltration is scanty, but plasma cells are numerous.
- **Liver:**
 - The liver is enlarged.
 - The Kupffer cells and vascular endothelial cells are heavily parasitized, but hepatocytes are not affected.
 - Liver function is, therefore, not seriously affected, although prothrombin production is commonly decreased.
 - The sinusoidal capillaries are dilated and engorged.
 - Some degree of fatty degeneration is seen. The cut surface may show a "nutmeg" appearance.

Box 5: Causes of anemia in kala-azar

- Splenic sequestration of red blood cells (RBCs)
- Decreased erythropoiesis due to replacement of bone marrow with parasitized macrophages
- Autoimmune hemolysis
- Hemorrhage
- Marrow suppression by cytokines.

- **Bone marrow:**

- The bone marrow is heavily infiltrated with parasitized macrophages, which may crowd the hematopoietic tissues.

- **Peripheral lymph nodes** and lymphoid tissues of the nasopharynx and intestine are hypertrophic, although this is not seen in Indian cases.
- **Severe anemia** with hemoglobin levels of 5–10 g/dL may occur in kala-azar, as a result of infiltration of the bone marrow as well as by the increased destruction of erythrocytes due to hypersplenism. Autoantibodies to red cells may contribute to hemolysis (**Box 5**).
- **Leukopenia** with marked **neutropenia** and **thrombocytopenia** are frequently seen. Antibodies against white blood cells (WBCs) and platelets suggest an autoimmune basis for the pancytopenia observed in kala-azar.

Ecological types: The epidemiology and clinical features of VL and the ecology of the parasite are very different in different geographical areas. The different clinical syndromes have, therefore been considered to be distinct entities and the parasite causing them have been given separate species or subspecies status, as listed here:

- **Indian visceral leishmaniasis:** Caused by *L. donovani* producing the anthroponotic disease kala-azar and its sequel PKDL. The disease is not zoonotic; *human beings being the only host and reservoir*. Vector is the sandfly, *P. argentipes*.
- **Mediterranean leishmaniasis:** Middle Eastern leishmaniasis caused by *L. donovani infantum* affecting mostly young children. It is a *zoonotic disease*; the reservoir being dog and wild canines such as foxes, jackals and wolves. Vectors are *P. perniciosus* and *P. papatasi*.
- **American (New World) visceral leishmaniasis:** Caused by *L. chagasi*. It is present in most parts of Latin America and resembles the disease caused by *L. infantum*. The main vector is *L. longipalpis*.

Clinical features of kala-azar:

- The onset is typically insidious. The clinical illness begins with **high-grade fever** which may be remittent with twice daily spikes or intermittent or less commonly continuous.
- **Splenomegaly** starts early and is progressive and massive (**Fig. 11**). It is usually soft and nontender.
- **Hepatomegaly** is moderate.

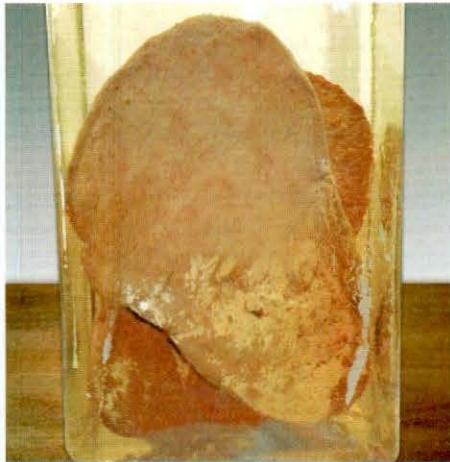


Fig. 11: Kala-azar spleen showing a greatly enlarged organ

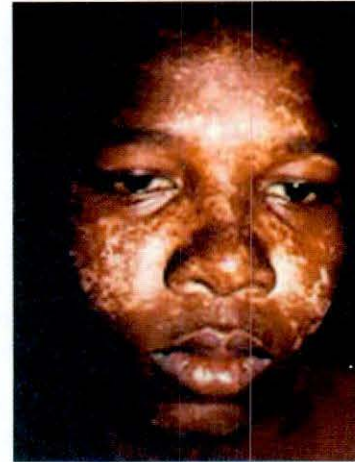

Fig. 12: Erythematous patches (Butterfly distribution)

- **Lymphadenopathy** is common in most endemic areas except Indian subcontinent.
- Skin becomes *dry, rough* and *darkly pigmented* (hence, the name *kala-azar*).
- The hair becomes thin and brittle.
- **Cachexia** with marked anemia, **emaciation** and loss of weight is seen.
- **Hematological abnormalities:**
 - *Anemia* is most always present and is usually severe
 - *Leukopenia*
 - *Thrombocytopenia* is associated with epistaxis, gum bleeding, gastrointestinal (GI) bleeding.
- **Ascites** and **edema** may occur due to hypoalbuminemia.
- **Renal involvement** is also common.
- In late stage of human immunodeficiency virus (HIV) infection VL can present as opportunistic infection. *HIV coinfection* rate is 5% in India and 20% in African countries.
- **Secondary infections** such as herpes, measles, pneumonia, tuberculosis, bacillary dysentery may occur.
- Most untreated patients die in about 2 years, due to some intercurrent disease such as dysentery, diarrhea and tuberculosis.

Post-kala-azar dermal leishmaniasis: About 3–10% cases of patients of VL in endemic areas develop PKDL, about an year or 2 after recovery from the systemic illness.

- Post-kala-azar dermal leishmaniasis is seen mainly in India and East Africa and not seen elsewhere. The Indian and African diseases differ in several aspects; important features of PKDL in these two regions are listed in **Table 8**.
- Post-kala-azar dermal leishmaniasis is a nonulcerative lesion of skin. The lesions are of three types:
 1. **Depigmented or hypopigmented macules:** These commonly appear on the face, the trunk and extremities and resemble tuberculoid leprosy.

Table 8: Differences between post-kala-azar dermal leishmaniasis (PKDL) of India and East Africa

Characteristics	India	East Africa
Incidence	5%	50%
Time interval between visceral leishmaniasis and PKDL	Occurs after visceral leishmaniasis. May take 3–5 years	Occurs during visceral leishmaniasis
Age group affected	Any age	Mostly children
Appearance of rash	Rashes appear after visceral leishmaniasis	Rashes may appear during visceral leishmaniasis
Spontaneous cure	Not seen	Seen
Duration of treatment with sodium stibogluconate	60–120 days	60 days

2. **Erythematous patches:** These are distributed on the face in a “butterfly distribution” (Fig. 12).
3. **Nodular lesion:** Both of the earlier mentioned lesions may develop into painless yellowish pink nonulcerating granulomatous nodules.
 - The parasite can be demonstrated in the lesions.

Diagnosis of post-kala-azar dermal leishmaniasis:

- The nodular lesions are biopsied and amastigote forms are demonstrated in stained sections.
- The biopsy material can be cultured or animal inoculation can be done.
- Immunodiagnosis has no role in the diagnosis of PKDL.

Treatment of post-kala-azar dermal leishmaniasis:

- Liposomal amphotericin-B (AmBisome) 2.5 mg/kg/day for 20 days or sodium stibogluconate (SSG) 20 mg/kg/day for 40–60 days are given.

Immunity:

- The immune response in VL is very complex.
- There is increased production of proinflammatory cytokines and chemokines. Interleukin-10 (IL-10) and transforming growth factor- β (TGF- β) are the dominant cytokines.
- The most important immunological feature in kala-azar is the marked suppression of cell-mediated immunity to leishmanial antigens. This makes unrestricted intracellular multiplication of the parasite possible. Cellular responses to tuberculin and other antigens are also suppressed and may be regained some 6 weeks after recovery from the disease.
- In contrast, there is an overproduction of immunoglobulins, both specific antileishmanial antibodies as well as nonspecific polyclonal IgG and IgM. Circulating immune complexes are demonstrable in serum.

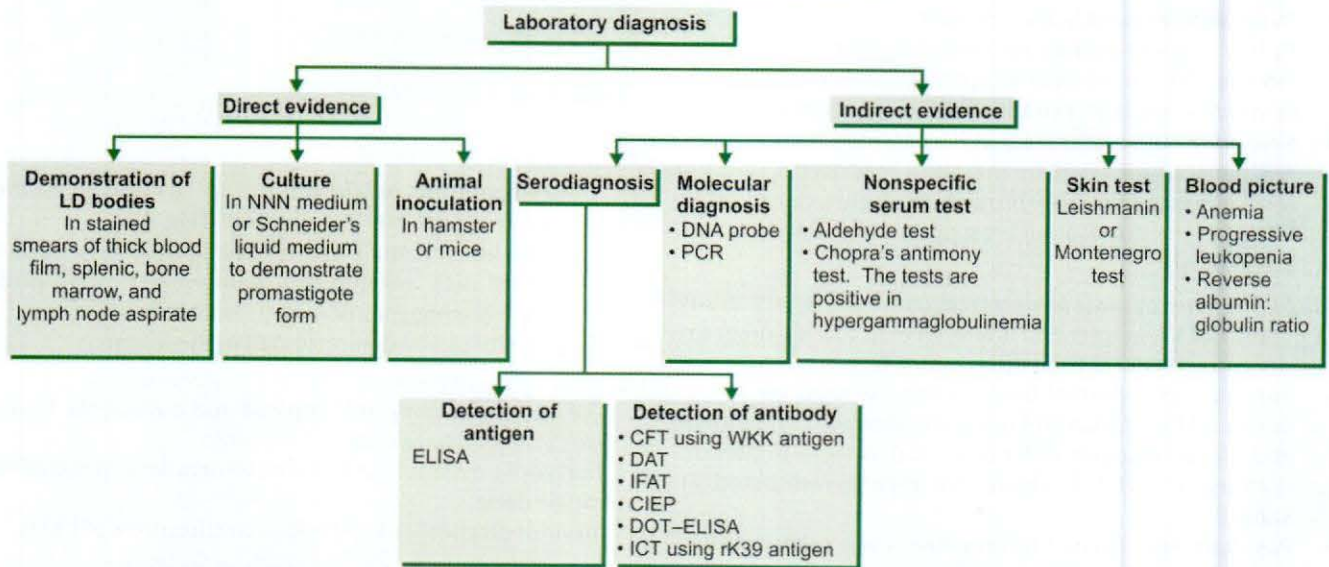
Laboratory diagnosis: Laboratory diagnosis of kala-azar depends upon direct and indirect evidences (**Flow chart 3**).

Direct evidence:**Microscopy:**

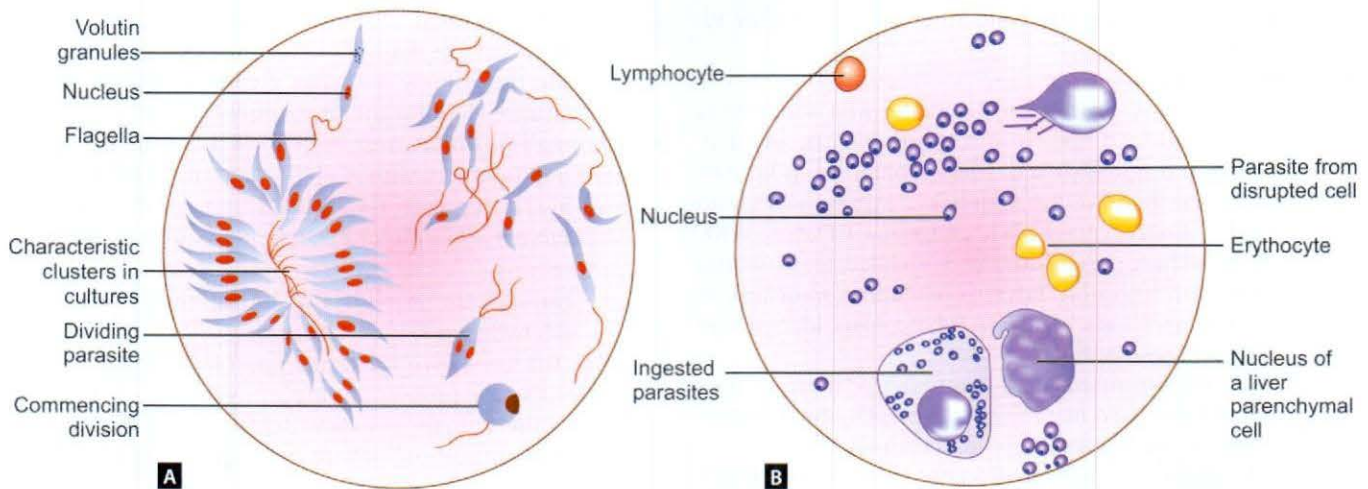
- Demonstration of amastigotes in smears of tissue aspirates is the *gold standard* for diagnosis of VL.
- For microscopic demonstration of the parasite, the materials collected are:
 - Peripheral blood
 - Bone marrow
 - Splenic aspirate

- Enlarged lymph node.
- The smears are stained by Leishman, Giemsa, or Wright's stains and examined under oil immersion objective.
- Amastigote parasite can be seen within the macrophages, often in large numbers. A few extracellular forms can also be seen.
- **Peripheral blood smear:**
 - Peripheral blood contains the amastigotes present inside circulating monocytes and less often in neutrophils, but the numbers are so scanty that a direct blood smear may not show them.
 - Chances of detecting them are somewhat improved by examination of a thick blood film.
 - It is best to examine *buffy coat smear*, although even these are not often found positive.
 - Buffy coat smears show a diurnal periodicity, more smears being positive when collected during the day than at night.
- **Bone marrow aspirate:**
 - Bone marrow aspirate is the most common diagnostic specimen collected.
 - Generally, the **sternal marrow** is aspirated by puncturing the sternum at the level of the 2nd or 3rd intercostal space, using a sternal puncture needle.
 - Bone marrow samples can also be obtained by puncturing the **iliac crest**.
- **Splenic aspirates:**
 - Splenic aspirates are richer in parasites and therefore, are more valuable for diagnosis.

Flow chart 3: Laboratory diagnosis of kala-azar



Abbreviations: CFT, complement fixation test; CIEP, counter immunoelectrophoresis; DAT, direct agglutination test; DNA, deoxyribonucleic acid; ELISA, enzyme-linked immunosorbent assay; ICT, immunochromatographic test; IFAT, indirect immunofluorescent antibody test; LD, Leishman-Donovan; NNN, Novy, MacNeal and Nicolle; PCR, polymerase chain reaction; rK39, recombinant kinesin 39



Figs 13A and B: *Leishmania donovani*. (A) Culture form (Giemsa stain, magnification 1100X); and (B) Liver smear (Giemsa stain, magnification 1100X)

- But, the procedure can sometimes cause dangerous bleeding and therefore, should be done carefully and only when a marrow examination is inconclusive.
- **Lymph node aspirates:** Lymph node aspirates are not useful in the diagnosis of Indian kala-azar, although it is employed in VL in some other countries.
- **Comparison of aspiration biopsies:** Although splenic aspiration is the most sensitive method (98% positive), bone marrow puncture (50–85%, positive) is a safer procedure when compared to spleen puncture, as there is risk of hemorrhage in splenic puncture particularly in patients with advanced stage of disease with soft enlarged spleen. Splenic aspiration is contraindicated in patients with **prolonged prothrombin time**, or if platelet count is less than $40,000/\text{mm}^3$. Liver biopsy is also not a safe procedure and carries a risk of hemorrhage. Lymph node aspiration is positive in 65% of cases of African kala-azar, but not useful in cases of Indian kala-azar.

Culture: Different tissue materials or blood are cultured on **NNN medium** (described by **Novy, MacNeal and Nicolle**). This is a rabbit blood agar slope consisting of two parts of salt agar and one part of defibrinated rabbit blood. The material is inoculated into the **water of condensation** and culture is incubated at $22\text{--}24^\circ\text{C}$ for 1–4 weeks. At the end of each week, a drop of culture fluid is examined for promastigotes under high power objective or phase contrast illumination (**Figs 13A and B**). Other biphasic medium, like **Schneider's drosophila tissue culture medium** with added 30% fetal calf serum can also be used.

Animal inoculation: Animal inoculation is not used for routine diagnosis.

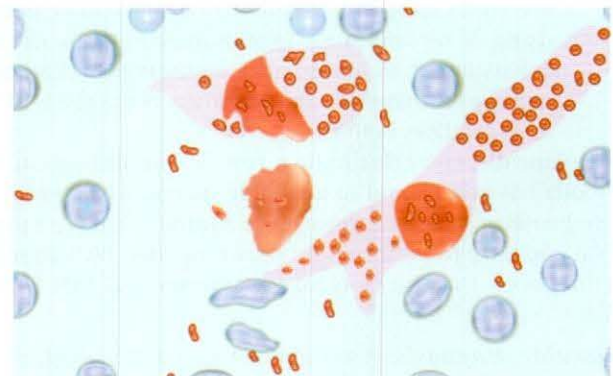


Fig. 14: Leishman-Donovan (LD) body in spleen smear of experimentally infected animal (Giemsa stain)

- When necessary, *Chinese golden hamster* is the animal employed.
- The material is inoculated intraperitoneally or intradermally into the skin of nose and feet.
- The inoculated animals are kept at $23\text{--}26^\circ\text{C}$.
- In positive cases, the amastigote can be demonstrated in smears taken from ulcers or nodules developing at the sites of inoculation or from the spleen (**Fig. 14**).
- Animal inoculation is a very sensitive method, but takes several weeks to become positive.

Indirect evidences:

Serodiagnosis:

- **Detection of antigen:** The concentration of antigen in the serum or other body fluids is very low. ELISA and PCR have been developed for detection of leishmanial antigen.

- Two noninvasive antigen detection test in urine for VL are under evaluation.
- **Detection of antibodies:**
 - *Complement fixation test* was the first serological test used to detect serum antibodies in VL. The antigen originally used, was prepared from human tubercle bacillus by Witebsky, Klingenstein and Kuhn (hence, called *WKK antigen*). CFT using WKK antigen becomes positive early in the disease, within weeks of infection. Positive reaction also occurs in other conditions, including tuberculosis, leprosy and tropical eosinophilia.
 - Specific leishmanial antigens prepared from cultures have been used in a number of tests to demonstrate specific antibodies. These tests include:
 - ♦ Indirect immunofluorescent antibody test (IFAT)
 - ♦ Counter immunoelectrophoresis (CIEP)
 - ♦ ELISA and DOT-ELISA
 - ♦ Direct agglutination test (DAT)
 - **rk 39 test:** A specific rapid immunochromatographic test (ICT) method for antibody has been developed using a recombinant leishmanial antigen *rk 39* consisting of 39 amino acids conserved in kinesin region of *L. infantum*. The sensitivity of the test is 98% and specificity is 90%.

Note: The direct agglutination test for antileishmanial antibody has been found to be highly specific and sensitive for diagnosis of kala-azar. However, rk 39 antibody test is more useful and easy to perform and recommended by National Vector Borne Disease Control Programme (NVBDCP) in India.

Molecular diagnosis: A number of molecular diagnosis methods have been developed, which help in species identification of *Leishmania*. The methods include Western blot and PCR. The use of PCR is confined to specialized laboratories and is yet to be used for routine diagnosis of VL in endemic areas.

Nonspecific serum tests: These tests are based on the greatly increased globulin content of serum in the disease.

- The two tests widely used are:
 1. *Napier's aldehyde or formogel test*
 2. *Chopra's antimony test*
- **Napier's aldehyde test:** 1 mL of clear serum from the patient is taken in a small test tube, a drop of formalin (40% formaldehyde) is added, shaken and kept in a rack at room temperature.
 - A control tube with normal serum is also set up.
 - A positive reaction is jellification and opacification of the test serum, resembling the coagulated white of egg appearing within 3–30 minutes.
 - About 85% of patients with disease of 4 months or more give positive reaction.

- Aldehyde test is always negative in cutaneous leishmaniasis (CL).
- The test merely indicates greatly increased serum gamma-globulin and thus, is nonspecific.
- **Chopra's antimony test:** It is done by taking 0.2 mL of serum diluted 1:10 with distilled water in a Dreyer's tube and overlaying with few drops of 4% solution of *urea stibamine*. Formation of flocculent precipitate indicates positive test.
 - The reaction is said to be more sensitive than the aldehyde test.
- Both the tests give false-positive reactions in several other disease such as multiple myeloma, cirrhosis of liver, tuberculosis, leprosy, schistosomiasis, African trypanosomiasis, etc. where hypergammaglobulinemia exists.

Skin test:

- **Leishmanin skin test (Montenegro test):**
 - It is delayed hypersensitivity test.
 - This was first discovered by Montenegro in South America and hence, named after him.
 - 0.1 mL of killed promastigote suspension (10^6 washed promastigotes/mL) is injected intradermally on the dorsoventral aspect of forearm.
 - Positive result is indicated by an induration and erythema of 5 mm or more after 48–72 hours.
 - Positive result indicates prior exposure to leishmanial parasite.
 - In active kala-azar, this test is negative and becomes positive usually 6–8 weeks after cure from the disease.

Blood picture:

- Complete blood count shows **normocytic normochromic anemia** and **thrombocytopenia**.
- Leukocyte count reveals *leukopenia* accompanied by a relative increase of lymphocytes and monocytes. Eosinophil granulocytes are absent. During the course of disease, there is a progressive diminution of leukocyte count falling to $1,000/\text{mm}^3$ of blood or even below that.
- The ratio of leukocyte to erythrocyte is greatly altered and may be about 1:200 to 1:100 (normal 1:750).
- Serum shows **hypergammaglobulinemia** and a reversal of the albumin: globulin ratio.
- Liver function tests show mild elevations of liver enzymes.
- Erythrocyte sedimentation rate is elevated.

Treatment: Kala-azar responds to treatment better than other forms of VL. The standard treatment consists of pentavalent antimonial compound, which is the drug of choice in most of the endemic regions of the world, but there is resistance to antimony in Bihar in India, where amphotericin-B-deoxycholate or miltefosine is preferred.

Pentavalent antimonial compound: Two pentavalent antimonial (Sb^V) preparations are available:

1. Sodium stibogluconate (100 mg of Sb^V /mL) (**SSG**)
2. Meglumine antimoniate (85 mg of Sb^V /mL).

Dosage: The daily dose is 20 mg/kg by rapid intravenous (IV) infusion or intramuscular (IM) injection for 20–30 days. Cure rates exceed 90% in most of the old world, except in Bihar (India) due to resistance (cure rate 36%).

Amphotericin-B:

- Amphotericin-B is currently used as a first-line drug in Bihar. In other parts of the world, it is used when initial antimonial treatment fails.
- **Dosage:** 0.75–1.0 mg/kg on alternate days for a total of 15 infusions.

Note: Fever with chills is almost seen in all patients, using amphotericin-B infusions.

- **Liposomal amphotericin-B (AmBisome):** It has been developed and used extensively to treat VL in all parts of the world. It is the only drug approved by the US Food and Drug Administration (FDA) for the treatment of VL; dose being 3 mg/kg daily. By using liposomal amphotericin-B, higher doses can be given, improving the cure, without toxicity (**Box 6**).
- Current recommendation in India is 10 mg/kg **single dose**.

Paromomycin: Paromomycin is an intramuscular aminoglycoside antibiotic with antileishmanial activity.

Dosage: It is given in a dose of 11 mg/kg daily for 21 days.

Miltefosine: Miltefosine is the first oral drug, approved for the treatment of leishmaniasis.

Dosage: 50 mg daily for 28 days for patients weighing less than 25 kg, and twice daily for patients weighing more than 25 kg.

Prophylaxis:

- Early detection and treatment of all cases.
- Integrated insecticidal spraying to reduce sandfly population.
- Destruction of animal reservoir host in cases of zoonotic kala-azar.

Box 6: Advantages of drug coadministrations in visceral leishmaniasis

- Increase activity by additive and synergistic effect.
- Reduce length of treatment, toxicity, drug-dose burden.
- Reduce resistant cases and improve patient compliance.
- Improve success in treating human immunodeficiency virus (HIV)-leishmaniasis coinfecting cases.
- Regime of coadministered drug include:
 - AmBisome + Paromomycin
 - AmBisome + Miltefosine
 - Paromomycin + Miltefosine

- Personal prophylaxis by using antisanfly measures like, using thick clothes, bed nets, window mesh, or insect repellants and keeping the environment clean.
- No vaccine is available at present against kala-azar.
- **Candidate vaccine:** Many 2nd generation subunit vaccines are under trial in rodent models, e.g. hydrophilic acetylated surface protein B1 (**HASB1**), kinetoplastid membrane protein II (**KMP11**) and **LeishIII**.

Leishmania Tropica Complex

- It includes three species:
 1. *Leishmania tropica*
 2. *Leishmania major*
 3. *Leishmania aethiops*.
- All these species cause **old world cutaneous leishmaniasis**. The disease is also known as **oriental sore**, **Delhi boil**, **Bagdad boil**, or **Aleppo button**.

History and distribution: Cunningham (1885) first observed the parasite in the tissues of a Delhi boil in Calcutta.

- Russian military surgeon, Borovsky (1891) gave an accurate description of its morphology and Luhe (1906) gave the name *L. tropica*.
- *L. tropica* and *L. major* are found in Middle-East, India, Afghanistan, Eastern Mediterranean countries and North Africa.
- *L. aethiops* occurs in Ethiopia and Kenya.
- In India, CL is restricted to the dry western half of the Indo-Gangetic plains including dry areas bordering Pakistan, extending from Amritsar to Kutch and Gujarat plains. To the East, the cases have been reported from Delhi and Varanasi in Uttar Pradesh.

Habitat: *L. tropica* causing CL (old world CL) are essentially the parasite of skin. The amastigote forms occur in the reticuloendothelial cells of the skin, whereas promastigote forms are seen in sandfly vector.

Morphology: Morphology of *L. tropica* complex is indistinguishable from that of *L. donovani*.

Life cycle: The life cycle of *L. tropica* is similar to that of *L. donovani* except:

Vectors: The vectors of *L. tropica* complex are *Phlebotomus* sandflies. The following species of sandflies act as vector:

- *P. sergenti*—*L. tropica*
- *P. papatasi*—*L. major*
- *P. longipes*—*L. aethiops*

Mode of transmission:

- The most common mode of infection is through bite of sandflies.
- Infection may also sometimes occur by direct contact.
- Infection may be transmitted from man-to-man or animal-to-man by direct inoculation of amastigotes.

- Infection may also occur by autoinoculation.
- The amastigotes are present in the skin, within large mononuclear cells, neutrophils, inside capillary endothelial cells, and also free in the tissues.
- They are ingested by sandflies feeding near the skin lesions.
- In the midgut of the sandfly, the amastigotes develop into promastigotes, which replicate profusely.
- These are in turn transmitted to the skin of persons bitten by sandflies in the skin, the promastigotes are phagocytosed by mononuclear cells, in which they become amastigotes and multiply.
- However, they remain confined to the skin, without being transported to the internal organs, as is the case in VL.

Incubation period: Incubation period varies from 2–8 months.

Pathology: Amastigote forms are found in histiocytes and endothelial cells. There is an inflammatory granulomatous reaction with infiltration of lymphocyte and plasma cells. Early lesions are papular, followed by ulceration necrosis. *Papule* and *ulcer* are the main pathological lesions. They heal over months to years, leaving scars.

Clinical features: *L. tropica* causes **old world cutaneous leishmaniasis**.

- Features of the disease vary with epidemiological pattern from region-to-region.
- Three distinct patterns of old world CL have been recognized.
- The **anthroponotic urban type** causing painless dry ulcerating lesions, leading to disfiguring scars, caused by the species *L. tropica*.
 - This is prevalent from the Middle East to North-Western India. The most important vector is *P. sergenti*.
 - It is seen mainly in children in endemic areas and is called as **oriental sore or Delhi boil**.
 - It begins as a **raised papule**, which grows into a nodule that ulcerates over some weeks.
 - Lesions may be single or multiple and vary in size from 0.5 to more than 3 cm. Lymphatic spread and lymph gland involvement may be palpable and may precede the appearance of the skin lesion.
 - The margins of the ulcer are raised and indurated.
 - The ulcer is usually painless unless secondary bacterial infection occurs.
 - There may be **satellite lesions**, especially in *L. major* and *L. tropica* infections.
 - The dry ulcers usually heal spontaneously in about an year.
- The **zoonotic rural type** causing **moist ulcers** which are inflamed, often multiple, caused by *L. major*.
 - The incubation period is usually less than 4 months.

- Lesions due to *L. major* heal more rapidly than *L. tropica*
- This is seen in the lowland zones of Asia, Middle East and Africa.
- Gerbils, rats and other rodents are the reservoirs.
- *P. papatasi* is the most important vector.

- **Diffuse cutaneous leishmaniasis:** The nonulcerative and often diffuse lesions caused by *L. aethiopica* and seen in the highlands of Ethiopia and Kenya are known as diffuse cutaneous leishmaniasis (DCL).

- *P. longipes* is the usual vector.
- It is a rare form of disease, where nodular lesions although restricted to skin are disseminated on the face and extremities from initial localized papule.
- It is characterized by low humoral as well as cell-mediated immunity.
- The lesions last for years or even for entire age.
- It is difficult to treat.

Leishmaniasis recidivans is a type of lesion seen in persons with a high degree of cell-mediated immunity to the parasite. The lesions are chronic with alternating periods of activity and healing, characterized by a central scar with peripheral activity. The lesions resemble those of lupus or tuberculoid leprosy. Parasites are very scanty in the lesions. Leishmanin test is strongly positive. Chemotherapy is not very useful. Better results follow local application of heat.

Laboratory diagnosis:

Microscopy:

- Smear is made from the material obtained from the indurated edge of nodule or sore and stained by Giemsa or Leishman stain.
- Amastigotes are found in large numbers inside the macrophages.
- Definitive diagnosis is made by demonstration of amastigote in the smear collected from the lesion.

Culture: Promastigote forms can be isolated by culture of the aspirate material in NNN medium.

Skin test: Leishmanin skin test is helpful. Positive leishmanin test in children under 10 years of age from endemic areas is highly suggestive of the disease. The skin test is negative in diffuse CL.

Serology: These are of limited value as the patient shows no detectable levels of circulating antibodies.

Treatment: The specific treatment of CL is same as VL.

- Antimony-resistant diffuse CL can be treated with pentamidine.
- Topical treatment consists of a paste of 10% charcoal in sulfuric acid or liquid nitrogen.

Prophylaxis:

- Control of sandfly population by insecticides and sanitation measures.
- Personal protection by use of protective clothing and use of insect repellants.
- Elimination of mammalian reservoir.

New World Leishmaniasis***L. Braziliensis* Complex and *L. Mexicana* Complex**

History and distribution: Lindenberg and Paranhos (1909) first described amastigotes in the ulcers of skin in a man in Brazil. Vianna (1911) named the species as *L. braziliensis*.

- *L. braziliensis* complex and *L. mexicana* complex cause new world leishmaniasis in Central and South America.

Habitat: These occur as intracellular parasite. The amastigote form is seen inside the macrophages of skin and mucous membrane of the nose and buccal cavity. The promastigote form occurs in vector species *Lutzomyia*.

Morphology: Morphology of amastigote and promastigote forms of both the parasites is same as that of the other two species of *Leishmania*.

Life cycle: The life cycle of *Leishmania* species causing the new world cutaneous and mucocutaneous leishmaniasis is similar to that of *L. donovani* except:

- Amastigotes are found in the reticuloendothelial cells and lymphoid tissues of skin, but not in the internal organs.
- The infection is transmitted to man from animals by bite of sandfly vectors of genus *Lutzomyia*.
- Sylvatic rodents and domestic animals are the common sources and reservoir of infection.
- Direct transmission and autoinfection also occurs man-to-man.

Clinical features: *L. mexicana* complex leads to cutaneous leishmaniasis which closely resembles the old world CL. However a specific lesion of caused by *L. mexicana* is *chiclero ulcer* which is characterized by ulcerations in pinna.

- **Chiclero ulcer** is also called as *self healing sore of Mexico*.
- *L. braziliensis* complex causes both **mucocutaneous leishmaniasis (espundia)** and "CL".
- *L. braziliensis* causes the most severe and destructive form of cutaneous lesion.
- It involves the nose, mouth and larynx.
- The patient experiences a nodule at the site of sandfly bite with symptoms consistent with oriental sore.
- Subsequent mucocutaneous involvement leads to nodules inside the nose, perforation of the nasal septum, and enlargement of the nose and lips (**espundia**).

- If the larynx is involved, the voice changes as well.
- Ulcerated lesions may lead to scarring and tissue destruction that can be disfiguring.
- The disease occurs predominantly in Bolivia, Brazil and Peru.
- *L. mexicana*, *L. amazonensis* also cause **DCL** similar to that of *L. aethiopica* in individuals with defective cell-mediated immunity. Montenegro skin test is negative.

Pian bois: It is also known as "forest yaws".

- It is caused by *L. braziliensis guyanensis* and is characterized by appearance of single or multiple painless dry persistent ulcers appear all.

Laboratory diagnosis:

Microscopy: Amastigotes are demonstrated in smears taken from lesions of skin and mucous membrane. *L. mexicana* amastigotes are larger than those of *L. braziliensis* and their kinetoplast is more centrally placed.

Biopsy: Amastigotes can also be demonstrated from slit-skin biopsy.

Culture: Culturing material obtained from ulcers in NNN medium demonstrates promastigotes. *L. mexicana* grows well in comparison to *L. braziliensis*, which grows slowly.

Serology: Antibodies can be detected in serum by IFA test, which is positive in 89–95% of cases. ELISA is also a sensitive method to detect antibody; being positive in 85% of cases.

Skin test: Leishmanin test is positive in cutaneous and mucocutaneous leishmaniasis.

Treatment: Treatment with a pentavalent antimonial compound is moderately effective for mild mucocutaneous leishmaniasis.

- Amphotericin-B is the best alternative drug currently available.
- In case of respiratory complications, glucocorticoids can be used.

Prophylaxis:

- Due to sylvatic and rural nature of the disease, control is often difficult.
- Use of insect repellants, spraying of insecticides and screening are advisable.
- Forest workers should use protective clothing and other protective measures.
- A recently developed polyvalent vaccine using five *Leishmania* strains has been reported to be successful in reducing the incidence of CL in Brazil.

KEY POINTS OF *LEISHMANIA*

- Visceral leishmaniasis (kala-azar) is caused by *L. donovani* and *L. infantum*.
- Vector of kala-azar is sandfly (*argentipes*).
- Amastigote forms (LD body) are found in macrophages and monocytes in human.
- Promastigote forms with a single flagellum is found in vector sandfly and artificial culture.
- **Clinical features: Kala-azar:** Fever, hepatosplenomegaly, marked anemia, darkly pigmented skin, weight loss, cachexia, etc.
- **Post-kala-azar dermal leishmaniasis:** Seen after 1–2 years of treatment in 3–10% cases and is a nonulcerative lesion of skin.
- **Diagnosis:** By demonstrations of LD bodies in peripheral blood, bone marrow aspirate, splenic aspirate and lymph node aspirate; culture done in NNN medium; aldehyde test; detection of specific antigen and antibody by IIF, ELISA, DAT and rapid rk 39 antibody detection test.
- **Blood picture:** Anemia, thrombocytopenia, leukopenia with relative lymphocytosis and hypergammaglobulinemia.
- **Treatment:** Sodium stibogluconate, amphotericin-B and oral miltefosine.
- Old world CL (oriental sore) is caused by *L. tropica* and the vectors are *P. sergenti* and *P. papatasi*.
- New world mucocutaneous (espundia) and CL are caused by *L. braziliensis* and *L. mexicana*. Vector is sandfly of genus *Lutzomyia*.

REVIEW QUESTIONS

1. Describe briefly the life cycle and laboratory diagnosis of:
 - a. *Trypanosoma brucei gambiense*
 - b. *Trypanosoma cruzi*
 - c. *Leishmania donovani*
2. Write short notes on:
 - a. Sleeping sickness
 - b. Chagas disease
 - c. Antigenic variations of *Trypanosoma brucei gambiense*
 - d. Morphological stages of hemoflagellates
 - e. *Trypanosoma rangeli*
 - f. Kala-azar
 - g. Post-kala-azar dermal leishmaniasis
 - h. Cutaneous leishmaniasis
 - i. Diffuse cutaneous leishmaniasis
3. Differentiate between:
 - a. East African trypanosomiasis and West African trypanosomiasis
 - b. *Trypanosoma cruzi* and *Trypanosoma rangeli*

MULTIPLE CHOICE QUESTIONS

1. Vector for *Trypanosoma cruzi* is
 - a. Reduviid bug
 - b. Tsetse fly
 - c. Sandfly
 - d. Hard tick
2. All of the following are obligate intracellular parasite except
 - a. *Plasmodium*
 - b. *Trypanosoma cruzi*
 - c. *Toxoplasma gondii*
 - d. *Trypanosoma brucei gambiense*
3. Romana's sign occurs in
 - a. Babesiosis
 - b. Leishmaniasis
 - c. Trypanosomiasis
 - d. Schistosomiasis
4. Vector for *T. brucei gambiense* is
 - a. Sandfly
 - b. Reduviid bug
 - c. Tsetse fly
 - d. House fly
5. Winterbottom sign in sleeping sickness refers to
 - a. Unilateral conjunctivitis
 - b. Posterior cervical lymphadenitis
 - c. Narcolepsy
 - d. Transient erythema
6. The drug that can clear trypanosomes from blood and lymph nodes and is active in late nervous system stages of African sleeping sickness is
 - a. Emetine
 - b. Melarsoprol
 - c. Nifurtimox
 - d. Suramin
7. Which of the following is not true about West African trypanosomiasis
 - a. Primary reservoirs are human
 - b. Low parasitemia
 - c. Illness is usually chronic
 - d. Minimal lymphadenopathy
8. Chronic infections with which of the following hemoflagellates may be associated with megaesophagus or megacolon
 - a. *Trypanosoma gambiense*
 - b. *Trypanosoma cruzi*
 - c. *Leishmania donovani*
 - d. *Leishmania tropica*
9. True about visceral leishmaniasis is/are
 - a. Caused by *Leishmania tropica*
 - b. Post leishmaniasis dermatitis develops in 20% of patients

- c. Antimonial compounds are useful
d. Vector is tsetse fly
- 10. Which of the following is most severely affected in kala-azar**
- Spleen
 - Liver
 - Lymph nodes
 - Bone marrow
- 11. LD bodies are**
- Amastigotes of *Leishmania donovani* inside RBCs
 - Giant cells seen in leishmaniasis
 - Degenerative lesions seen in leishmaniasis
 - Amastigotes of *Leishmania donovani* inside macrophages
- 12. In a case of kala-azar, aldehyde test becomes positive after**
- 2 weeks
 - 4 weeks
 - 8 weeks
 - 12 weeks

- 13. Mucocutaneous leishmaniasis is caused by**
- Leishmania braziliensis*
 - Leishmania donovani*
 - Leishmania tropica*
 - None of the above
- 14. Chiclero's ulcer is caused by**
- Leishmania mexicana complex*
 - Leishmania braziliensis complex*
 - Leishmania tropica*
 - Leishmania infantum*

Answer

- | | | | | | | |
|------|------|-------|-------|-------|-------|-------|
| 1. a | 2. d | 3. c | 4. c | 5. b | 6. b | 7. d |
| 8. b | 9. c | 10. a | 11. d | 12. d | 13. a | 14. a |

Malaria and Babesia

MALARIA

INTRODUCTION

Protozoan parasites characterized by the production of spore-like oocysts containing sporozoites were known as sporozoa.

- They live *intracellularly*, at least during part of their life cycle.
- At some stages in their life cycle, they possess a structure called the *apical complex*, by means of which they attach to and penetrate host cells.
- These protozoa are therefore grouped under the *Phylum Apicomplexa*.
- The medically important parasites in this group are the *malaria parasites*, *Coccidia*, and *Babesia*.
- The *Phylum Apicomplexa* includes two classes viz. (1) hematozoa and (2) coccidia and three orders— (1) eimeriida, (2) hemosporida and (3) piroplasmida (**Table 1**).

Note: Many minute intracellular protozoa formerly grouped as sporozoa have been reclassified because of some structural differences. These are now called *microspora*. They infect a large spectrum of hosts including vertebrates and invertebrates. Infection is mostly asymptomatic, but clinical illness is often seen in the immunodeficient.

Table 1: Phylum Apicomplexa (Sporozoa)

Class	Order	Genera
Hematozoa	Hemosporida	• <i>Plasmodium</i>
	Piroplasmida	• <i>Babesia</i>
Coccidia	Eimeriida	• <i>Toxoplasma</i>
		• <i>Cyclospora</i>
		• <i>Cryptosporidium</i>
		• <i>Isospora</i>
		• <i>Sarcocystis</i>

CLASSIFICATION

Malaria parasite belongs to:

- Phylum:** Apicomplexa
- Class:** Sporozoa
- Order:** Hemosporida
- Genus:** *Plasmodium*.

- The genus *Plasmodium* is classified into two subgenera: (1) *P. vivax*, (2) *P. malariae* and *P. ovale* belong to the subgenus **Plasmodium** while *P. falciparum* belongs to subgenus **Laverania** because it differs in a number of aspects from the other three species.
- *P. vivax*, *P. malariae* and *P. ovale* are closely related to other primate malaria parasites. *P. falciparum* is more related to bird malaria parasites and appears to be a recent parasite of humans, in evolutionary terms. Perhaps for this reason, *falciparum* infection causes the most severe form of malaria and is responsible for nearly all fatal cases.
- *P. knowlesi*, a parasite of long-tailed Macaque monkeys may also affect man.

CAUSATIVE AGENTS OF HUMAN MALARIA

- *Plasmodium vivax*: Benign tertian malaria
- *Plasmodium falciparum*: Malignant tertian malaria
- *Plasmodium malariae*: Benign quartan malaria
- *Plasmodium ovale*: Benign tertian malaria.

MALARIA PARASITE

History and Distribution

Malaria has been known from ancient times. Seasonal intermittent fevers with chills and shivering, recorded in the religious and medical texts of ancient Indian, Chinese and Assyrian civilizations, are believed to have been malaria (**Fig. 1**).

- The name malaria (*mal: bad, aria: air*) was given in the 18th century in Italy, as it was thought to be caused by foul emissions from marshy soil.
- The specific agent of malaria was discovered in red blood cells (RBCs) of a patient in 1880 by **Alphonse Laveran**, a French army surgeon in Algeria.
- In 1886, **Golgi** in Italy described the asexual development of the parasite in RBCs (*erythrocytic schizogony*), which therefore came to be called as *Golgi cycle*.
- Three different species of malaria parasite infecting man: (1) *P. vivax*, (2) *P. malariae*, and (3) *P. falciparum* were described in Italy between 1886 and 1890. The fourth species, *P. ovale* was identified only in 1922.
- The mode of transmission of the disease was established in 1897, when **Ronald Ross** in Secunderabad, India identified the developing stages of malaria parasites in mosquitoes. This led to various measures for the control and possible eradication of malaria by mosquito control. Both Ross (1902) and Laveran (1907) won the Nobel Prize for their discoveries in malaria.
- Incidence of malaria is more in poor population in rural areas, also in urban areas having bad sanitary condition. An epidemic can develop when there are changes in environmental, economic and social conditions such as migrations and heavy rains following draughts.
- The relative prevalence of the four species of malaria parasites varies in different geographical regions (**Fig. 1**):
 1. *P. vivax* is the most widely distributed, being most common in Asia, North Africa, and Central and South America.
 2. *P. falciparum*, the predominant species in Africa, Papua New Guinea and Haiti, is rapidly spreading in Southeast Asia and India.
 3. *P. malariae* is present in most places but is rare, except in Africa.
 4. *P. ovale* is virtually confined to West Africa where it ranks second after *P. falciparum* (**Fig. 1**).
- Malaria may occur in endemic as well as epidemic patterns. It is described as *endemic*, when it occurs constantly in an area over a period of several successive years and as *epidemic*, when periodic or occasional sharp rises occur in its incidence.

The World Health Organization (WHO) has recommended the classification of endemicity depending on the spleen or parasite rate in a statistically significant sample in the populations of children (2–9 years) and adults. According to this:

 - **Hypoendemic** (*transmission is low*): Spleen or parasite rate less than 10%
 - **Mesoendemic** (*transmission is moderate*): Spleen or parasite rate 11–50%
 - **Hyperendemic** (*transmission is intense but seasonal*): Spleen or parasite rate 51–75%
 - **Holoendemic** (*transmission of high intensity*): Spleen or parasite rate more than 75%.
- In India, malaria is a major public health threat. In India, about **27% population** lives in high transmission (>1 case/1,000 population) and about 58% in low transmission (0–1 case)/1,000 population) area.
- In spite of decline of total number of malaria cases, the number of cases of *P. falciparum* malaria has increased.

Vectors

Human malaria is transmitted by over 60 species of female *Anopheles mosquito*.

- The male mosquito feeds exclusively on fruits and juices, but the female needs at least two blood meals, before the first batch of eggs can be laid.
- Out of 45 species of *Anopheles* mosquito in India, only few are regarded as the vectors of malaria. These are *An. culicifacies*, *An. fluviatilis*, *An. stephensi*, *An. minimus*, *An. philippinensis*, *An. sundaicus*, etc.

Life Cycle

Malaria parasite passes its life cycle in two hosts:

1. **Definitive host:** Female *Anopheles* mosquito.
 2. **Intermediate host:** Man.
- The life cycle of malarial parasite comprises of two stages—(1) **an asexual phase** occurring in humans, which act as the intermediate host and (2) **a sexual phase** occurring in mosquito, which serves as a definitive host for the parasite (**Fig. 2**).

Asexual Phase

- In this stage, the malaria parasite multiplies by division or splitting a process designated to as *schizogony* (from *schizo: to split*, and *gone: generation*).

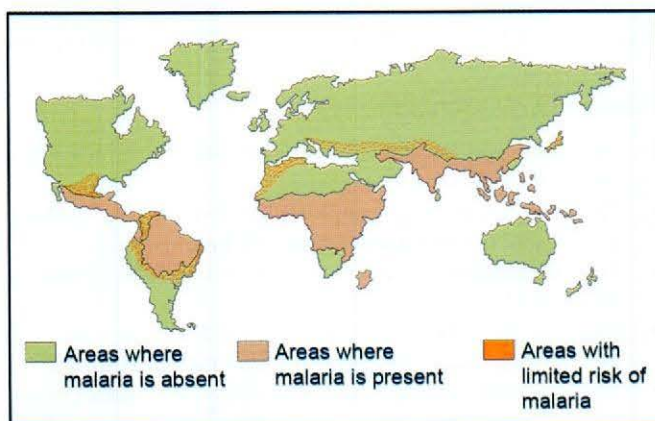


Fig. 1: Global distribution of malaria

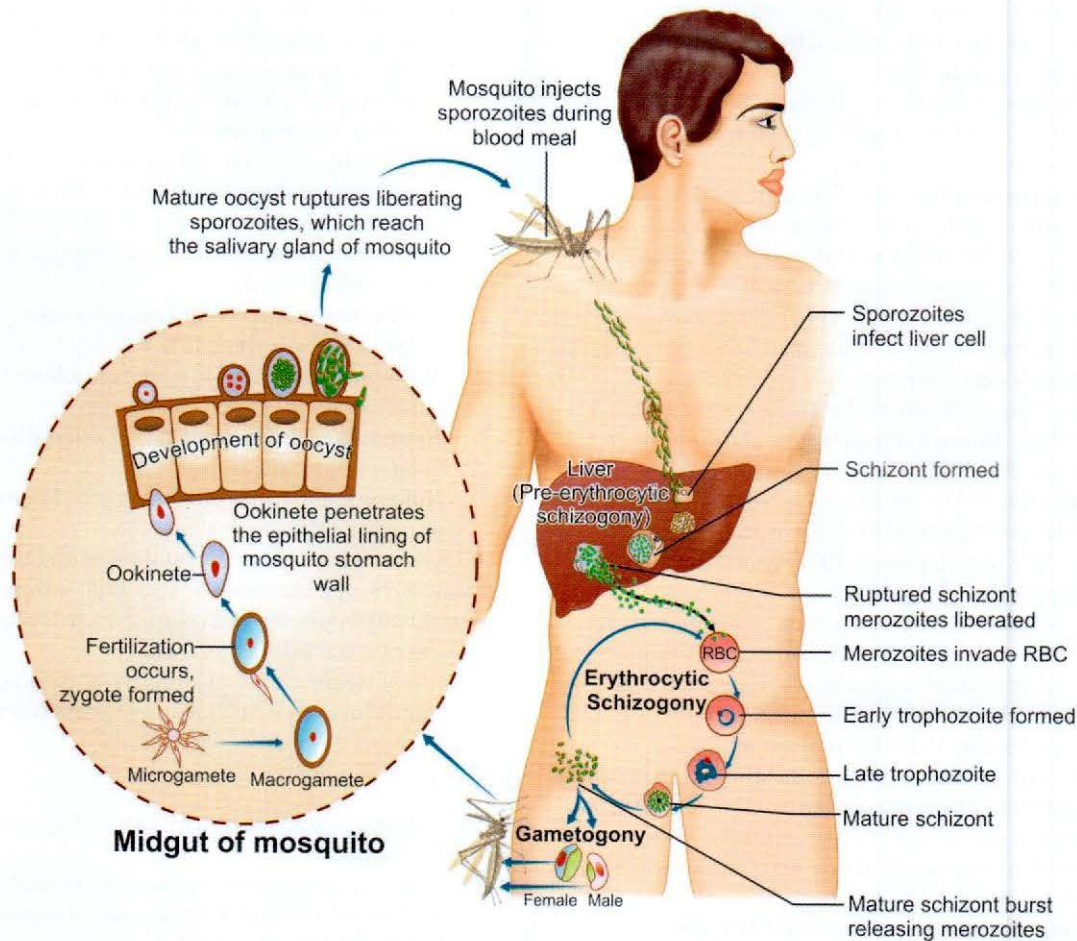


Fig. 2: Life cycle of the *Plasmodium vivax*
Abbreviation: RBC, red blood cell

- Because this asexual phase occurs in man, it is also called the *vertebrate, intrinsic, or endogenous phase*.
- In humans, schizogony occurs in two locations—(1) in the red blood cell (*erythrocytic schizogony*) and (2) in the liver cells (*exoerythrocytic schizogony* or the tissue phase).
- Because schizogony in the liver is an essential step before the parasites can invade erythrocytes, it is called *pre-erythrocytic schizogony*.
- The products of schizogony, whether erythrocytic or exoerythrocytic, are called **merozoites** (*meros: a part, zoon: animal*).

Sexual Phase

- Female *Anopheles* mosquito represents definitive host, in which sexual forms take place. Although the sexual forms of the parasite (**gametocytes**) originate in human RBCs.
- Maturation and fertilization take place in the mosquito, giving rise to a large number of **sporozoites** (from *sporos:*

seed). Hence, this phase of sexual multiplication is called **sporogony**. It is also called the invertebrate, extrinsic, or exogenous phase.

Thus, there is an alternation of hosts as the asexual phase takes place in humans followed by sexual phase in mosquito.

Human Cycle (Schizogony)

Human infection comes through the bite of the infective female *Anopheles* mosquito (**Fig. 2**).

- The sporozoites, which are infective forms of the parasite are present in the **salivary gland** of the mosquito.
- They are injected into blood capillaries when the mosquito feeds on blood after piercing the skin.
- Usually, 10–15 sporozoites are injected at a time, but occasionally, many hundreds may be introduced.
- The sporozoites pass into the bloodstream, where many are destroyed by the phagocytes, but some reach the liver and enter the parenchymal cells (hepatocytes).

Pre-erythrocytic (tissue) stage or exoerythrocytic stage: Within an hour of being injected into the body by the mosquito, the sporozoites reach the liver and enter the hepatocytes to initiate the stage of pre-erythrocytic schizogony or merogony.

- The sporozoites, which are elongated spindle-shaped bodies, become rounded inside the liver cells.
- They enlarge in size and undergo repeated nuclear division to form several daughter nuclei; each of which is surrounded by cytoplasm.
- This stage of the parasite is called the *pre-erythrocytic* or *exoerythrocytic schizont* or **meront**.
- The hepatocyte is distended by the enlarging schizont and the liver cell nucleus is pushed to the periphery.
- Mature liver stage schizonts are spherical (45–60 μm), multinucleate and contain 2,000–50,000 **uninucleate merozoites**.
- Unlike erythrocytic schizogony, there is no pigment in liver schizonts. These normally rupture in 6–15 days and release thousands of merozoites into the bloodstream.
- *The merozoites infect the erythrocytes by a process of invagination.*
- **Prepatent period:** The interval between the entry of the sporozoites into the body and the first appearance of the parasites in blood is called the prepatent period.
- The duration of the pre-erythrocytic phase in the liver, the size of the mature schizont and the number of merozoites produced vary with the species of the parasite (**Table 2**).
- **Latent stage:** In *P. vivax* and *P. ovale*, two kinds of sporozoites are seen, some of which multiply inside hepatic cells to form schizonts and others persist and remain dormant (resting phase).
- **Relapse:** The resting forms are called **hypnozoites** (*hypnos: sleep*). From time to time, some are activated to become schizonts and release merozoites, which go on infecting RBCs producing clinical relapse.
- **Recrudescence:** In *P. falciparum* and *P. malariae*, initial tissue phase disappears completely, and no hypnozoites are found. However, small numbers of erythrocytic parasites persist in the bloodstream and in due course of time, they multiply to reach significant numbers resulting in clinical disease (*short-term relapse or recrudescence*).

Erythrocytic stage: The merozoites released by pre-erythrocytic schizonts invade the RBCs.

- The receptor for merozoites is **glycophorin**, which is a major glycoprotein on the red cells. The differences in the glycophorins of red cells of different species may account for the species specificity of malaria parasites.
- Merozoites are *pear-shaped* bodies, about 1.5 μm in length, possessing an **apical complex** (*rhoptery*). They attach to the erythrocytes by their apex and then the merozoites lie within an intraerythrocytic parasitophorous vacuole formed by red cell membrane by a process of invagination.

- In the erythrocyte, the merozoite loses its internal organelles and appears as a rounded body having a vacuole in the center with the cytoplasm pushed to the periphery and the nucleus at one pole. These young parasites are, therefore called the **ring forms** or *young trophozoites*.
- The parasite feeds on the hemoglobin of the erythrocyte. It does not metabolize hemoglobin completely and therefore, leaves behind a hemo-globin pigment called the **malaria pigment** or **hemozoin pigment**, as residue (**Box 1**).
- The malaria pigment released when the parasitized cells rupture is taken up by reticuloendothelial cells. Such pigment-laden cells in the internal organs provide histological evidence of previous malaria infection.
- As the ring form develops, it enlarges in size becoming irregular in shape and shows **ameboid motility**. This is called the **ameboid form** or late **trophozoite form**.
- When the ameboid form reaches a certain stage of development, its nucleus starts dividing by mitosis followed by a division of cytoplasm to become mature **schizonts or meronts**.
- A mature schizont contains 8–32 merozoites and hemozoin. The mature schizont bursts releasing the merozoites into the circulation.
- The merozoites invade fresh erythrocytes within which they go through the same process of development. This cycle of **erythrocytic schizogony** or **merogony** is repeated sequentially, leading to progressive increase in the parasitemia, till it is arrested by the development of host immune response.

Table 2: Features of pre-erythrocytic schizogony in human malaria parasites

	<i>P. vivax</i>	<i>P. falciparum</i>	<i>P. malariae</i>	<i>P. ovale</i>
Pre-erythrocytic stage (days)	8	6	15	9
Diameter of pre-erythrocytic schizont (μm)	45	60	55	60
No. of merozoites in pre-erythrocytic schizont	10,000	30,000	15,000	15,000

Box 1: Appearance of malaria pigments in different species

- *P. vivax*: Numerous fine golden-brown dust-like particles
- *P. falciparum*: Few 1–3 solid blocks of black pigment
- *P. malariae*: Numerous coarse dark-brown particles
- *P. ovale*: Numerous blackish-brown particles.

- The rupture of the mature schizont releases large quantities of pyrogens. This is responsible for the febrile paroxysms characterizing malaria.
- The interval between the entry of sporozoites into the host and the earliest manifestation of clinical illness is the **incubation period (Box 4)**. This is different from *prepatent period*, which is the time taken from entry of the sporozoites to the first appearance of malaria parasite in peripheral blood.
- In *P. falciparum*, erythrocytic schizogony always takes place inside the capillaries and vascular beds of internal organs. Therefore, in *P. falciparum* infections, schizonts and merozoites are usually not seen in the peripheral blood.
- The erythrocytic stages of all the four species of *Plasmodium* are shown in **Figure 3**.

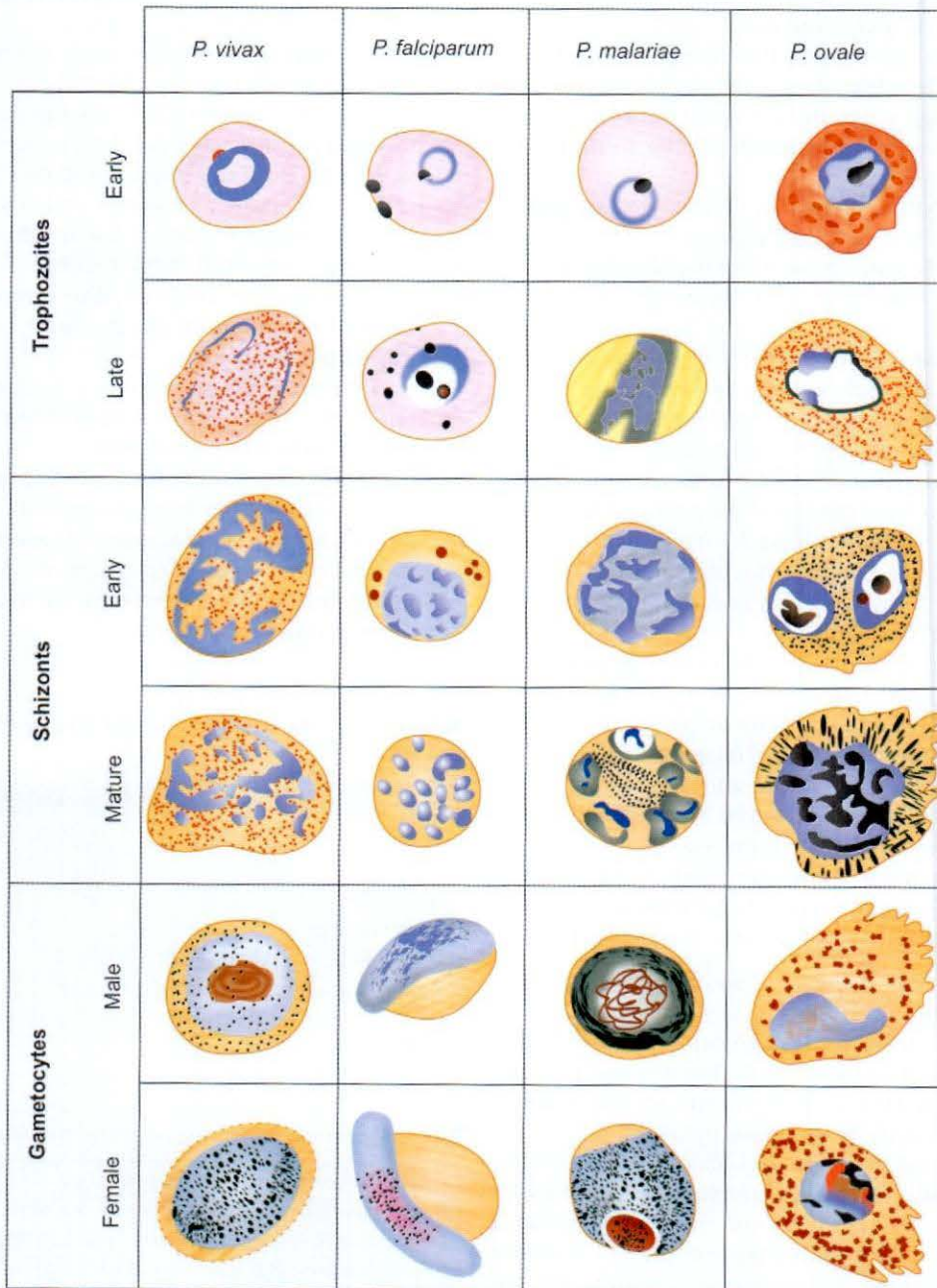


Fig. 3: Malaria parasites—Erythrocytic stages of the four species (Giemsa stain. Magnification 2000X)

Gametogony

After a few erythrocytic cycles, some of the merozoites that infect RBCs do not proceed to become trophozoites or schizonts but instead, develop into sexually differentiated forms, the **gametocytes**.

- They grow in size till they almost fill the RBC, but the nucleus remains undivided.
- Development of gametocytes generally takes place within the internal organs and only the mature forms appear in circulation.
- The mature gametocytes are **round** in shape, except in *P. falciparum*, in which they are **crescent-shaped**.
- In all species, the female gametocyte is larger (**macrogametocyte**) and has cytoplasm staining dark blue with a compact nucleus staining deep red. In the smaller male gametocyte (**microgametocyte**), the cytoplasm stains pale blue or pink and the nucleus is larger, pale stained and diffuse. Pigment granules are prominent.
- Female gametocytes are generally more numerous than the male.
- Gametocyte appears in circulation **4–5 days** after the first appearance of asexual form in case of *P. vivax* and **10–12 days** in *P. falciparum*.
- A person with gametocytes in blood is a **carrier** or reservoir.
- The gametocytes do not cause any clinical illness in the host, but are essential for transmission of the infection.
- A gametocyte concentration of 12 or more per mm³ of blood in the human host is necessary for mosquitoes to become infected.

The Mosquito Cycle (Sporogony)

When a female *Anopheles* mosquito ingests parasitized erythrocytes along with its blood meal, the asexual forms of malaria parasite are digested, but the gametocytes are set free in the midgut (stomach) of mosquito and undergo further development.

- The nuclear material and cytoplasm of the male gametocytes divides to produce eight microgametes with long, actively motile, whip-like filaments (**exflagellating male gametocytes**) (Fig. 4).
- At 25°C, the exflagellation is complete in 15 minutes for *P. vivax* and *P. ovale* and 15–30 minutes for *P. falciparum*.
- The female gametocyte does not divide but undergoes a process of maturation to become the female gamete or macrogamete. It is fertilized by one of the microgametes to produce the **zygote** (Fig. 4).
- Fertilization occurs in 0.5–2 hours after the blood meal. The zygote, which is initially a motionless round body, gradually elongates and within 18–24 hours, becomes a **vermicular motile** form with an apical complex anteriorly. This is called the **ookinete (travelling vermicule)**.

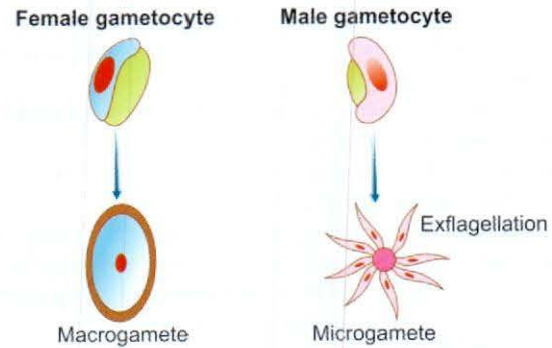


Fig. 4: Schematic diagram showing formation of microgamete and macrogamete

- It penetrates the epithelial lining of the mosquito stomach wall and comes to lie just beneath the basement membrane.
- It becomes rounded into a sphere with an elastic membrane. This stage is called the **oocyst**, which is yet another multiplicative phase, within which numerous **sporozoites** are formed.
- The mature oocyst, which may be about 500 µm in size, bulges into body cavity of mosquito and when it ruptures, the sporozoites enter into the hemocele or body cavity, from where some sporozoites move to the salivary glands.
- The mosquito is now infective and when it feeds on humans, the sporozoites are injected into skin capillaries to initiate human infection.
- **Extrinsic incubation period:** The time taken for completion of sporogony in the mosquito is about **1–4 weeks** (extrinsic incubation period), depending on the environmental temperature and the species.

Types of Malarial Parasites

Plasmodium Vivax

P. vivax has the widest geographical distribution, extending through the tropics, subtropics and temperate regions. It is believed to account for 80% of all malaria infections. It is the **most common species** of malaria parasite in Asia and America, but is much less common in Africa. It causes **benign tertian malaria** with frequent relapses.

- The sporozoites of *P. vivax* are narrow and slightly curved. On entering the liver cells, the sporozoites initiate two types of infection. Some develop promptly into **exoerythrocytic schizonts**, while others persist in the dormant state for varying periods as **hypnozoites**. There may be two distinct types of sporozoites: (1) the **tachysporozoites** (*tachy*: fast), which develops into the primary exoerythrocytic schizont and (2) the **bradysporozoite** (*brady*: slow) which becomes the hypnozoite.

- The pre-erythrocytic schizogony lasts for 8 days and the average number of merozoites per tissue schizont is 10,000.
- Merozoites of *P. vivax* preferentially infect **reticulocytes and young erythrocytes**.
- All stages of erythrocytic schizogony can be seen in peripheral smears (**Fig. 5**).
- The degree of parasitization is not generally heavy, each infected red cell usually having only one trophozoite and not more than **2-5% of the red cells** being affected. Reticulocytes are preferentially infected.
- The trophozoite is actively motile, as indicated by its name *vivax*. The ring form is well-defined, with a prominent central vacuole. One side of the ring is thicker and the other side thin. Nucleus is situated on the thin side of the ring (Signet ring appearance). The ring is about 2.5-3 μm in diameter, about a **third** of the size of an erythrocyte. The cytoplasm is blue and the nucleus red in stained films. The ring develops rapidly to the ameboid form and accumulates malarial pigment (**Figs 6 and 7**).
- The infected erythrocytes are enlarged and show red granules known as **Schuffner's dots** on the surface. They become irregular in shape, lose their red color and present a washed out appearance. A few of the parasitized erythrocytes retreat into the blood spaces of the internal organs.
- The schizont appears in about 36-40 hours. It occupies virtually the whole of the enlarged red cell. The schizont matures in the next 6-8 hours, with the development of merozoites, each with its central nucleus and surrounding cytoplasm. The pigment granules agglomerate into a few dark brown collections at the center, and with the merozoites around it, this stage presents a **rosette** appearance. There are about 12-24 (usually 16) merozoites per schizont.
- Erythrocytic schizogony takes approximately 48 hours. The red cell, which now measures about 10 μm in diameter is heavily stippled and often distorted. It bursts to liberate the merozoites and pigment. The pigment is phagocytosed by reticuloendothelial cells.

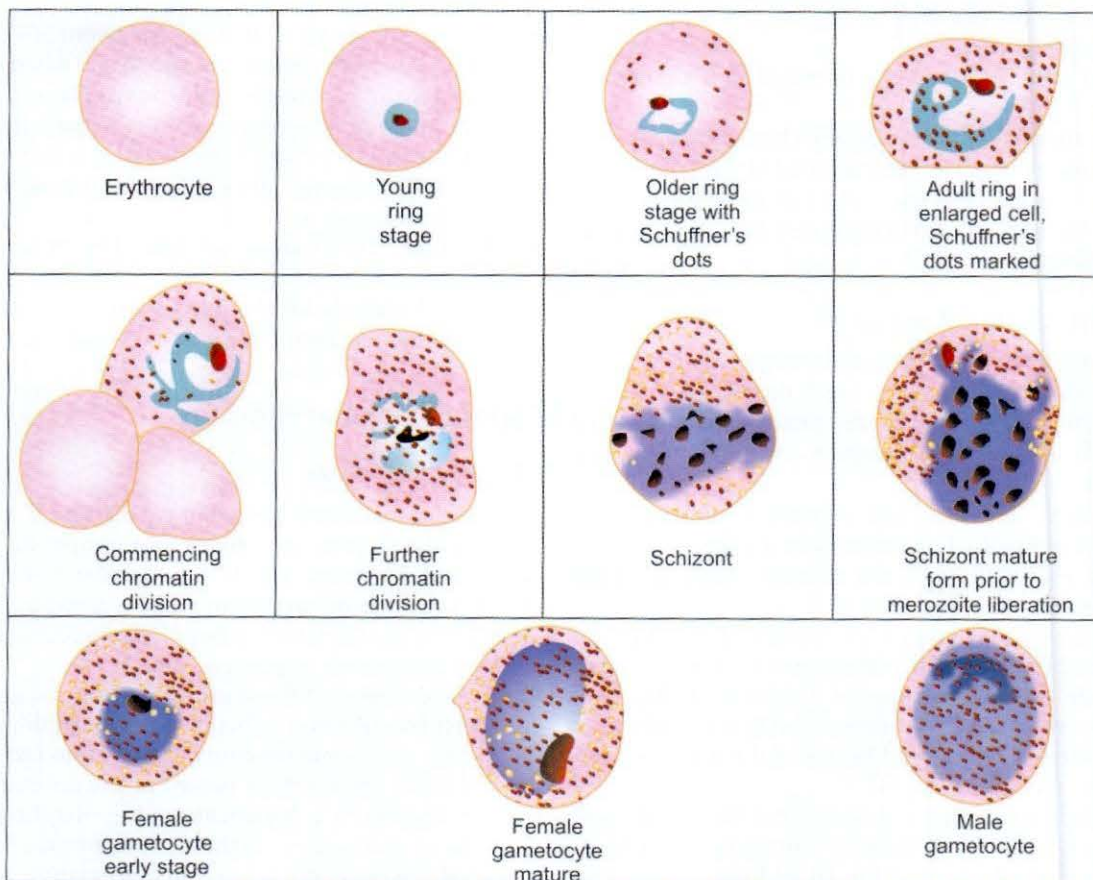


Fig. 5: *Plasmodium vivax* (Giemsa stain, magnification 2000X)

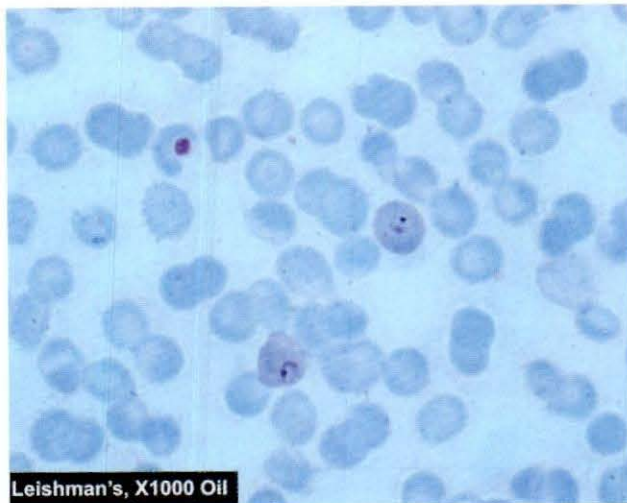


Fig. 6: Malarial parasite in blood film—Ring stage of *P. vivax*
Source: Mohan H. Textbook of Pathology, 6th edition. New Delhi: Jaypee Brothers Medical Publishers; 2010. p. 189.

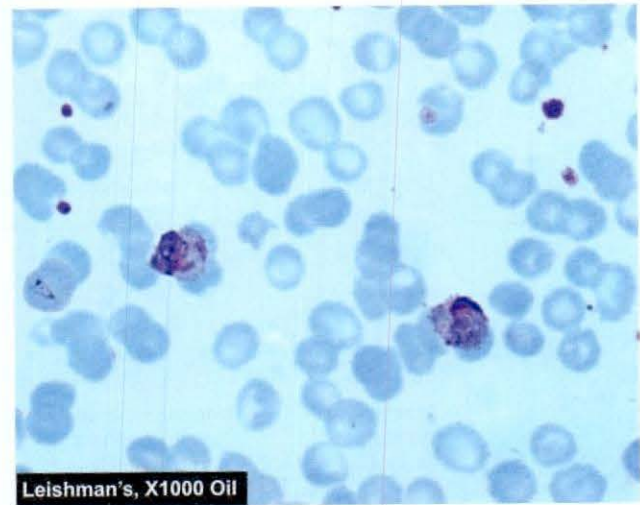


Fig. 7: Malarial parasite in blood film—Ameboid form of *P. vivax*
Source: Mohan H. Textbook of Pathology, 6th edition. New Delhi: Jaypee Brothers Medical Publishers; 2010. p. 189.

- The merozoites measure about 1.5 μm and have no pigment.
- Gametocytes appear early, usually within **4 days** after the trophozoites first appear. Both male and female gametocytes are large, nearly filling the enlarged red cell. The **macrogametocyte** has dense cytoplasm staining deep blue and a small compact nucleus. The **microgametocyte** has pale-staining cytoplasm and a large diffuse nucleus. Pigment granules are prominent in the gametocytes.

Plasmodium Falciparum

The name *falciparum* comes from the characteristic sickle shape of the gametocytes of this species (*falx: sickle, parere: to bring forth*). This is the highly pathogenic of all the plasmodia and hence, the name malignant tertian or pernicious malaria for its infection.

- The disease has a high rate of complications and unless treated, is often fatal. The species is responsible for almost all deaths caused by malaria.
- **Schizogony:** The sporozoites are sickle-shaped. The tissue phase consists of only a single cycle of pre-erythrocytic schizogony. **No hypnozoites occur.** The mature liver schizont releases about 30,000 merozoites.
- They attack **both young and mature erythrocytes** and so the population of cells affected is very large. Infected erythrocytes present a brassy coloration.
- **Ring form:** The early ring form in the erythrocyte is very **delicate** and tiny, measuring only a **one-sixth of the red cell diameter**. Rings are often seen attached along the margin of the red cell, the so-called **form appliqué** or **accolé**. Binucleate rings (**double chromatin**) are common resembling **stereo headphones** in appearance. Several rings may be seen within a single erythrocyte. In course of time, the rings become larger, about a third of the size of the red cell and may have 1 or 2 grains of pigment in its cytoplasm (**Figs 8 and 9**).
- The subsequent stages of the asexual cycle—late trophozoite, early and mature schizonts—are not ordinarily seen in peripheral blood, except in very severe or pernicious malaria. The presence of *P. falciparum* schizonts in peripheral smears indicates a grave prognosis (**Box 2**).
- The mature schizont is smaller than in any other species and has 8–24 (usually 16) merozoites. The erythrocytic schizogony takes about 48 hours or less, so that the periodicity of febrile paroxysms is 36–48 hours.
- Very high intensity of parasitization is seen in *falciparum* malaria. In very severe infections, the rate of parasitized cells may even be up to **50%**.
- The infected erythrocytes are of normal size. They show a few (6–12) coarse brick-red dots which are called **Maurer's clefts**. Some red cells show **basophilic stippling**.
- **Gametogony:** It begins after several generations of schizogony. Gametocytes are seen in circulation about 10 days after the ring stage first appears. The early gametocytes seldom appear in peripheral circulation. The mature gametocytes, which are seen in peripheral smears are curved oblong structures, described as **crescentic, sickle, sausage, or banana-shaped**. They are usually referred to as **crescents (Fig. 10)**.
- The male gametocytes are broad and sausage-shaped or **kidney-shaped**, with blunt rounded ends as compared to the female gametocytes, which are thinner and more

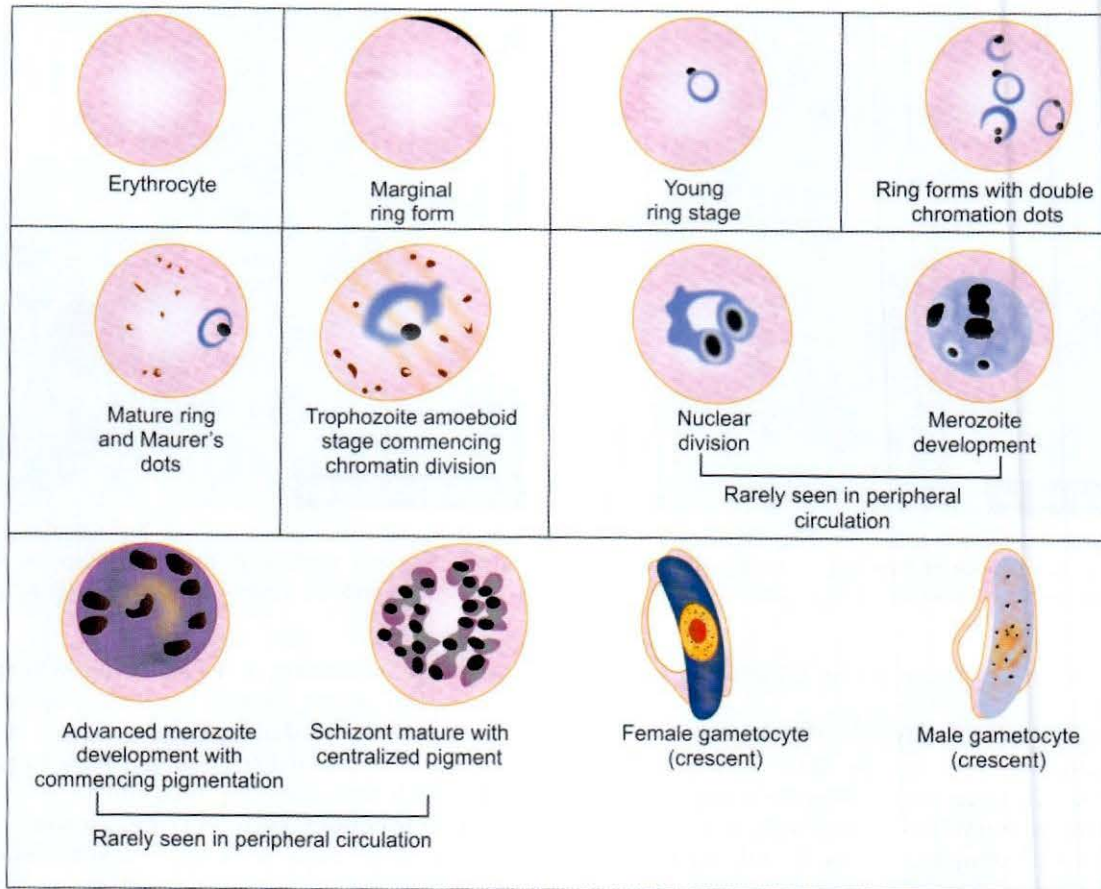


Fig. 8: *Plasmodium falciparum* (Giemsa stain, magnification 2000X)

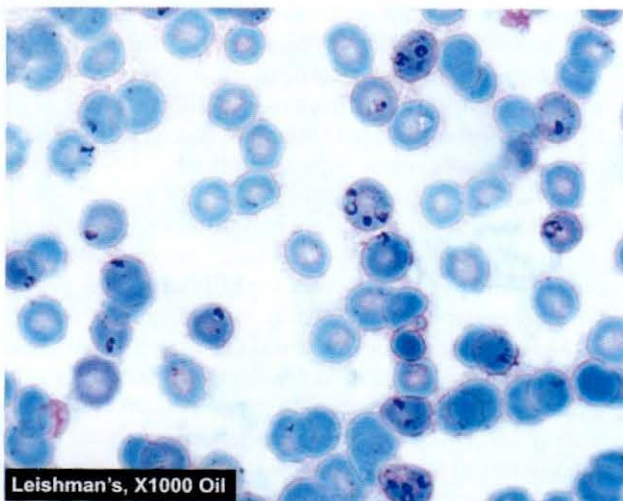


Fig. 9: Malarial parasite in blood film—Ring stage of *P. falciparum*
 Source: Mohan H. Textbook of Pathology, 6th edition. New Delhi: Jaypee Brothers Medical Publishers; 2010. p. 189.

Box 2: Pathogenesis of malignant malaria

- Late stage schizonts of *P. falciparum* secrete protein on the surface of RBCs to form knob-like protuberances in erythrocyte's cell membrane. These knobs produce specific adhesive *Plasmodium falciparum* erythrocyte membrane protein-1 (PFEMP-1) so that infected RBCs become sticky.
- Sometime inflammatory cytokines particularly IFN- γ produced by the malaria parasite upregulate the expression of endothelial **cytoadherence** receptors like thrombospondin, E-selectin, VCAM-1, ICAM-1 in capillaries in the brain, chondroitin sulfate B in placenta and CD36 in most other organs. The infected RBCs stick inside and eventually block capillaries and venules. This phenomenon is called **cytoadherence**. At the same stage these *P. falciparum* infected RBCs adhere to uninfected RBCs to form **rosettes**.
- This process of cytoadherence and rosetting causes capillary plugging and decrease microcirculatory flow in vital organs like brain, kidney, lungs, spleen, intestine, bone marrow and placenta resulting in serious complications such as cerebral malaria.
- Other virulence factors of *P. falciparum* are histidine-rich protein II (**HRP II**) and glycosylphosphatidylinositol (**GPI**).

Abbreviations: ICAM-1, intercellular adhesion molecule-1; IFN- γ , interferon gamma; RBCs, red blood cells; VCAM-1, vascular cell adhesion molecule-1

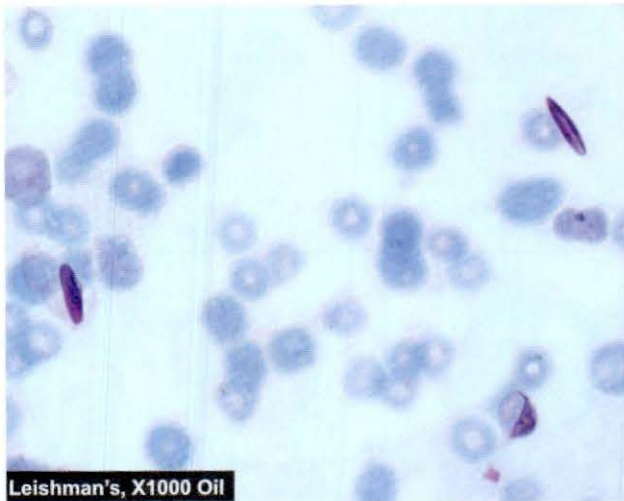


Fig. 10: Malarial parasite in blood film—Gametocytes of *P. falciparum*
 Source: Mohan H. Textbook of Pathology, 6th edition. New Delhi: Jaypee Brothers Medical Publishers; 2010. p. 189.

typically *crescentic*, with sharply rounded or pointed ends. The mature gametocyte is longer than the diameter of the red cell and so produces gross distortion and sometimes even apparent disappearance of the infected red cell. The red cell is often seen as a rim on the concave side of the gametocyte. The cytoplasm in the female gametocyte is deep blue, while in the male it is pale blue or pink. The nucleus is deep red and **compact** in the female, with the *pigment granules* closely aggregated around it, while in the male, it is pink, **large and diffuse**, with the pigment granules scattered in the cytoplasm.

- *Falciparum* crescents can survive in circulation for up to 60 days, much longer than in other species. Gametocytes are most numerous in the blood of young children, 9 months to 2 years old. They, therefore serve as the most effective source of infection to mosquitoes.

Plasmodium Malariae

This was the species of malaria parasite first discovered by Laveran in 1880 and the name *malariae* is the one given by him. It causes **quartan malaria**, in which febrile paroxysms occur *every 4th day*, with **72 hours** interval between the bouts.

- The disease is generally mild, but is notorious for its long persistence in circulation in undetectable levels, for 50 years or more. **Recrudescence** may be provoked by splenectomy or immunosuppression.
- The development of the parasite, in man and mosquito is much slower than with other species. Chimpanzees may be naturally infected with *P. malariae* and may constitute a natural reservoir for quartan malaria.
- *P. malariae* occurs in tropical Africa, Sri Lanka, Burma and parts of India, but its distribution is patchy.

- The sporozoites are relatively *thick*. Pre-erythrocytic schizogony takes about **15 days**, much longer than in other species. Each schizont releases about 15,000 merozoites. *Hypnozoites do not occur*. The **long latency** of the infection is believed to be due to long time survival of few erythrocytic forms in some internal organs.
- *P. malariae* preferentially infects *older erythrocytes* and the degree of parasitization is *low*.
- The ring forms resemble those of *P. vivax*, although thicker and more intensely stained. The old trophozoites are sometimes seen stretched across the erythrocyte as a **broad band**. These **band forms** are a unique feature of *P. malariae*. Numerous large pigment granules are seen (**Fig. 11**).
- The schizonts appear in about 50 hours and mature during the next 18 hours. The mature schizont has an average of eight merozoites, which usually present a *rosette* appearance.
- The infected erythrocytes may be of the normal size or slightly smaller. Fine stippling, called **Ziemann's stippling**, may be seen with special stains. The degree of parasitization is lowest in *P. malariae*.
- Erythrocytic schizogony takes **72 hours**.
- The gametocytes develop in the internal organs and appear in the peripheral circulation when fully grown. Gametocytes occupy nearly the entire red cell. The male has pale blue cytoplasm with a large diffuse nucleus, while the female has deep blue cytoplasm and a small compact nucleus.

Plasmodium Ovale

This parasite produces a tertian fever resembling *vivax* malaria, but with milder symptoms, prolonged latency and fewer relapses.

- It is the **rarest of all plasmodia** infecting humans and is seen mostly in tropical Africa, particularly along the West Coast.
- The pre-erythrocytic stage extends for 9 days. Hepatocytes containing schizonts usually have enlarged nuclei. The mature liver schizont releases about 15,000 merozoites. **Hypnozoites are present**.
- The trophozoites resemble those in *vivax* malaria, but are usually more compact, with less amoeboid appearance. **Schuffner's dots** appear earlier and are more abundant and prominent than in *vivax* infection (**Fig. 12**).
- The infected erythrocytes are slightly enlarged. In thin films, many of them present an oval shape with fimbriated margins. This oval appearance of the infected erythrocyte is the reason for the name *ovale* given to this species.
- The schizonts resemble those of *P. malariae*, except that the pigment is **darker** and the erythrocyte is usually *oval*, with prominent Schuffner's dots.

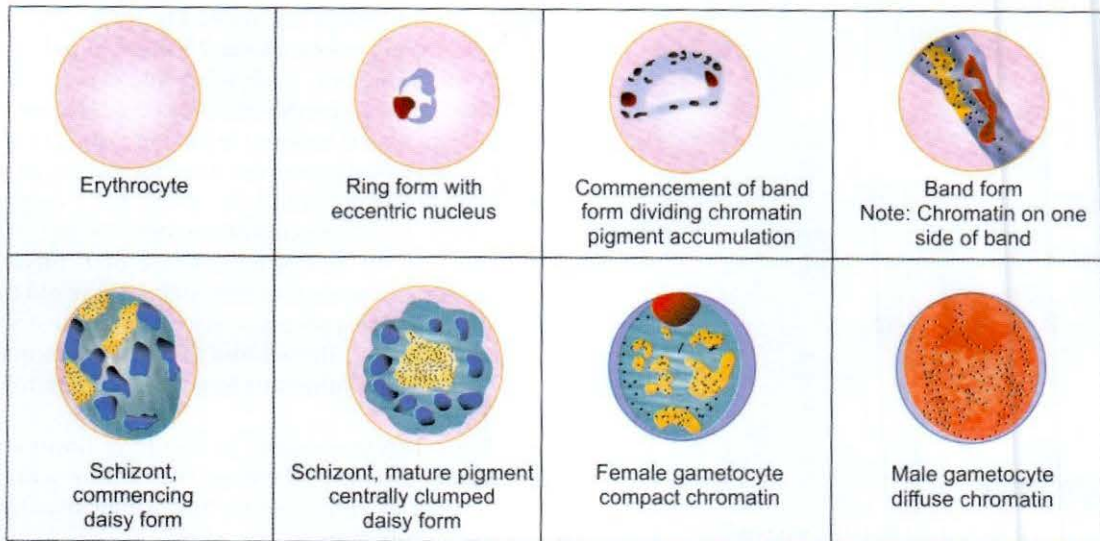


Fig. 11: *Plasmodium malariae* stages of erythrocytic schizogony (Giemsa stain, magnification 2000X)

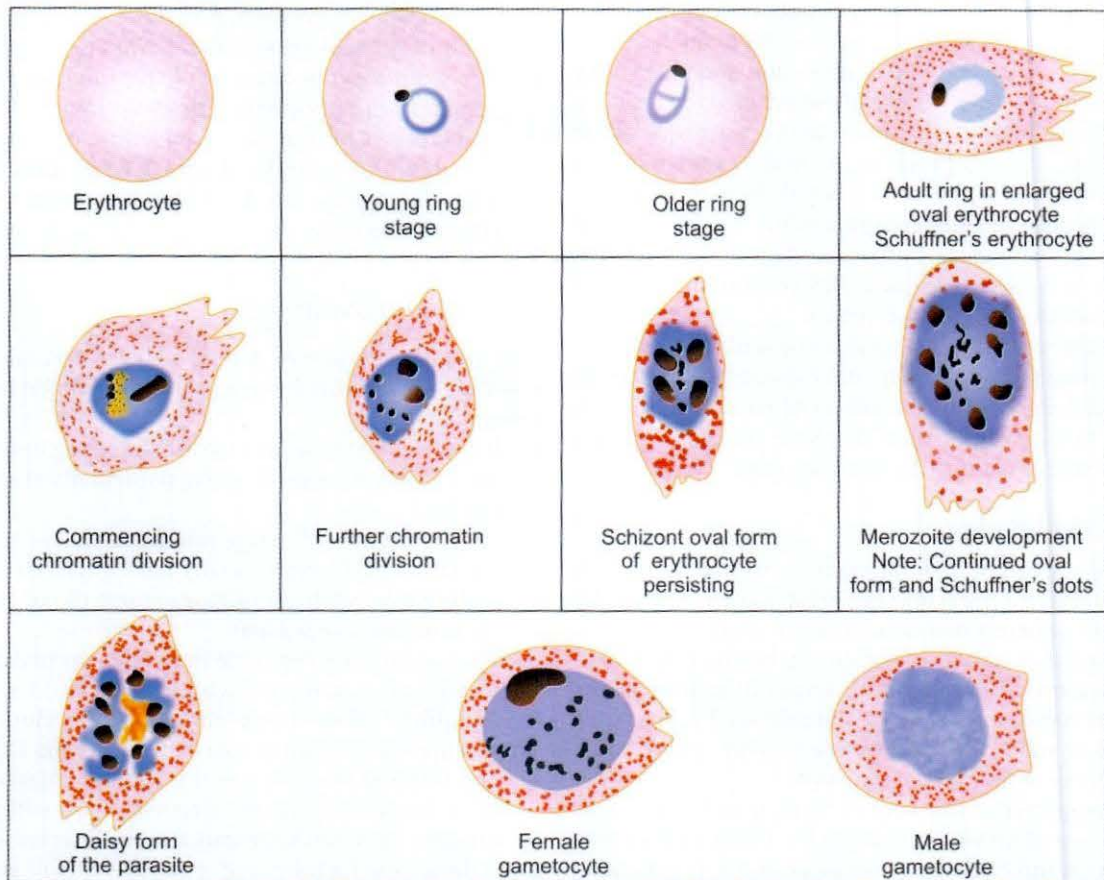


Fig. 12: *Plasmodium ovale* stages of erythrocytic schizogony (Giemsa stain, magnification 2000X)

Mixed Infections

In endemic areas it is not uncommon to find mixed infections with **two or more** species of malaria parasites in the same individual.

- Mixed infection with *P. vivax* and *P. falciparum* is the most common combination with a tendency for one or the other to predominate.
- The clinical picture may be *atypical* with bouts of fever occurring **daily**.
- Diagnosis may be made by demonstrating the characteristic parasitic forms in thin blood smears.

The characteristics of the four species of plasmodia infecting man are listed in **Table 3**.

Pathogenesis

Clinical manifestations in malaria are caused by products of erythrocytic schizogony and the host's reaction to them.

- The disease process in malaria occurs due to the local or systemic response of the host to parasite antigens and **tissue hypoxia** caused by reduced oxygen delivery because of obstruction of blood flow by the parasitized erythrocytes.
- **Liver** is enlarged and congested. Kupffer cells are increased and filled with parasites. **Hemozoin pigments** are also found in the parenchymal cells (**Fig. 13**). Parenchymal cells show fatty degeneration, atrophy and **centrilobular necrosis**.

Table 3: Comparison of the characteristics of plasmodia causing human malaria

	<i>P. vivax</i>	<i>P. falciparum</i>	<i>P. malariae</i>	<i>P. ovale</i>
Hypnozoites	Yes	No	No	Yes
Erythrocyte preference	Reticulocytes	Young erythrocytes, but can infect all stages	Old erythrocytes	Reticulocytes
Stages found in peripheral blood	Rings, trophozoites, schizonts, gametocytes	Only rings and gametocytes	As in <i>vivax</i>	As in <i>vivax</i>
Ring stage	Large, 2.5 μm , usually single, prominent chromatin	Delicate, small, 1.5 μm , double chromatin, and multiple rings common, acrole forms found	Similar to <i>vivax</i> , but thicker	Similar to <i>vivax</i> , more compact
Late trophozoite	Large irregular, actively ameboid, prominent vacuole	Compact, seldom seen in blood smear	Band form characteristic	Compact, coarse pigment
Schizont	Large filling red cell	Small, compact, seldom seen in blood smear	Medium size	Medium size
Number of merozoites	12–24 in irregular grape-like cluster	8–24 grape-like cluster	6–12 in daisy-head or rosette pattern	6–12 irregularly arranged
Microgametocyte (male gametocyte)	Spherical, compact, pale blue cytoplasm, diffuse nucleus	Sausage or banana-shaped pale blue or pink cytoplasm, large diffuse nucleus	As in <i>vivax</i>	As in <i>vivax</i>
Macrogametocyte (female gametocyte)	Large, spherical, deep blue cytoplasm, compact nucleus	Crescentic, deep blue cytoplasm, compact nucleus	As in <i>vivax</i>	As in <i>vivax</i>
Infected erythrocyte	Enlarged, pale, with Schuffner's dots	Normal size, Maurer's clefts, sometimes basophilic stippling	Normal, occasionally Ziemann's stippling	Enlarged, oval fimbriated, prominent Schuffner's dots
Duration of schizogony (days)	2	2	3	2
Prepatent period (days)	8	5	13	9
Average incubation period (days)	14	12	30	14
Appearance of gametocyte after parasite patency (days)	4–5	10–12	11–14	5–6
Duration of sporogony in mosquito (25°C) (days)	9–10	10–12	25–28	14–16
Average duration of untreated infection (years)	4	2	40	4

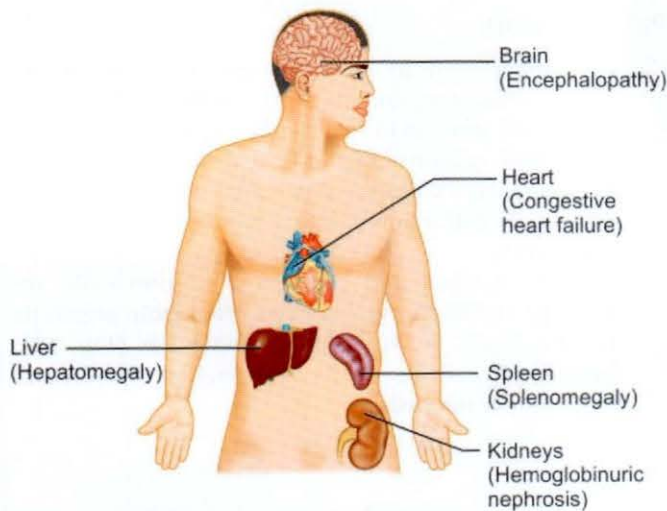


Fig. 13: Major pathological changes in organs in malaria

Box 3: Causes of anemia in malaria

- Destruction of large number of RBCs by complement-mediated and autoimmune hemolysis.
- Suppression of erythropoiesis in the bone marrow.
- Increased clearance of both parasitized and nonparasitized RBCs by the spleen.
- Failure of the host to recycle the iron bound in hemozoin pigment.
- Antimalarial therapy in G6PD deficient patients.

Abbreviations: G6PD, glucose-6-phosphate dehydrogenase; RBCs, red blood cells

- **Spleen** is soft, moderately enlarged and congested in acute infection. In chronic cases, spleen is hard with a thick capsule and **slate gray** or **dark brown** or even **black** in color due to dilated sinusoids, pigment accumulation and fibrosis (Fig. 13).
- **Kidneys** are enlarged and congested. Glomeruli frequently contain malarial pigments and tubules may contain hemoglobin casts (Fig. 13).
- **The brain** in *P. falciparum* infection is congested. Capillaries of the brain are plugged with parasitized RBCs. The cut surface of the brain shows slate gray cortex with multiple punctiform hemorrhage in subcortical white matter.
- **Anemia:** After few paroxysms of fever, normocytic and normochromic anemia develops. Anemia is caused by destruction of large number of red cells by complement-mediated autoimmune hemolysis. Spleen also plays an active role by phagocytic removal of a large number of **both infected and uninfected RBCs**. Excess removal of uninfected RBCs may account for up to 90% of erythrocyte loss (Box 3).

Box 4: Incubation period

- It is the time interval between the bite of infective mosquito and the first appearance of clinical symptoms. The duration of incubation period varies with the species of the parasite.
- The average incubation periods of different species of *Plasmodium* are as follows:
 - *P. vivax*: 14 (12–17) days
 - *P. falciparum*: 12 (8–14) days
 - *P. ovale*: 14 (8–31) days
 - *P. malariae*: 28 (18–40) days.

The incubation period is to be distinguished from the *prepatent period*, which is the interval between the entry of the parasites into the host and the time when they first become detectable in blood.

There is also **decreased erythropoiesis** in bone marrow due to tumor necrosis factor (TNF) toxicity and failure of the host to recycle the iron bound in hemozoin pigments.

- **Cytokines** like TNF, interleukin (IL)-1 and interferon (IFN)-gamma play an important role in the pathogenesis of end-organ disease of malaria.

Clinical Features

Benign Malaria

- **Incubation period:** 12–17 days (Box 4).
- The typical clinical feature of malaria consists of periodic bouts of **fever with chill and rigor**, followed by **anemia, spleno-megaly and hepatomegaly**.
- The classic febrile paroxysm comprises of three distinct stages—(1) **cold stage**, (2) **hot stage** and (3) **sweating stage**.
 1. **Cold stage:** The patient feels intense cold with chill and rigor along with lassitude, headache and nausea. This stage lasts for 15 minutes to 1 hour.
 2. **Hot stage:** The patient feels intensely hot. The temperature mounts to 41°C or higher. Headache persists but nausea commonly diminishes. This stage lasts for 2–6 hours.
 3. **Sweating stage:** Profuse sweating follows the hot stage and the temperature comes down to normal. The skin is cool and moist. The patient usually falls asleep to wake up refreshed.
- The paroxysm usually begins in the **early afternoon** and lasts for 8–12 hours. The febrile paroxysm synchronizes with the erythrocytic schizogony.
- The **periodicity** is approximately **48 hours** in tertian malaria (in *P. vivax*, *P. falciparum* and *P. ovale*) and **72 hours** in quartan malaria (in *P. malariae*).
- Quotidian periodicity, with fever occurring at 24 hour intervals may be due to two broods of tertian parasites maturing on successive days or due to mixed infection.
- Regular periodicity is seldom seen in primary attack, but is established usually only after a few days of continuous,

remittent, or intermittent fever. True rigor is typically present in *vivax* malaria and is less common in *falciparum* infection.

- There can be both hypoglycemia or hyperglycemia in malaria.
- Sometimes, there may be *hyperkalemia* due to red cell lysis and fall in blood pH.
- Infection with *P. vivax* usually follows a chronic course with periodic relapses, whereas *P. ovale* malaria is generally mild. Although *P. malariae* malaria is less severe, but it may lead to renal complications. Relapse mainly occurs in inadequately treated cases after an interval of 8–40 weeks or more.

Malignant Tertian Malaria

Incubation period: 8–14 days.

The most serious and fatal type of malaria is malignant tertian malaria caused by *P. falciparum*. *Falciparum* malaria if not treated timely or adequately, severe life-threatening complications may develop. In severe *falciparum* malaria, parasitic load is very high and more than 5% red cells are affected. The term pernicious malaria also have been applied to these conditions that include cerebral malaria, blackwater fever, algid malaria and septicemic malaria (**Box 5**).

- **Cerebral malaria:** It is the most common complication of malignant malaria.
 - The initial symptoms are nonspecific with fever, headache, pain in back, anorexia and nausea.
 - **Anemia:** The patient may be anemic and mildly jaundiced.
 - **Hepatosplenomegaly:** Liver and spleen are enlarged and nontender.
 - Thrombocytopenia is common.
 - After 4–5 days of high fever, cerebral malaria is manifested by features of **diffuse symmetric encephalopathy** like headache, confusion, increased muscle tone, seizures, paralysis, slowly lapsing to coma.

Box 5: Complications of *falciparum* malaria

- Cerebral malaria
- Algid malaria
- Septicemic malaria
- Blackwater fever
- Pulmonary edema
- Acute renal failure
- Hypoglycemia (<40 mg/dL)
- Severe anemia (Hb<5 g/dL, PCV<15%)
- Hyperpyrexia
- Metabolic acidosis and shock
- Bleeding disturbances
- Hyperparasitemia.

Abbreviations: Hb, hemoglobin; PCV, packed cell volume

- Retinal hemorrhages may be seen in 15% of adults.
- **Hypoglycemia** is common in patients following quinine therapy or with hyperparasitemia.
- In 10% of cases renal dysfunction progressing to acute renal failure may occur.
- Other complications include **metabolic acidosis**, pulmonary edema and shock.
- Even with treatment, death occurs in 15% of children and 20% of adults who develop cerebral malaria.
- This occurs particularly when nonimmune persons have remained untreated or inadequately treated for 7–10 days after development of the primary fever.
- The basic pathogenesis of cerebral malaria is due to **erythrocyte sequestration** in microvasculature of various organs.

Late stage schizonts of *P. falciparum* secrete a protein on the surface of RBCs to form **knob-like** deformities. This knob produces specific adhesive proteins [*Plasmodium falciparum* erythrocyte membrane protein-1 (**PfEMP-1**)], which promote aggregation of infected RBCs to other noninfected RBCs and receptors of capillary endothelial cells. These sequestered RBCs cause **capillary plugging** of cerebral microvasculature, which results in anoxia, ischemia and hemorrhage in brain.

- **Blackwater fever:** A syndrome called blackwater fever (malarial hemoglobinuria) is sometimes seen in *falciparum* malaria, particularly in patients, who have experienced repeated past infections and inadequate treatment with quinine. An autoimmune mechanism has been suggested.
 - Patients with glucose-6-phosphate dehydrogenase (G6PD) deficiency may develop this condition after taking oxidant drugs, even in the absence of malaria.
 - Clinical manifestations include fever, prostration and hemoglobinuria (**black colored urine**), bilious vomiting and prostration, with passage of dark red or blackish urine.
 - The pathogenesis is believed to be massive intravascular hemolysis caused by antierythrocyte antibodies, leading to massive absorption of hemoglobin by the renal tubules (**hemoglobinuric nephrosis**) producing blackwater fever. Complications of blackwater fever include renal failure, acute liver failure and circulatory collapse.
- **Algid malaria:** This syndrome is characterized by peripheral circulatory failure, rapid thready pulse with low blood pressure and cold clammy skin. There may be severe abdominal pain, vomiting, diarrhea and profound shock.
- **Septicemic malaria:** It is characterized by high continuous fever with dissemination of the parasite to various organs, leading to multiorgan failure. Death occurs in 80% of the cases.

Merozoite-induced Malaria

Natural malaria is sporozoite-induced, the infection being transmitted by sporozoites introduced through the bite of vector mosquitoes. Injection of merozoites can lead to direct infection of red cells and erythrocytic schizogony with clinical illness. Such merozoite-induced malaria may occur in the following situations:

- **Transfusion malaria:** Blood transfusion can accidentally transmit malaria, if the donor is infected with malaria. The parasites may remain viable in blood bank for 1–2 weeks. As this condition is induced by direct infection of red cells by the merozoites, pre-erythrocytic schizogony and hypnozoites are absent. *Relapse does not occur and incubation period is short.*

Table 4 enumerates the differences between mosquito-borne malaria and blood transfusion malaria.

- **Congenital malaria:** A natural form of merozoite-induced malaria, where the parasite is transmitted transplacentally from mother to fetus.
- **Renal transplantation** may lead to malaria if the donor had parasitemia.
- **Shared syringes** among drug addicts may be responsible.

Tropical Splenomegaly Syndrome

Tropical splenomegaly syndrome (TSS) or hyper-reactive malarial splenomegaly (HMS) is a benign condition seen in people of malaria endemic areas mainly tropical Africa, New Guinea and Vietnam.

It happens from abnormal immunological response to repeated malaria infection.

- Tropical splenomegaly syndrome is characterized by high level of immunoglobulin M (IgM) against malaria due to polyclonal activation of B-cells, decreased C3 and massive splenomegaly. Malaria parasite is **absent** in peripheral blood.

Table 4: Difference between mosquito-borne malaria and blood transfusion malaria

	Mosquito-borne malaria	Blood transfusion malaria
Mode of transmission	Mosquito bite	Blood or blood products transfusion
Infective stage	Sporozoite	Trophozoite
Incubation period	Long	Short
Pre-erythrocytic schizogony	Present	Absent
Hypnozoites	May be present	Absent
Severity	Comparatively less	More complications seen
Relapse	May occur	Does not occur
Radical treatment	Required	Not required

- A normocytic normochromic anemia is present which does not respond to hematinics or antihelminthics.
- Spleen and liver are enlarged, congested, with dilated sinusoids and marked lymphocytic infiltration. Numerous pigment-laden Kupffer cells dot the liver. Changes are also seen in bone marrow, kidneys and adrenals.
- Tropical splenomegaly syndrome differs from various other types of splenomegalies seen in the tropics in its response to antimalarial treatment.

Immunity

Immunity in malaria could be two types: (1) *innate immunity* and (2) *acquired immunity*.

Innate Immunity

- It is the inherent, nonimmune mechanism of host resistance against malarial parasite.
- Innate immunity could be due to:
 - **Duffy negative red blood cells:** The invasion of red cells by merozoites requires the presence of specific glycoprotein receptors on the erythrocyte surface. It has been found duffy blood group negative persons are protected from *P. vivax* infection. *Duffy blood group is absent in West Africa where P. vivax malaria is not prevalent.*
 - **Nature of hemoglobin: Hemoglobin E** provides natural protection against *P. vivax*. *P. falciparum* does not multiply properly in sickled red cells containing **HbS**. Sickle cell anemia trait is very common in Africa, where *falciparum* malaria is hyperendemic and offers a survival advantage. **HbF** present in neonates protects them against all *Plasmodium* species.
 - **Glucose-6-phosphate dehydrogenase deficiency:** Innate immunity to malaria has also been related to G6PD deficiency found in Mediterranean coast, Africa, Middle East and India.
 - **Human leukocyte antigen-B53:** Human leukocyte antigen-B53 (HLA-B53) is protected from cerebral malaria associated with protection from malaria.
 - **Nutritional status:** Patients with iron deficiency and severe malnutrition are relatively resistant to malaria.
 - **Pregnancy:** *Falciparum* malaria is more severe in pregnancy, particularly in primigravida and may be enhanced by iron supplementation.
 - **Splenectomy:** The spleen appears to play an important role in immunity against malaria. Splenectomy enhances susceptibility to malaria.

Acquired Immunity

Infection with malaria parasite induces specific immunity involving both humoral and cellular immunity, which can

bring about clinical cure, but cannot eliminate parasites from the body.

- It can prevent superinfection, but is not powerful enough to defend against reinfection. This type of resistance in an infected host, which is associated with continued asymptomatic parasite infection is called **premunition**. This type of immunity disappears once the infection is eliminated.

Humoral immunity: Circulating antibodies (IgM, IgG and IgA) against asexual forms give protection by inhibiting red cell invasion and antibodies against sexual forms reduce transmission of malaria parasite.

- Acquired antibody-mediated immunity is transferred from mother to fetus across the placenta and is evident in endemic areas where infants below the age of 3 months are protected by passive maternal antibodies.
- Young children are highly susceptible to malaria. As they grow up, they acquire immunity by subclinical or clinical infections, so that incidence of malaria is low in older children and adults.

Cellular immunity: Sensitized T cells release cytokines that regulate macrophage activation and stimulate B cells to produce antibodies. The activated macrophages inside liver, spleen and bone marrow phagocytose both parasitized and nonparasitized RBCs.

Clinical note: Protective immunity against malaria is species specific, stage specific and strain specific.

Recrudescence and Relapse

Recrudescence

In *P. falciparum* and *P. malariae* infections after the primary attack, sometimes there is a **period of latency**, during which there is no clinical illness. But some parasites persist in some erythrocytes, although the level of parasitemia is below the fever threshold or sometimes below the microscopic threshold. Erythrocytic schizogony is repeated at a low level in the body when the number of parasites attain a significant level, fresh malarial attack develops. *This recurrence of clinical malaria caused by persisting P. falciparum and P. malariae is called recrudescence.* Recrudescence may be due to **waning immunity** of the host or possibly due to **antigenic variation**. In *P. falciparum* infections, recrudescences are seen for 1–2 years, while in *P. malariae* infection, they may last for long periods, even up to 50 years (**Table 5**).

Relapse

It is seen in inadequately treated *P. vivax* and *P. ovale* infections. In both these species, two kinds of sporozoites are seen, some of which multiply inside hepatocytes promptly

Table 5: Differences between recrudescence and relapse

Recrudescence	Relapse
Seen in <i>P. falciparum</i> and <i>P. malariae</i>	Seen in <i>P. vivax</i> and <i>P. ovale</i>
Due to persistence of the parasite at a subclinical level in circulation	Due to reactivation of hypnozoites present in liver cells
Occurs within a few weeks or months of a previous attack	Occurs usually 24 weeks to 5 years after the primary attack
Can be prevented by adequate drug therapy or use of newer antimalarial drugs in case of drug resistance	Can be prevented by giving primaquine to eradicate hypnozoites

to form schizonts and others which remain dormant. These latter forms are called **hypnozoites** (from *hypnos*: sleep). Hypnozoites remain inside the hepatocytes as uninucleated forms, 4–5 µm in diameter, for long periods. **Reactivation of hypnozoites** leads to initiation of fresh erythrocytic cycles and new attacks of malarial fever. Such new attacks of malaria, caused by dormant exoerythrocytic forms, reactivated usually from 24 weeks to 5 years after the primary attack are called **relapses** (**Table 5**).

Laboratory Diagnosis

Demonstration of Parasite by Microscopy

Diagnosis of malaria can be made by demonstration of malarial parasite in the blood (**Box 6**).

Two types of smears are prepared from the peripheral blood. One is called **thin smear** and the other is called **thick smear**.

1. **Thin smears:** They are prepared from capillary blood of finger tip and spread over a good quality slide by a second slide held at an angle of 30–45° from the horizontal such that a tail is formed.
 - A properly made thin film will consist of an unbroken smear of a **single layer of red cells**, ending in a tongue, which stops a little short of the edge of the slide.
 - Thin smears are air dried rapidly, fixed in alcohol and stained by one of the Romanowsky stains such as Leishman, Giemsa, Field's, or JSB stain (named after Jaswant Singh and Bhattacharjee).
 - Thin smears are used for detecting the parasites and **determining the species**.
2. **Thick smears:** They can be made on the same slide of thin smear or separately.
 - In a thick film, usually **three drops** of blood are spread over a small area (about 10 mm).
 - The amount of blood in thin smear is about **1–1.5 µL**, while in a thick smear it is **3–4 µL**.
 - The thick film is dried and kept in a Koplín jar for 5–10 minutes for dehemoglobinization.

Box 6: Morphological feature of malaria parasites in blood smear

- In *P. vivax*, *P. ovale* and *P. malariae* all asexual forms and gametocytes can be seen in peripheral blood. In *P. falciparum* infection, only ring form alone or with gametocytes can be seen.
- Ring forms of all species appear as streaks of blue cytoplasm with detached nuclear dots. They are large and compact in *P. vivax*, *P. ovale*, and *P. malariae* and fine delicate with double chromatin (*head-phone appearance*). In *P. falciparum*, multiple rings with "accolé" forms are seen.
- Gametocytes are *banana-shaped* (crescents) in *P. falciparum* and *round* in *P. vivax*, *P. ovale* and *P. malariae*.
- Enlarged red blood cells (RBCs) with intracellular coarse brick-red stippling (*Schuffner's dots*) are characteristic in *P. vivax*. In *P. falciparum*, RBCs are normal in size with large red dots (*Maurer's dots*) and sometimes, with *basophilic stippling*. Careful search in blood should be made for *mixed infections*.

Box 7: Quantification of parasites

Quantification of parasites can be done by thick smear. The counting of parasites are done to an approximate number in the following method:

- + = 1–10 parasite per 100 thick film fields
- ++ = 11–100 parasite per 100 thick film
- +++ = 1–10 parasite per thick film field
- ++++ = More than 10 parasite per thick film field.

- It is not fixed in methanol.
- Thick film is stained similar to thin film.
- The stained film is examined under the oil immersion microscope.
- The thick film is more **sensitive**, when examined by an experienced person, because it concentrates **20–30 layers** of blood cells in a small area.
- Thick film is more suitable for rapid detection of malarial parasite, particularly when they are few (as low as **20 parasites/ μ L**) (**Box 7**).
- The dehemoglobinized and stained thick film does not show any red cells, but only leukocytes, and, when present, the parasites. But the parasites are often distorted in form, and as the diagnostic changes in blood cells such as *enlargement* and *stippling* cannot be made out, *species identification is difficult*.
- Thin film is examined first at the tail end and if parasites are found, there is no need for examining thick film. If parasites are not detected in thin film, then thick film should be examined.
- It is recommended that 200 oil immersion fields should be examined before a thick film is declared negative (**Fig. 14**).

Quantitative Buffy Coat, Smear

The quantitative buffy coat (**QBC**) test is a novel method for diagnosing malaria, wherein a small quantity of blood (50–110 μ L) of blood is spun in QBC centrifuge at 12,000 revolutions per minutes for 5 minutes.

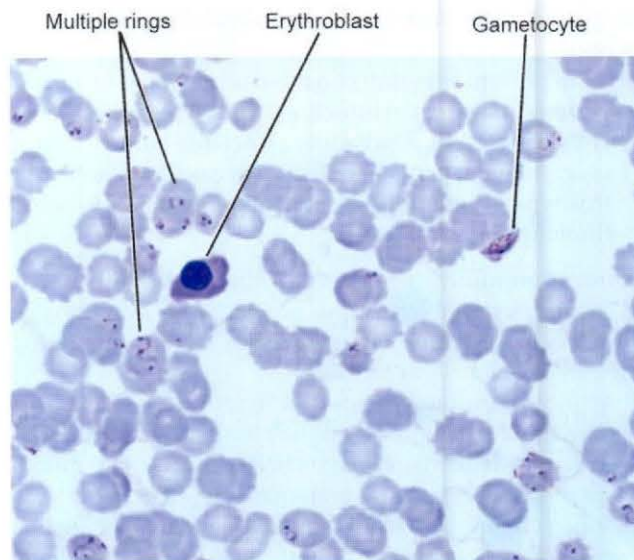


Fig. 14: Malarial parasite, *Plasmodium falciparum*, in the peripheral blood showing numerous ring stages and a crescent of gametocyte. The background shows a normoblast

Source: Mohan H. Textbook of Pathology, 6th edition. New Delhi: Jaypee Brothers Medical Publishers; 2010. p. 314.

- Red blood cell containing malaria parasites are less dense than normal RBCs and concentrate just below the buffy coat of leukocytes at the top of the erythrocytic column.
- Precoating of the tube with acridine orange induces a fluorescence on the parasites, which can then be readily visualized under the oil immersion microscope because the parasite contains deoxyribonucleic acid (DNA), but the mature RBCs do not contain DNA and ribonucleic acid (RNA). The nucleus of the parasite is detected by acridine orange stains and appears as fluorescing **greenish-yellow** against red background.
- The advantage of QBC is that it is faster and more sensitive than thick blood smear.
- The disadvantage of the test is that it is less sensitive than thick film and is expensive.
- A careful smear examination still remains as the "gold standard" in malaria diagnosis.

Microconcentration Technique

In microconcentration technique, blood sample is collected in microhematocrit tube and centrifuged at high speed. The sediment is mixed with normal serum and smear is prepared. Though it increases the positivity rate, it changes the morphology of the parasite.

Culture of Malaria Parasites

- The original method of petridish culture employed a candle jar to provide an atmosphere of 3% oxygen and

10% carbon dioxide and a relatively simple self-culture medium (**RPMI1640**) supplemented with human, rabbit, or calf serum to maintain infected erythrocytes. Fresh red cells were added periodically for continuation of the growth and multiplication of plasmodia. The continuous flow method devised by Trager enables the prolonged maintenance of stock cultures.

- Computer-controlled culture systems, introduced subsequently, provide a steady abundant supply of parasites. Several culture lines have been established from blood of infected *Aotus monkey* or directly from human patients.
- Schizogony proceeds normally in culture. Gametocytes are formed infrequently. Pre-erythrocytic stages of some species have been obtained in tissue cultures. Plasmodia retain their infectivity in culture.
- Culture of plasmodia provides a source of the parasites for study of their antigenic structure, in seroepidemiologic surveys, drug sensitivity tests and studies in immunoprophylaxis.

Serodiagnosis

Serodiagnosis is not helpful in clinical diagnosis because they will not differentiate between an active and past infection. It is used mainly for seroepidemiological survey and to identify the infected donors in transfusion malaria. The tests used are indirect hemagglutination (*IHA*), indirect fluorescent antibody (*IFA*) test and enzyme-linked immunosorbent assay (*ELISA*).

Newer Methods of Diagnosis (Box 8)

Fluorescence microscopy:

Kawamoto technique: Fluorescent dyes like acridine orange or benzothio-carboxy purine are used, which stain the parasites entering the RBCs but not white blood cells (WBCs). This is a method of differential staining.

- Acridine orange stains DNA as fluorescent green and cytoplasmic RNA as red.

Box 8: Laboratory diagnosis of malaria

- Demonstration of malarial parasites in thick and thin blood smear examination by Leishman, Giemsa, or JSB stain.
- Immunofluorescence staining and QBC smear.
- Rapid immunochromatographic test (ICT) for detection of malaria antigen (PfHRP-2 and pLDH).
- *Molecular diagnosis:* DNA probe and PCR.
- Routine blood examination for Hb, PCV and blood sugar.

Abbreviations: DNA, deoxyribonucleic acid; Hb, hemoglobin; JSB, Jaswant Singh and Bhattacharjee; PCR, polymerase chain reaction; PCV, packed cell volume; PfHRP-2; *Plasmodium falciparum* histidine rich protein-2; pLDH, parasite lactate dehydrogenase; QBC, quantitative buffy coat

- The stained slide is examined under fluorescent microscope.
- The method is mainly used for mass screening in field laboratory.

Rapid antigen detection tests: Rapid diagnostic test are based on the detection of antigens using immunochromatographic methods. These rapid antigen detection tests have been developed in different test formats like the dipstick, card and cassette bearing monoclonal antibody, directed against the parasite antigens. Several kits are available commercially, which can detect *Plasmodium* in 15 minutes (**Fig. 15**).

Parasite-F test: This test is based on detection of histidine rich protein-2 (HRP-2) antigen produced by the asexual stages of *P. falciparum* expressed on the surface of red cells.

- Monoclonal antibody produced against **HRP-2 antigen** (Pf band) is employed in the test strip.
- **Advantage:** It is widely popular and has high sensitivity (98%) and specificity.
 - The test is said to detect low asexual parasitemia of more than 40 parasites/ μ L.
 - The test can be performed within 10 minutes.
- **Disadvantage:** *Plasmodium falciparum* HRP-2 (PfHRP-2) antigen detection test cannot detect the other three malaria species.
 - It remains positive up to 2 weeks after cure.
 - In *P. falciparum* infection, PfHRP-2 is not secreted in gametogony stage. Hence in “carriers”, the Pf band may be absent.

Dual antigen test: The test detects parasite lactate dehydrogenase (**pLDH**) produced by trophozoites and gametocytes of all plasmodium species and **PfHRP-2 antigen** produced by *P. falciparum* simultaneously.

- Thus, one band (Pv band) is genus specific (*Plasmodium specific*) and other is *Plasmodium falciparum* specific (Pf band).

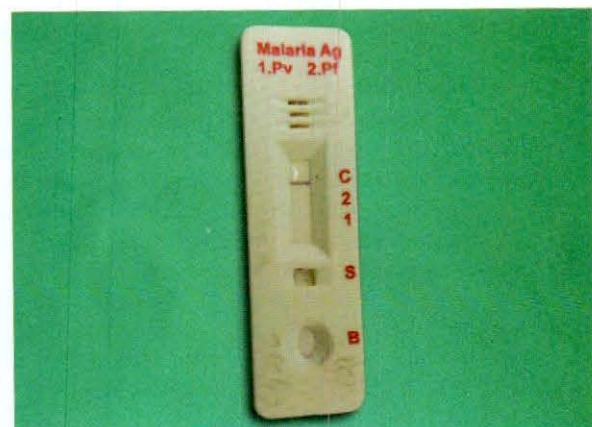


Fig. 15: Rapid ICT Kit for dual antigen

- This test is a rapid two-site sandwich immunoassay used for specific detection and differentiation of *P. falciparum* and *P. vivax* malaria in areas with high rates of mixed infection.
- The “Pv” band can be used for monitoring success of antimalarial therapy in case of stained alone *P. vivax* infection as the test will detect only live parasites and therefore will be negative, if the parasite has been killed by the treatment.
- The disadvantage of the test is that it is expensive and cannot differentiate between *P. vivax*, *P. ovale* and *P. malariae*.

Molecular Diagnosis

Deoxyribonucleic acid probe: Deoxyribonucleic acid probe is a highly sensitive method for the diagnosis of malaria. It can detect less than 10 parasites/ μ L of blood.

Polymerase chain reaction: Polymerase chain reaction (PCR) is increasingly used now for species specification and for detection of drug resistance in malaria.

- Chloroquine resistance in *P. falciparum* is due to mutation in the *Plasmodium falciparum* chloroquine resistance transporter (**PfCRT**), a transporter gene in the parasite.
- Point mutation in another gene *Plasmodium falciparum* multidrug resistance protein 1 (**PfMDR1**) is responsible for resistance in vitro.
- Pyrimethamine and sulfadoxine resistances are associated with point mutations in dihydrofolate reductase (**DHFR**) and dihydropteroate synthase (**DHPS**) genes, respectively.
- Mutation in **PfATPase gene** is associated with reduced susceptibility to artemisinin derivatives.

Other Tests

- Measurement of hemoglobin and packed cell volume (PCV), in case of heavy parasitemia, particularly in children and pregnant woman.
- Total WBC and platelet count in severe *falciparum* malaria.
- Measurement of blood glucose to detect hypoglycemia, particularly in young children and pregnant women with severe *falciparum* malaria and patients receiving quinine.
- Coagulation tests like measurement of antithrombin III level, plasma fibrinogen, fibrin degradation products (FDPs), partial thromboplastin time (PTT), if abnormal bleeding is suspected in *falciparum* malaria.
- Urine for free hemoglobin, if blackwater fever is suspected.
- Blood urea and serum creatinine to monitor renal failure.
- Glucose-6-phosphate dehydrogenase screening before treatment with an antioxidant drug like primaquine.

Treatment

Antimalarial drugs are used with various objectives like clinical cure, prevention of relapse, prevention of transmission and prophylaxis.

Therapeutic

Objective is to eradicate the erythrocytic cycle and clinical cure.

Radical Cure

Objective is to eradicate the exoerythrocytic cycle in liver to prevent relapse.

Gametocidal

Objective is to destroy gametocytes to prevent mosquito transmission and thereby reducing human reservoir.

Chemoprophylaxis

Objective is to prevent infections in nonimmune person visiting endemic areas.

The most commonly used antimalarials are chloroquine, amodiaquine, quinine, pyrimethamine, doxycycline, sulfadoxine, proguanil and primaquine. Newer antimalarial like artemisinin, lumefantrine, mefloquine, halofantrine are now commonly used for multidrug-resistant *P. falciparum* infections.

Treatment of Uncomplicated Malaria

Positive *P. vivax*, *P. ovale* and *P. malariae* cases are treated with **chloroquine 25 mg/kg** divided over **3 days**.

- *Vivax* malaria relapses due to the presence of hypnozoites in the liver. The relapse rate of *vivax* malaria in India is about 30%.
- For prevention of relapse, **primaquine** is given in a dose of 0.25 mg/kg daily for **14 days** under supervision.
- Primaquine is contraindicated in G6PD deficiency patients, infants and pregnant women.
- *In case of chloroquine resistance:* **Quinine** is given in a dose of 600 mg 8 hourly for 7 days along with doxycycline 100 mg/day.

Treatment of Complicated (*Falciparum*) Malaria

Due to emergence of drug resistance of *falciparum* malaria is based on area resistant or sensitive antimalarial drugs.

- **Artemisinin-based combination therapy:** According to revised malaria drug policy in India artemisinin-based

combination therapy (ACT) (**artemisinin + sulfadoxine – pyrimethamine**) should be given to all microscopically positive *falciparum* cases for 3 days in all over India except North-eastern states. This is accompanied by single dose of **primaquine** 45 mg (**0.75 mg/kg**) on day 2 as gametocidal drug.

- In North-eastern states considering resistant to sulfadoxine – pyrimethamine drugs, Technical Advisory Committee on Malaria recommended **artemether (20 mg + lumefantrine)** as per age specific dose schedule.

Note: According to revised Malaria Drug Policy 2013, there is no scope for presumptive treatment. Production and sale of artemisinin as monotherapy has been banned in India as it can lead to development of parasite resistance to the drug.

Drug resistance of malarial parasite:

- A drug resistant parasite is defined as a parasite that will survive and multiply in a dosage that normally cures the infection. Such resistance may be *relative* (yielding to increased doses of the drug tolerated by the host) or *complete* (withstanding a maximum dose tolerated by the host).
- Resistance arises from spontaneous **point mutations** in the genome or gene duplications. The emergence of resistance can be prevented by use of combination of drugs with different mechanisms of action and different drug target.
- Three levels of resistance (R) are defined by the WHO:
 1. **RI:** Following treatment, parasitemia clears but recrudescence occurs.
 2. **RII:** Following treatment, there is a reduction but not a clearance of parasitemia.
 3. **RIII:** Following treatment, there is no reduction of parasitemia.

The earlier method of classifying resistance is based on counting trophozoites in blood film daily for 7 days after treatment and monitoring the patient for any subsequent recrudescence. All patients with a *falciparum* parasitemia of more than one trophozoite per high power field (+++ or over) in areas of suspected drug resistance, should be checked for a decrease and clearing of parasites following treatment.

Prophylaxis

Chemoprophylaxis

It is recommended for travelers going to endemic areas as short-term measure.

Chloroquine (300 mg) or mefloquine (400 mg) weekly should be given 1 week and 2 weeks before travel to endemic area respectively.

Alternatively doxycycline (100 mg) daily can be given from day 1 before travel.

Malaria Vaccine

Malaria vaccine is an area of intensive research. Over past decades, there has been a significant progress in malaria vaccine development. A completely effective vaccine is not yet available for malaria, although several vaccines are under development. **SPf66** (a cocktail of four antigens, three asexual blood stage antigens + circumsporozoite of Pf) was tested extensively in endemic areas in the 1990s, but clinical trials showed it to be insufficiently effective. Other vaccine candidates targeting the blood stage of parasite's life cycle using merozoite surface protein 1 (**MSP1**), **MSP2**, **MSP13** and ring-infected erythrocyte surface antigens (**RESAs**) have also been in insufficient on their own. Several potential vaccines targeting the pre-erythrocytic stage are being developed, with **RTS,S/AS01** showing the most promising results. The **RTS,S/AS01** (commercial name, **mosquirix**) was engineered using genes from the *outer protein of P. falciparum* and a portion of *hepatitis B virus*, plus a chemical adjuvant (**AS01**) to boost immune response.

Vector Control Strategies

- **Residual spraying:** Spraying of residual insecticides, e.g. dichlorodiphenyltrichloroethane (DDT), malathion and fenitrothion in the indoor surfaces of the house is highly effective against adult mosquitos.
- **Space application:** Insecticidal formulation is sprayed into the atmosphere by ultra-low volume in the form of mist or fog to kill insects (pyrethrum extracts).
- **Individual protection:** Man-vector contact can be reduced by other preventive measures such as the use of repellants, protective clothing, bed net, preferably impregnated with long-acting repellant, mosquito coils and screening of house.

Antilarval Measures

- Old antilarval measures such as **oiling** the collection of standing water or dusting them with **Paris green** have now become promising with the increase of insecticide resistance.
- **Source reduction:** Mosquito breeding sites can be reduced by proper drainage, filling of land, water level management, intermittent irrigation, etc.

Integrated Control

In order to reduce too much dependence on residual insecticides, increasing emphasis is being put on integrated vector control methodology, which includes bioenvironmental and personal protection measures.

Malaria Control Programs

In India, the National Malaria Control Programme was introduced in **1953**, with the objective of the ultimate eradication of the disease and operated successfully for 5 years, bringing down the annual incidence of malaria from 75 million in 1958 to 2 million.

- By 1961, the incidence dropped to an all time low of 50,000 cases and no deaths. However, there have been setbacks from 1970 and by 1976, the incidence rose to 6.4 million cases. With the implementation of **modified plan of operation in 1977**, the upsurge of malaria cases dropped down to 2.1 million cases in 1984. Since then, the epidemiological situation has not shown any improvement.
- Malaria control added impetus as "**roll-back malaria initiative**" launched jointly by WHO, United Nations Children's Fund (UNICEF), United Nations Development Programme (UNDP) and the World Bank in 1998. Accordingly, National Vector Borne Disease Control Programme (NVBDCP) is implemented by Directorate of Health Services jointly with Mission Directorate and National Rural Health Mission (NRHM). National goal established under the program is to reduce the number of cases and deaths recorded in 2000, by 50% or more in 2010 and by 75% or more by 2015.

BABESIA SPECIES

INTRODUCTION

Babesia is intraerythrocytic sporozoan parasites that morphologically resemble *Plasmodium* and cause tick-borne malaria like illness in domestic and wild animals.

It causes opportunistic infection in humans.

CLASSIFICATION

Order: Piropalasmida

Family: Babesiidae

Species: Medically important *Babesia* species are:

- *B. microti* (rodent strain)
- *B. clivgens* (cattle strain)
- *B. bovis* (cattle strain)

HISTORY AND DISTRIBUTION

Babesia is so named after Babes, who in 1888 described the intraerythrocytic parasite in the blood of cattle and sheep in Romania.

- In 1893, the parasite was shown to cause the **tick-borne disease**, Texas fever, an acute hemolytic disease of cattle in southern United States of America (USA).

- This was the first arthropod-borne disease to have been identified.
- In 2009, more than 700 cases were reported from endemic state of USA.
- Prevalence of *B. microti* is underestimated because young healthy individuals typically experience a mild self-limiting disease and may not seek medical attention.

HABITAT

The parasite is present in erythrocytes and resembles the ring stage of *P. falciparum*.

MORPHOLOGY

Trophozoites are pleomorphic 2-5 μm in diameter found inside the red cells. The shape may be pyriform, ameboid, or spindle-like, usually in pairs and are often mistaken as ring form of *Plasmodium* (Fig. 16).

Merozoites may be spherical or oval or pyriform bodies, found in pairs.

LIFE CYCLE

Definitive Host

Ixodid ticks.

Intermediate Host

Man or other mammals.

Infective Form

Sporozoites are the infective form for humans.

Mode of Transmission

Infection in vertebrate occurs through bite of the nymphal stage of *Ixodid* ticks. Transmission occurs during May to

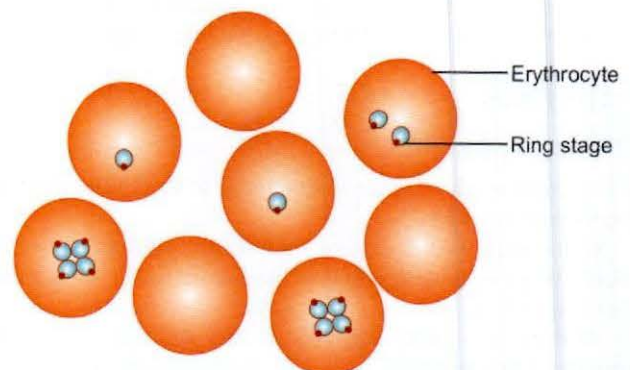


Fig. 16: Trophozoites of *Babesia microti* in human blood smear

September. Incubation period is 1–6 weeks. Babesiosis can also be transmitted via blood transfusion. **Transovarian transmission** in ticks also occurs.

- In their life cycle, merogony takes place in vertebrate hosts and sporogony in the invertebrates.
- Man acquires infection by bite of the infected ticks (**definitive host**).
- Sporozoites present in the salivary glands of tick are introduced in man or other mammals (**intermediate host**).
- Sporozoites change to trophozoites in the circulation, which then invade the RBCs and multiply asexually by binary fission or schizogony to form four or more trophozoites. Newly formed trophozoites are released by rupturing erythrocytes and invade new erythrocytes.
- Some of the sporozoites grow slowly inside red cells and become folded like an accordion. These are thought to be gametocytes.
- Female ticks become infected by feeding the host blood.
- In the digestive tract of tick, the gametocytes multiply sexually and later migrate to the salivary glands where they divide by multiple fission into smaller forms known as “**vermicules**”.
- Vermicules undergo secondary schizogony to produce sporozoites, which are the infective forms for human.

■ PATHOGENICITY AND CLINICAL FEATURES

Hemolysis of the infected erythrocytes is primarily responsible for many clinical manifestations.

- There is accumulation of parasites in the capillaries of liver, spleen and kidneys which leads to cellular degeneration and necrosis.
- The illness develops 1–6 weeks after the tick bite.
- This may be subclinical or mild self-limiting or acute illness, resembling malaria.
- In acute disease, there is malaise, fatigue, fever, myalgia, arthralgia, dry cough and anorexia. Fever exceeds 38°C and can reach 40.6°C accompanied by chill and sweat.
- Less common syndromes are neck stiffness, sore throat, abdominal pain, jaundice and anemia.
- Severe babesiosis is associated with parasitemia levels of more than 4% infected RBCs and requires hospitalization. Fatality rate is 5% among hospitalized cases but is higher (20%) among immunocompromised patients.
- Complications of **acute babesiosis** are renal failure, disseminated intravascular coagulation (DIC), acute respiratory distress syndrome (ARDS) and congestive cardiac failure (CCF).
- Risk factors for complication are **severe anemia** (<10 g%) and high levels of parasitemia.

■ LABORATORY DIAGNOSIS

Microscopy

Diagnosis of babesiosis is primarily done by examination of blood films stained with Leishman or Giemsa stain.

- *Babesia* appears as intraerythrocytic round or pyriform, or ring form simulating *P. falciparum* (**Fig. 16**).
- The ring forms are the most common and lacks the central hemozoin deposit, typical of *P. falciparum*.
- Other distinguishing features are the **absence** of schizonts and gametocytes and presence of tetrads (**maltose crosses**), which are pathognomonic of *B. microti* or *B. duncani* (**Table 6**).

Polymerase Chain Reaction

If parasite cannot be identified by microscopy, amplification of babesial 18S rRNA by PCR is recommended.

Serology

It is useful to confirm the diagnosis. An IFA for *B. microti* is available.

Immunoglobulin M titer of more than 1:64 and IgG titer more than 1:1024, signify active or recent infection. Titer declines over 6–12 months.

Blood Picture

Parasitemia levels typically range from 1% to 20% in immunocompetent patients but can reach up to 85% in asplenic patients.

Table 6: Differential features of malaria and babesiosis

Characteristics	Malaria	Babesiosis
Distribution	Worldwide	North America and Europe
Vector	<i>Anopheles</i> mosquito	Tick
Reservoir	Man	Rodent and cattle
No. of parasites per red blood cell (RBC)	1–3	1–12
Schizont	Present	Absent
Gametocyte	Present	Absent
Pigment in trophozoite	Present	Absent
Antigenic variation	None	Profound
Level of parasitemia	Correlate with severity of disease	Does not correlate with severity of disease
Animal inoculation	Negative	Positive

- Reticulocyte count is elevated.
- Thrombocytopenia is common.
- White blood cell count may be normal or slightly decreased.

Other Tests

Liver function tests such as serum glutamic pyruvate transaminase (SGPT) and alkaline phosphatase yield elevated value.

- Urine analysis may detect hemoglobinuria, excess urobilinogen and proteinuria.
- In renal complications, increased blood urea nitrogen (BUN) and serum creatinine are found.

TREATMENT

B. microti infection appears to be mild and self-limiting. Most of the patients recover without any specific chemotherapy, with only symptomatic treatment.

- In acute cases chemotherapy is required.
- **Atovaquone** 750 mg twice daily, along with **azithromycin** 500 mg-1 g/day for a period of 7-10 days is effective. Alternatively, clindamycin (300-600 mg, 6 hourly) along with quinine (650 mg 6-8 hourly) may be given intravenously.
- In fulminant cases, exchange transfusion is recommended.

PROPHYLAXIS

No vaccine is available at present. There is no role of chemotherapy. Individuals who reside or travel in endemic areas, should wear protective clothing and apply tick repellents.

Individuals with history of symptomatic babesiosis or with positive antibody titer should be indefinitely deferred from donating blood.

KEY POINTS OF PLASMODIUM AND BABESIA

- *Malaria parasite* belongs to the genus *Plasmodium*.
- Four species of *Plasmodium* cause malaria in man—(1) *P. vivax*, (2) *P. falciparum*, (3) *P. malariae* and (4) *P. ovale*.
- **Definitive host:** *Anopheles* mosquito (sexual phase of life cycle).
- **Intermediate host:** Man (asexual phase of life cycle).
- **Infective form:** Sporozoites present in salivary gland of mosquito.
- *P. vivax* and *P. ovale* cause benign tertian malaria, *P. falciparum* causes malignant tertian malaria and *P. malariae* causes benign quartan malaria.

- **Acute falciparum malaria** is the most dangerous and fatal form and is due to heavy parasitization of RBCs which cause blockage of capillary and venules by cytoadherence.
- **Clinical features:** Typical picture of malaria consist of periodic bouts of fever with rigor followed by anemia and splenomegaly. Febrile paroxysms comprise of cold stage, hot stage and the sweating stage.
- **Tropical splenomegaly syndrome** is a chronic benign condition resulting from abnormal immunological response to malaria.
- **Relapse** of malaria occurs in *P. vivax* and *P. ovale* infection due to persistence of dormant stage hypnozoites in liver. **Recrudescence** occurs commonly in *P. falciparum* and *P. malariae* due to persistence of parasite in circulation at a subclinical level.
- **Diagnosis:** By demonstration of parasite in thick and thin smear of peripheral blood and also by detection of malaria antigen by rapid ICT.
- **Treatment:** Chloroquine, sulfadoxine and pyrimethamine along with primaquine. In chloroquine resistance, quinine or artemisinin are used.
- **Babesia species** comprising *B. microti*, *B. divergens* and *B. bovis*, are intraerythrocytic sporozoan parasite resembling plasmodia. They cause opportunistic infections in humans.
- **Mode of transmission:** Through bite of Ixodid ticks.
- **Reservoirs:** Rodents and cattle.
- **Clinical features:** Mild and self-limiting. In immunocompromised patients, it causes anemia, jaundice, hemoglobinuria, respiratory failure, etc.
- **Diagnosis:** By examination of stained blood films for intraerythrocytic parasites, reticulocytosis, increased SGPT, alkaline phosphatase, hemoglobinuria.
- **Treatment:** Atovaquone + azithromycin. Alternatively, clindamycin and quinine may be given.

REVIEW QUESTIONS

1. Describe briefly the life cycle and laboratory diagnosis of:
 - a. *Plasmodium vivax*
 - b. *Plasmodium falciparum*
2. Write short notes on:
 - a. Clinical features of malaria
 - b. Cerebral malaria
 - c. Blackwater fever
 - d. Malignant tertian malaria
 - e. Prophylaxis of malaria
 - f. Treatment of malaria
 - g. Rapid detection test
 - h. Babesiosis
3. Differentiate between:
 - a. Different malarial parasites
 - b. Recrudescence and relapse
 - c. Malaria and Babesiosis

MULTIPLE CHOICE QUESTIONS

1. Old RBCs are preferentially infected by
 - a. *Plasmodium falciparum*
 - b. *Plasmodium malariae*
 - c. *Plasmodium vivax*
 - d. *Plasmodium ovale*
2. The infective form of the malaria parasite is
 - a. Oocyst
 - b. Sporozoite
 - c. Bradyzoite
 - d. Tachyzoite
3. Prolonged parasitism in malaria is due to
 - a. Antigenic variation
 - b. Intracellularity of parasite
 - c. Immunosuppression
 - d. Sequestration
4. Malaria pigment is formed by
 - a. Parasite
 - b. Bilirubin
 - c. Hemoglobin
 - d. All of the above
5. Schuffner's dot in RBCs are seen in infection with
 - a. *Plasmodium vivax*
 - b. *Plasmodium falciparum*
 - c. *Plasmodium malariae*
 - d. *Plasmodium ovale*
6. Quartan malaria is caused by
 - a. *Plasmodium vivax*
 - b. *Plasmodium falciparum*
 - c. *Plasmodium malariae*
 - d. *Plasmodium ovale*
7. Schizonts of *Plasmodium falciparum* are not found in peripheral blood because
 - a. Schizonts are absent in the life cycle
 - b. Schizonts are killed by antibodies
 - c. Schizonts develop only in capillaries of internal organs
 - d. None of the above
8. Crescent-shaped or banana-shaped gametocytes are seen in infection with
 - a. *Plasmodium vivax*
 - b. *Plasmodium falciparum*
 - c. *Plasmodium malariae*
 - d. *Plasmodium ovale*
9. Malaria is not seen in patients with
 - a. G6PD deficiency
 - b. Sickle cell trait
 - c. Duffy negative blood group
 - d. All of the above
10. Which plasmodial infection is more often associated with nephritic syndrome
 - a. *Plasmodium vivax*
 - b. *Plasmodium falciparum*
 - c. *Plasmodium malariae*
 - d. *Plasmodium ovale*
11. Which is the treatment of choice for benign tertian malaria
 - a. Sulfamethoxazole – pyrimethamine
 - b. Quinine
 - c. Mefloquine
 - d. Chloroquine
12. Gametocidal pernicious malaria may occur in
 - a. *Plasmodium vivax*
 - b. *Plasmodium falciparum*
 - c. *Plasmodium malariae*
 - d. *Plasmodium ovale*
13. Babesiosis is transmitted by
 - a. Ticks
 - b. Mites
 - c. Flea
 - d. Mosquito
14. Maltose cross is a characteristic feature of
 - a. *Cryptococcus neoformans*
 - b. *Babesia microti*
 - c. *Blastomycosis*
 - d. *Micrococcus*

Answer

- | | | | | | | |
|------|------|-------|-------|-------|-------|-------|
| 1. b | 2. b | 3. b | 4. c | 5. a | 6. c | 7. c |
| 8. b | 9. d | 10. c | 11. d | 12. b | 13. a | 14. b |

Coccidia

■ INTRODUCTION

The coccidia are unicellular protozoa and belong to the *Phylum Apicomplexa*.

- They live intracellularly, at least during a part of their life cycle, and at some stage in their life cycle, they possess a structure called the *apical complex*, by means of which they attach to and penetrate host cells; hence included in Phylum Apicomplexa.
- All coccidian have a **sexual sporogonic phase** and an **asexual schizogonic phase**.
- Many of them also show an alteration of hosts—a definitive host and an intermediate host.
- Many parasites considered in this chapter have acquired great prominence due to their frequent association with human immunodeficiency virus (HIV) infection.

■ TOXOPLASMA GONDII

History and Distribution

Toxoplasma gondii is an obligate intracellular coccidian parasite, first described in 1908 by Nicolle and Manceaux in

a small North American rodent called **gundi** (*Ctenodactylus gundi*).

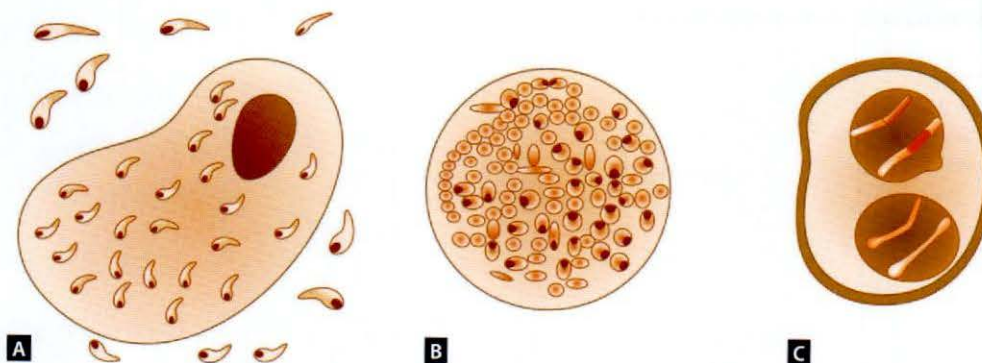
- Its importance as a human pathogen was recognized much later, when Janku in 1923 observed the cyst in the retina of a child with hydrocephalus and microphthalmia.
- The name *Toxoplasma* is derived from the *Greek word Toxon* meaning *arc or brow* referring to the curved shape of the trophozoite.
- *Toxoplasma* is now recognized as the most common protozoan parasite globally, with the widest range of hosts spread over 200 species of birds, reptiles and mammals, including humans.

Morphology

T. gondii occurs in three forms (Figs 1A to C):

1. Trophozoite
2. Tissue cyst
3. Oocyst.

- The trophozoite and tissue cyst represent stages in asexual multiplication (**schizogony**), while the oocyst is formed by sexual reproduction (**gametogony or sporogony**).



Figs 1A to C: *Toxoplasma gondii*. (A) Smear from peritoneal fluid of infected mouse, showing crescentic tachyzoites—extracellular trophozoites and intracellular form within macrophage; (B) Thick-walled tissue cyst containing rounded forms bradyzoites; and (C) Oocyst containing two sporocysts with sporozoites inside

- All three forms occur in domestic cats and other felines, which are the definitive hosts and support both schizogony and gametogony.
- Only the asexual forms, trophozoites and tissue cysts are present in other animals, including humans and birds, which are the intermediate hosts.
- All the three forms are infectious to man.

Trophozoites (Tachyzoites)

The trophozoite is **crenate-shaped**, with one end pointed and the other end rounded.

- It measures 3–7 μm in length. The nucleus is ovoid and is situated at the blunt end of the parasite.
- Electron microscopy reveals an **apical complex** at the pointed end (**Fig. 2**).
- The trophozoite stains well with Giemsa stain, the cytoplasm appearing **azure blue** and the nucleus **red** (**Fig. 3**).
- The actively multiplying trophozoite is seen intracellularly in various tissues during early acute phase of infection. Extracellular trophozoites can also be seen in impression smears.
- It can invade any nucleated cell and replicate within cytoplasmic vacuoles by a process called **endogony** (*internal budding*), wherein two daughter trophozoites are formed, each surrounded by a membrane, while still within the parent cell. When the host cell becomes distended with the parasite, it disintegrates, releasing the trophozoites that infect other cells.
- During acute infection, the proliferating trophozoites within host cell may appear rounded and enclosed by the host cell membrane. This is called **pseudocyst** or **colony** and can be differentiated from tissue cysts by staining reactions.

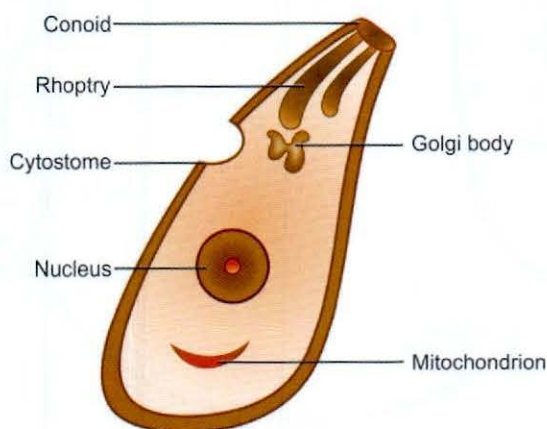


Fig. 2: *Toxoplasma gondii*. Trophozoite (tachyzoite), fine structure seen by electron microscopy

- The **rapidly** proliferating trophozoites in acute infection are called **tachyzoites**.
- The trophozoites are susceptible to drying, freeze-thawing and gastric digestion.

Tissue Cyst

Tissue cysts are the resting form of the parasite.

- They are found during chronic stage of the infection and can be found in the brain (most common site), skeletal muscles and various other organs.
- The cyst wall is eosinophilic and stains with silver, in contrast to the pseudocyst.
- With periodic acid-Schiff (PAS) stain, the cyst wall stains weakly, and the parasites inside are stained deeply. The **slowly** multiplying parasites within the cyst are called **bradyzoites**.
- The cyst is round or oval, 10–20 μm in size and contains numerous bradyzoites. Cysts remain viable in tissue for several years.
- In immunologically normal hosts, the cysts remain silent, but in the immunodeficient subjects, they may get reactivated, leading to clinical disease.
- It is relatively resistant and when the raw or undercooked meat containing the cysts is eaten, infection occurs.
- The cyst wall is disrupted by peptic or tryptic digestion and the released parasites initiate infection by invading intestinal epithelial cells.
- They reach various tissues and organs through blood and lymphatic dissemination.
- Cysts are susceptible to desiccation, freezing, and thawing, and heat above 60°C.

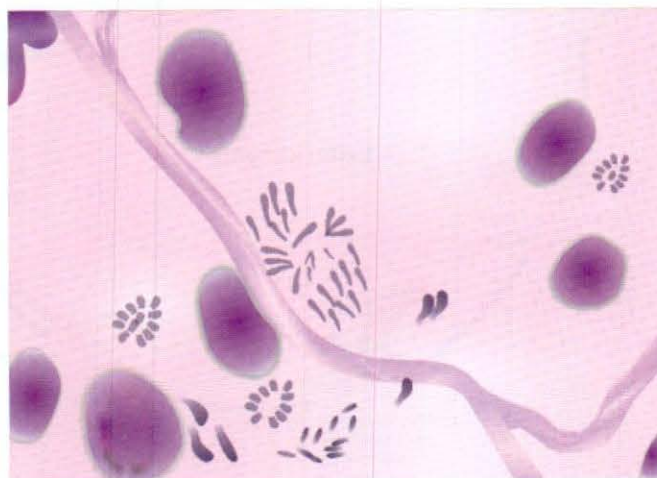

Fig. 3: *Toxoplasma gondii*. Trophozoite grows in tissue culture. Smear shows trophozoites arranged in different patterns—singly, in cluster, or as rosette (Giemsa stain)

Oocyst

Oocysts develop only in **definitive hosts**—in the intestine of **cats** and other felines but not in humans.

- It is oval in shape and measures 10–12 μm in diameter. Each cyst is surrounded by a thick resistant wall.
- The oocysts are formed by sexual reproduction (gametogony).
- Cats shed millions of oocysts per day in feces for about 2 weeks during the primary infection. The freshly passed oocyst is not infective.
- They undergo sporulation in the soil with formation of two sporocysts, each containing four sporozoites. The sporulated oocyst is infective.
- Oocyst is very resistant to environmental conditions and can remain infective in soil for about a year.
- When the infective oocyst is ingested, it releases sporozoites in the intestine, which initiates infection.

Life Cycle

Host: *T. gondii* completes its life cycle in two hosts (**Fig. 4**).

1. **Definitive hosts:** Cats and other felines, in which both sexual and asexual cycles take place.

2. **Intermediate hosts:** Man and other mammals, in which only the asexual cycle takes place.

T. gondii has two types of life cycles:

1. Enteric cycle
2. Exoenteric cycle.

Enteric Cycle (Feline Cycle)

Enteric cycle occurs in **cat** and other definitive hosts (**Fig. 4**).

- Both **sexual** reproduction (gametogony) and **asexual** reproduction (schizogony) occur within the mucosal epithelial cells of the small intestine of the cat.
- Cat acquires infection by ingestion of tissue cysts in the meat of rats and other animals or by ingestion of oocysts passed in its feces.
- The bradyzoites are released in the small intestine and they undergo asexual multiplication (schizogony) leading to formation of merozoites.
- Some merozoites enter extraintestinal tissues resulting in the formation of tissue cysts in other organs of the body.
- Other merozoites transform into male and female gametocytes and sexual cycle (gametogony) begins, with the formation of *microgamete* and *macrogamete*.

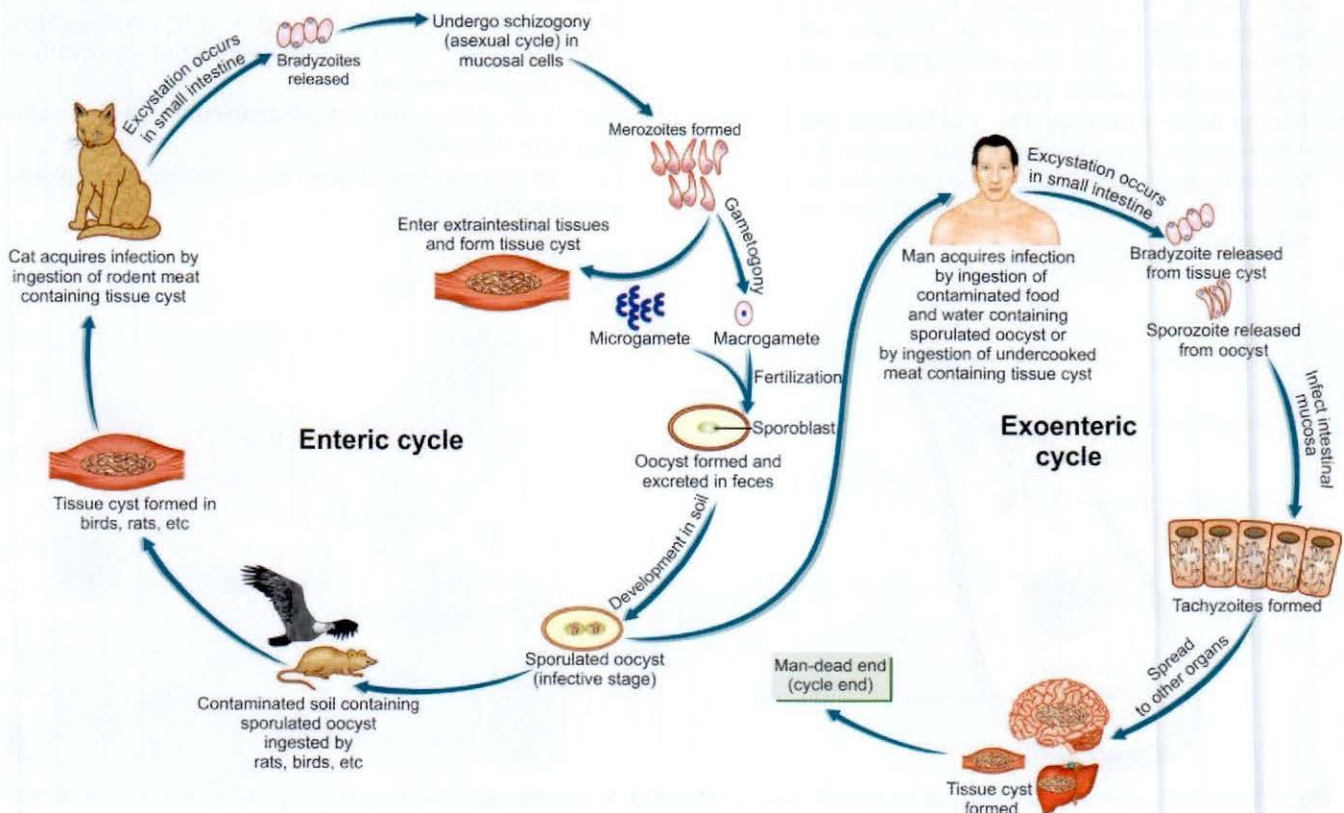


Fig. 4: Life cycle of *Toxoplasma gondii*

- A macrogamete is fertilized by motile microgamete resulting in the formation of an oocyst, which passes through maturation stages (**sporulation**) in the soil after being excreted from host through feces.
- A mature oocyst containing eight sporozoites is the infective form which may be ingested by rats or other mammals to repeat the cycle.

Exoenteric Cycle (Human Cycle)

Exoenteric cycle occurs in humans, mice, rats, sheep, cattle, pigs and birds, which are the intermediate hosts.

- **Humans acquire infection after:**
 - Eating uncooked or undercooked infected meat, particularly lamb and pork containing tissue cysts.
 - Ingestion of mature oocysts through food, water, or fingers contaminated with cat feces directly or indirectly.
 - Intrauterine infection from mother to fetus (*congenital toxoplasmosis*).
 - Blood transfusion or transplantation from infected donors.
- Sporozoites from the oocysts and bradyzoites from the tissue cysts enter into the intestinal *mucosa* and multiply **asexually** and *tachyzoites* are formed (*endodyogeny*).
- Tachyzoites continue to multiply and spread locally by lymphatic system and blood.
- Some tachyzoites also spread to distant extraintestinal organs like brain, eye, liver, spleen, lung and skeletal muscles and form *tissue cysts*. The slowly multiplying forms inside the tissue cysts are known as *bradyzoites*, which remain viable for years.
- The dormant bradyzoites inside the cyst may be reactivated in immune suppression causing renewed infection in the host.
- Human infection is a dead end for the parasite (**Fig. 4**).
- Human toxoplasmosis is a zoonosis.
- The full natural cycle is maintained predominantly by cats and mice.
- Mice eat materials contaminated with oocysts shed in cat's feces. Tissue cysts develop in mice.
- When such mice are eaten by cats, they get infected and again shed oocysts in feces.

Pathogenicity and Clinical Features

The outcome of *Toxoplasma* infection depends on the **immune status** of the infected person.

- Active progression of infection is more likely in immunocompromised individuals. Toxoplasmosis has acquired great importance as one of the major fatal

complications in acquired immunodeficiency syndrome (AIDS).

- Most human infections are *asymptomatic*.
- Clinical toxoplasmosis may be congenital or acquired.

Congenital Toxoplasmosis

Congenital toxoplasmosis results when *T. gondii* is transmitted transplacentally from mother to fetus (**Box 1**).

- This occurs when the mother gets primary toxoplasma infection, whether clinical or asymptomatic, during the pregnancy.
- The risk of fetal infection rises with progress of gestation; from 25%, when the mother acquires primary infection in 1st trimester to 65% in the 3rd trimester. Conversely, the severity of fetal damage is highest, when infection is transmitted in early pregnancy.
- Mothers with chronic or latent *Toxoplasma* infection, acquired earlier, do not ordinarily infect their babies. But in some women with latent or chronic infection, the tissue cyst may be reactivated during pregnancy and liberate trophozoites, which may infect the fetus *in utero*.
- Most infected newborns are **asymptomatic** at birth and may remain so throughout. Some (0.3–1%) develop clinical manifestations of toxoplasmosis within weeks, months and even years after birth.
- The manifestations of congenital toxoplasmosis include chorioretinitis, cerebral calcifications, convulsions, strabismus, deafness, blindness, mental retardation, microcephaly and hydrocephalus.
- A few children are born with manifestations of **acute toxoplasmosis**, which may include fever, jaundice, petechial rashes, microphthalmia, cataract, glaucoma, lymphadenopathy, hepatosplenomegaly, myocarditis, cerebral calcifications and chorioretinitis.

Acquired Toxoplasmosis

- Infection acquired postnatally is mostly asymptomatic.
- The most common manifestation of acute acquired toxoplasmosis is **lymphadenopathy**; the cervical lymph nodes being most frequently affected.
- Fever, headache, myalgia and splenomegaly are often present. The illness may resemble **mild flu** and is self-limited, although the lymphadenopathy may persist.

Box 1: Parasites which can be transmitted from mother to fetus

- *Toxoplasma gondii*
- *Plasmodium* spp.
- *Trypanosoma cruzi*.

- In some cases, there may be a *typhus-like exanthema* with pneumonitis, myocarditis and meningoencephalitis, which may be fatal.

Ocular Toxoplasmosis

Another type of toxoplasmosis is ocular.

- It may present as uveitis, choroiditis, or chorioretinitis.
- Some cases may be so severe that they require enucleation.

Toxoplasmosis in Immunocompromised Patients

Toxoplasmosis is the most serious and often fatal in immunocompromised patients, particularly in AIDS, whether it may be due to reactivation of latent infection or new acquisition of infections.

- In these patients, involvement of brain is most common.
- Clinical manifestations include encephalitis, altered mental state, seizures, cerebellar signs, meningismus and neuropsychiatric manifestations.
- Besides central nervous system involvement, other organs involved are lungs, pancreas, gastrointestinal tract, eyes, heart and liver.
- *Toxoplasma pneumonia* can be confused with *Pneumocystis pneumonia*.

Host Immunity

Host defense against *Toxoplasma* infection involves both humoral (antibody-mediated) and cellular responses. Specific immunoglobulin G (IgG) antibody can lyse extracellular trophozoites, but activated T cells and natural killer cells

appear to be more important in containing the infection and preventing clinical disease.

Laboratory Diagnosis

The diagnosis of acute toxoplasmosis is made mainly by demonstration of trophozoites and cysts in tissue and body fluids and by serology (**Flow chart 1**).

Microscopy

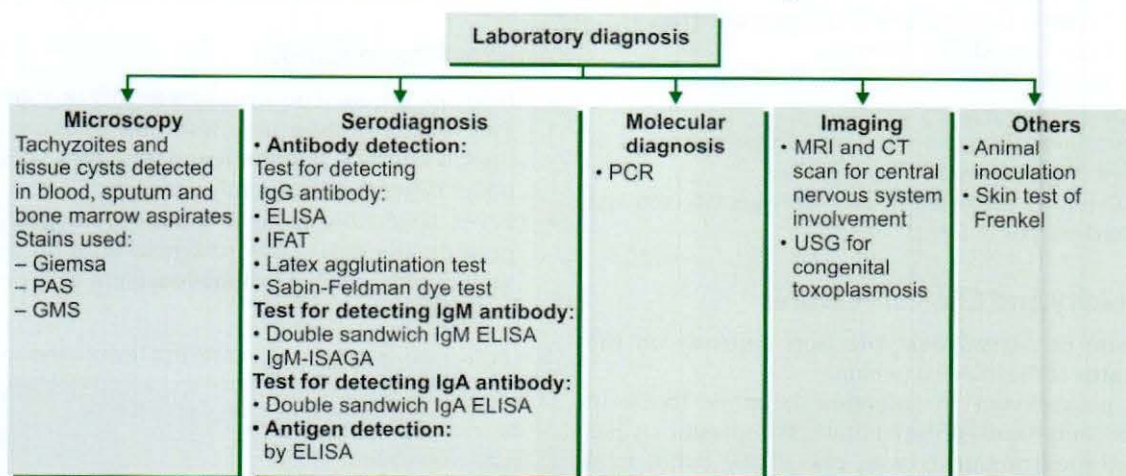
Tachyzoites and tissue cysts can be detected in various specimens like blood, sputum, bone marrow aspirate, cerebrospinal fluid (CSF), amniotic fluid, and biopsy material from lymph node, spleen and brain.

- Smear made from earlier specimens is stained by Giemsa, PAS, or Gomori methenamine silver (GMS) stain.
- Tachyzoites appear as **crenate-shaped** structures with blue cytoplasm and dark nucleus.
- Tachyzoites or cyst can also be demonstrated effectively by fluorescent conjugated antibody technique in tissue biopsy or impression smear.
- Presence of only tissue cysts does not differentiate between active and chronic infection.
- The presence of cysts in placenta or tissues of newborn establishes congenital *Toxoplasma* infection.

Animal Inoculation

Toxoplasma can be isolated by inoculating body fluids, blood, or tissue specimens by intraperitoneal inoculation in mice or

Flow chart 1: Laboratory diagnosis of *Toxoplasma gondii*



Abbreviations: CT, computed tomography; ELISA, enzyme-linked immunosorbent assay; GMS, Gomori methenamine silver; IFAT, indirect fluorescent antibody test; IgM-ISAGA, immunoglobulin M-immunosorbent agglutination assay; MRI, magnetic resonance imaging; PAS, periodic acid-Schiff; PCR, polymerase chain reaction; USG, ultrasonography

in tissue culture. Mice should be examined for *Toxoplasma* in their peritoneal exudate after 7–10 days of inoculation.

Serodiagnosis

Serology is the mainstay for diagnosis of toxoplasmosis.

Antibody detection: Diagnosis of acute infection with *T. gondii* can be made by detection of the simultaneous presence of IgM and IgG antibodies.

- Tests for detecting IgG antibody include:
 - Enzyme-linked immunosorbent assay (ELISA)
 - Sabin-Feldman dye test
 - Indirect fluorescent antibody test (IFAT)
 - Latex agglutination test.
- Positive IgG titer (>1:10) can be detected as early as 2–3 weeks after infection. Peak level of antibody is observed in blood 4–8 weeks after infection.
- A positive IgM antibody titer indicates an **early primary infection**. The serum IgM titer can be measured by double-sandwich IgM ELISA or IgM-immunosorbent agglutination assay (IgM-ISAGA). Both assays are equally specific and sensitive. Negative IgM titer and positive IgG titer indicate **distant infection**.
- The double-sandwich IgA ELISA test is used for detecting congenital infection in newborns.

Antigen detection: Detection of antigen by ELISA indicates **recent** *Toxoplasma* infection.

- In AIDS and other immunocompromised patients, antigen detection is very useful.
- Detection of antigen in amniotic fluid is helpful to diagnose congenital toxoplasmosis.

Skin Test of Frenkel

Diluted toxoplasmin is injected intradermally and delayed positive reaction appears after 48 hours. This test is not very reliable for diagnosis of *Toxoplasma*.

Sabin-Feldman Dye Test

This was the first serological test for *Toxoplasma* antibody to be described by Sabin and Feldman (1948).

Principal: The test is based on specific inhibition by antibody, of the staining of trophozoites by alkaline methylene blue dye.

Technique: Equal volumes of diluted patient's serum are incubated with live trophozoites and normal human serum (accessory factor) for an hour at 37°C. Later, a drop of alkaline methylene blue dye is added to each tube and is examined under microscope. If **less than 50%** of the tachyzoites first take up stain and the cytoplasm remains colorless, the test is considered to be positive. The presence of 90–100% tachyzoites, deeply swollen and stained with blue color, shows

the test to be negative. It denotes the absence of *Toxoplasma* antibodies. The highest dilution of the serum, which inhibits staining up to 50%, is the *titer*.

Limitation: The test is reported to give false-positive reaction in *Sarcocystis*, *Trichomonas vaginalis* and *Trypanosoma lewisi* infections. It cannot differentiate between recent and past infection.

Molecular Methods

Deoxyribonucleic acid (DNA) hybridization techniques and polymerase chain reaction (PCR) are increasingly used to detect *Toxoplasma* from different tissues and body fluids.

- **B₁ gene** of *T. gondii* can be detected by **PCR** of the amniotic fluid in case of congenital toxoplasmosis.

Imaging

Magnetic resonance imaging (MRI) and computed tomography (CT) scan are used to diagnose toxoplasmosis with central nervous system involvement.

- Ultrasonography (USG) of the fetus *in utero* at 20–24 weeks of pregnancy is useful for diagnosis of congenital toxoplasmosis.

Treatment

Congenital Toxoplasmosis

Neonates with congenital infection are treated with oral **pyrimethamine** (1 mg/kg) daily and **sulfadiazine** (100 mg/kg) with folinic acid for 1 year. Systemic corticosteroid may be added to reduce chorioretinitis.

Immunocompetent Patients

Immunologically competent adults and older children, who have only lymphadenopathy, do not require specific therapy unless they have persistent severe symptoms.

- Patients with ocular toxoplasmosis are treated for 1 month with pyrimethamine plus either sulfadiazine or clindamycin (600 mg QID).
- **Folinic acid** should be administered concomitantly to avoid marrow suppressive effect of pyrimethamine.

Immunocompromised Patients

Acquired immunodeficiency syndrome patients who are seropositive for *T. gondii* and have a CD4⁺ T-lymphocyte count below less than 100/μL, should receive **primary prophylaxis** against *Toxoplasma* encephalitis.

- Trimethoprim-sulfamethoxazole is the drug of choice. If trimethoprim-sulfamethoxazole cannot be tolerated by patients, dapsone-pyrimethamine is the recommended alternative drug of choice.

- Prophylaxis against *Toxoplasma* encephalitis should be discontinued in patients who have responded to antiretroviral therapy (ART) and whose CD4⁺ T-lymphocyte count has been above 200/ μ L for 3 months.

Prophylaxis

- Individuals at risk, particularly pregnant women, children and immunocompromised persons should avoid contact with cat and its feces.
- Proper cooking of meal.
- Proper washing of hands and washing of vegetables and fruits before eating.
- Blood or blood products from seropositive persons should not be given and screening for *T. gondii* antibody should be done in all blood banks.

Control

It is difficult to control toxoplasmosis because of wide range of animal reservoirs. Currently, there is no effective vaccine available for humans. A genetically engineered vaccine is under development for use in cats.

KEY POINTS OF *TOXOPLASMA GONDII*

- Obligate intracellular parasite.
- Exists in three forms: (1) trophozoite, (2) tissue cyst, and (3) oocyst.
- *Definitive host*: Cat family (enteric cycle).
- *Intermediate host*: Human (exoenteric cycle).
- Human infection occurs by ingestion of food containing oocyst and tissue cyst.
- Congenital infection can also occur.
- *Clinical features*: Acute encephalopathy, fever, chorioretinitis, lymphadenopathy, myocarditis, hepatosplenomegaly.
- Disseminated infection in AIDS.
- *Diagnosis*: By demonstration of parasite in tissue specimen, ELISA, IFAT, Sabin-Feldman dye test, IgM-ISAGA.
- *Treatment*: Congenital infection is treated with pyrimethamine and sulfadiazine. For primary prophylaxis, trimethoprim-sulfamethoxazole is the drug of choice.

■ *ISOSPORA BELLII*

History and Distribution

Isospora belli is a coccidian parasite which can cause diarrhea in humans.

- It was originally described by Virchow in 1860 but it was named in 1923.
- The name *bellii* (from *bellium* meaning war) was given for its association with war, because several cases of infection

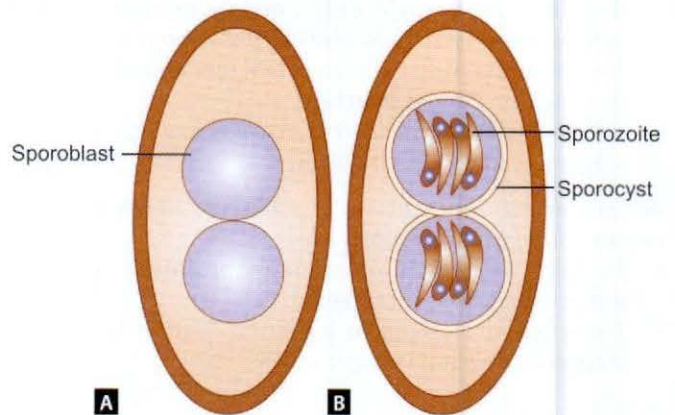
with this parasite were seen among troops stationed in Middle East during the First World War.

- It is more common in tropical and subtropical countries.

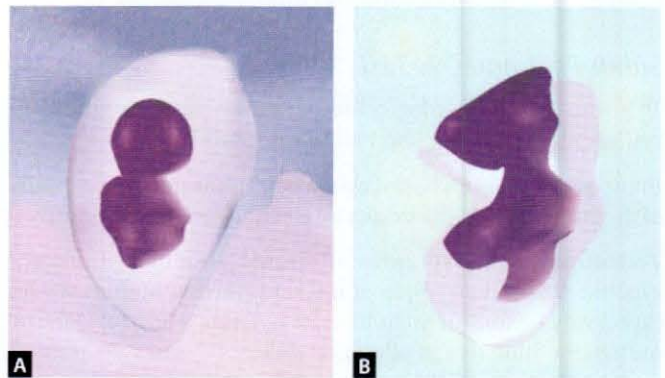
Morphology

Oocysts of *I. belli* are **elongated-ovoid** and measure 25 μ m \times 15 μ m.

- Each oocyst is surrounded by a thin smooth two-layered cyst wall (**Figs 5A and B**).
- Immature oocysts seen in the feces of patients contain two **sporoblasts**.
- The oocysts mature outside the body.
- On maturation, the sporoblast convert into **sporocysts**. Each sporocyst contains four crescent-shaped sporozoites (**Figs 6A and B**).
- The *sporulated oocyst containing eight sporozoites* is the **infective stage** of the parasite.



Figs 5A and B: Oocysts of *Isospora belli*. (A) Immature cyst; and (B) Mature cyst



Figs 6A and B: Oocysts of *Isospora belli*. (A) Oocyst showing two sporoblasts; and (B) Mature oocyst with two sporocysts containing sporozoites

Life Cycle

I. belli completes its life cycle in **one host**.

- Man gets infection by ingestion of food and water contaminated with sporulated oocyst.
- When a sporulated oocyst is swallowed, eight sporozoites are released from the two sporocysts in the small intestine and invade the intestinal epithelial cells.
- In the epithelium, the sporozoites transform into trophozoites, which multiply asexually (**schizogony**) to produce a number of (**merozoites**). The merozoites invade adjacent epithelial cells to repeat asexual cycle.
- Some of the trophozoites undergo sexual cycle (**gametogony**) in the cytoplasm of enterocytes and transform into **macrogametocytes** and **microgametocytes**.
- After fertilization, a **zygote** is formed, which secretes a cyst wall and develops into an **immature oocyst**.
- These immature oocysts are excreted with feces and mature in the soil.
- **Incubation period:** 1–4 days.

Clinical Features

Infection is usually asymptomatic.

- Clinical illness includes abdominal discomfort, mild fever, diarrhea and malabsorption.
- The **diarrhea** is usually watery and does not contain blood or pus and is self-limiting. However, protracted diarrhea, lasting for several years can be seen in immunocompromised persons, particularly in the HIV infected.

Laboratory Diagnosis

Stool Examination

Indirect evidence:

- High fecal fat content.
- Presence of fatty acid crystals in stool.
- Presence of Charcot-Leyden crystals in stool.

Direct evidence: It may be difficult to demonstrate the transparent oocyst in saline preparation of stool.

- Stool concentration techniques may be required when direct wet mount of stools are negative.
- The staining techniques used are **modified Ziehl-Neelsen (ZN)** stain or Kinyoun acid-fast staining of stool smear. In these methods, pink-colored acid-fast large oocyst (>25 µm) can be demonstrated. The stool smear can also be stained by auramine-rhodamine and Giemsa stains.

Duodenal Aspirates

After repeatedly negative stool examinations, duodenal aspirate examination or enterotest can be performed to demonstrate oocyst.

Intestinal Biopsy

Upper gastrointestinal endoscopy may provide biopsy specimens for demonstration of oocysts.

Others

Eosinophilia, which is generally not seen with other enteric protozoan infections, is detectable in case of isosporiasis.

Treatment

- No treatment is indicated in self-limiting infection in immunocompetent persons.
- Immunodeficient patients with diarrhea and excreting oocysts in the feces should be treated with **cotrimoxazole** (trimethoprim-sulfamethoxazole) in a dose of two tablets, four times a day for 10 days followed by two tablets two times a day for 3 weeks.
- For patients intolerant to sulfonamides, pyrimethamine 50–75 mg/day is given.
- Relapses can occur in persons with AIDS and necessitate maintenance therapy with cotrimoxazole one tablet thrice a week.

■ CRYPTOSPORIDIUM PARVUM

History and Distribution

Cryptosporidia were first observed in the gastric mucosal crypts of laboratory mice by Tyzzer in 1907.

- Its importance as a pathogen causing diarrhea in animals was recognized in 1971 and the first case of human infection was reported in 1976.
- *Cryptosporidium* has assumed great importance as a frequent cause of intractable diarrhea, in **AIDS patients** and **immunocompromised subjects**.
- It is worldwide in distribution.
- Two species of *Cryptosporidium*, *C. hominis* and *C. parvum* mostly cause human infections.

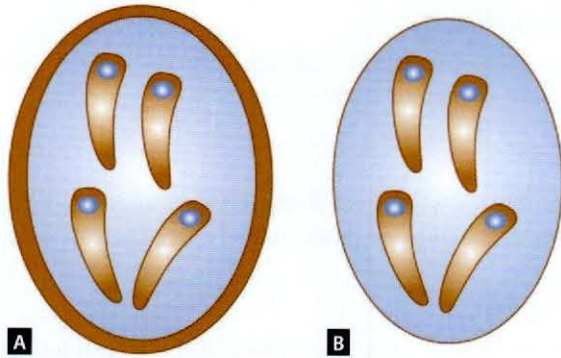
Habitat

C. parvum inhabits the small intestine. It may also be found in stomach, appendix, colon, rectum and pulmonary tree.

Morphology

The **infective form** of the parasite is **oocyst**.

- The oocyst is **spherical** or oval and measures about 5 µm in diameter.
- Oocyst does not stain with iodine and is **acid-fast**.
- The wall of the oocysts is thick, but in 20% cases, wall may be thin. These thin-walled oocysts are responsible for autoinfection.



Figs 7A and B: Oocysts of *Cryptosporidium parvum*. (A) Thick-walled oocyst; and (B) Thin-walled oocyst

- Both thin-walled and thick-walled oocyst contain four crescent-shaped *sporozoites* (Figs 7A and B).
- Oocyst can remain viable in the environment for long periods, as it is very hard and resistant to most disinfectants and temperature up to 60°C.
- It can survive chlorinated water, but sequential application of ozone and chlorine has been found effective in eliminating the cysts.

Life Cycle

The parasite complete its life cycle, sexual and asexual phases in a single host (monoxenous) (Fig. 8).

Suitable Host

Man.

Reservoirs

Man, cattle, cat and dog.

Mode of Transmission

Man acquires infection by:

- Ingestion of food and water contaminated with feces containing oocysts.
- Autoinfection.

Infective Form

Sporulated oocysts.

- The oocyst contains four sporozoites, which are released in the intestine.
- The sporozoites develop into trophozoites within parasitophorous vacuoles in the brush border of the intestine.
- The trophozoites undergo *asexual* multiplication (*schizogony*) to produce *type I meronts*.

- Eight merozoites are released from each type I meront. These merozoites enter adjacent epithelial cells to repeat schizogony or form type II meronts, which undergo gametogony.
- Four merozoites are released from each type II meront. The merozoites enter host cell to form sexual stages—*microgamete* and *macrogamete*.
- After fertilization, the zygote formed develops into the oocyst. The oocyst undergoes sporogony to form sporulated oocyst, which contains four sporozoites. Sporulated oocysts are released into the feces and transmit the infection from one person to another. Some of the oocysts have a thin wall surrounding four sporozoites and are called as *thin-walled oocysts*. These oocysts infect the same host and maintain the cycle of *autoinfection*.
- The oocysts are fully mature on release and are infective immediately without further development (Fig. 8).

Pathogenicity and Clinical Features

- Humans get infection either by ingestion of contaminated food and water with feces or by direct contact with infected animals. Human-to-human transmission can also occur. Incubation period is 2–14 days.
- Clinical manifestations of *C. parvum* infection vary depending upon the immune status of the host.
 - Infection in healthy immunocompetent persons may be asymptomatic or cause a self-limiting febrile illness, with watery diarrhea in conjunction with abdominal pain, nausea and weight loss. It can also cause childhood and traveler's diarrhea, as well as waterborne outbreaks (Box 2).
 - In immunocompromised hosts, especially those with AIDS and CD4⁺ T-cell counts below 100/μL, diarrhea can be chronic, persistent, and remarkably profuse, causing significant fluid and electrolyte depletion, weight loss, emaciation and abdominal pain. Stool volume may range from 1 L/day to 25 L/day. Biliary tract involvement can manifest as right upper quadrant pain, sclerosing cholangitis, or cholecystitis.

Laboratory Diagnosis

Stool Examination

Diagnosis is made by demonstration of the oocysts in feces.

- A direct *wet mount* reveals colorless, **spherical oocyst** of 4–5 μm, containing large and small granules.
- The oocysts are difficult to visualize in unstained wet preparations.
- A number of staining techniques have been employed for demonstration of oocysts of *C. parvum* in the stool specimen. **Modified ZN staining** is the method of choice

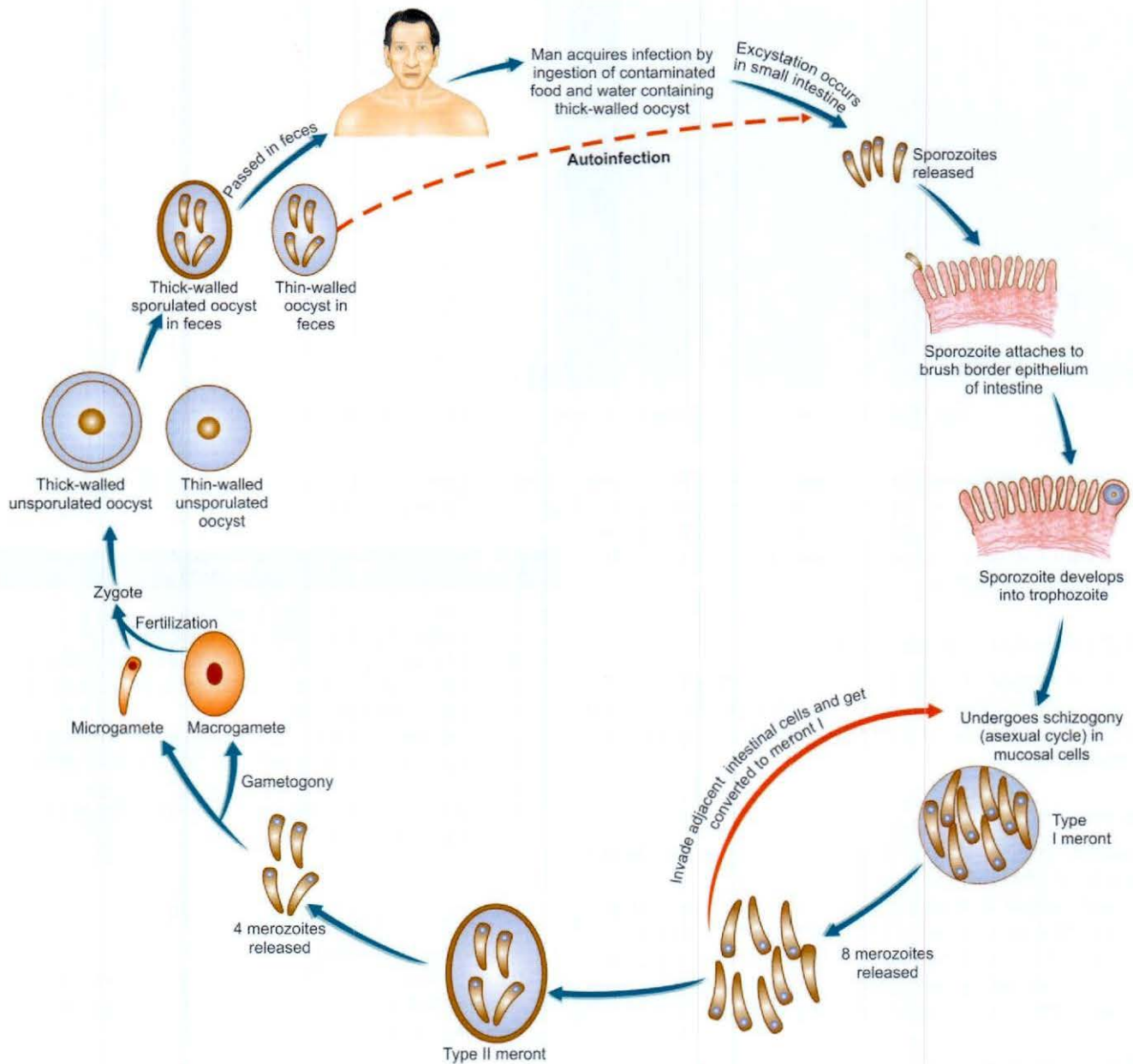


Fig. 8: Life cycle of *Cryptosporidium parvum*

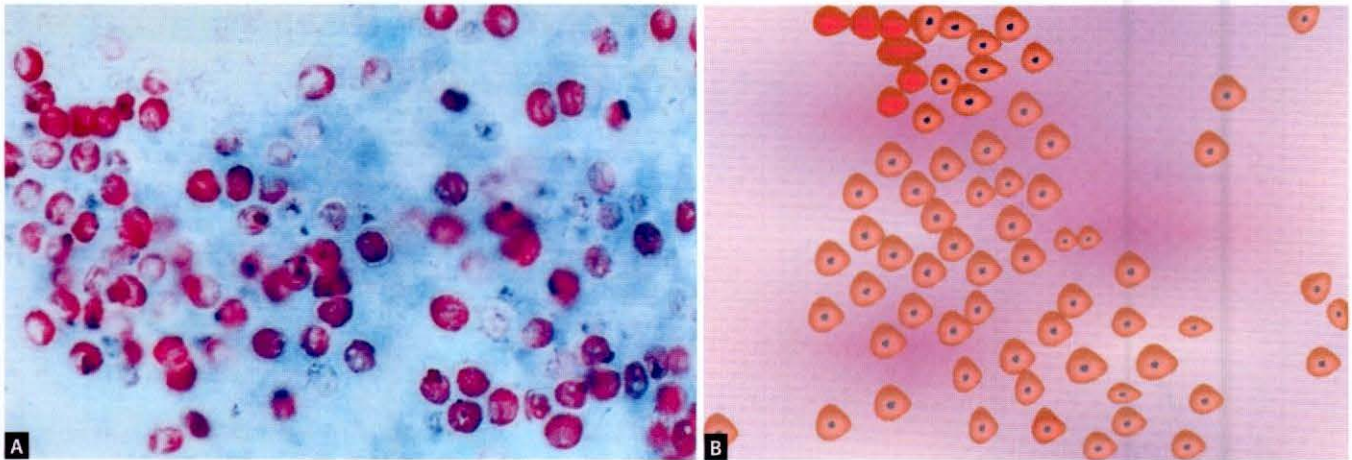
Box 2: Parasites causing traveler's diarrhea

- *Cryptosporidium parvum*
- *Entamoeba histolytica*
- *Giardia lamblia*
- *Cyclospora cayetanensis*

and by this method oocysts appear as red acid-fast spheres, against a blue background (**Figs 9A and B**). Yeast closely resembles oocysts of *C. parvum* in shape and size

but can be differentiated by using acid-fast stain, as they are not acid-fast and appear blue in color. The staining can also be used for demonstration of oocysts in other specimens like sputum, bronchial washing, etc.

- If oocysts, load is less and cannot be demonstrated even after examination of three wet mounts of stool specimen, concentration techniques like Sheather's sugar floatation technique and zinc sulfate floatation technique can be applied.



Figs 9A and B: Oocysts of *Cryptosporidium parvum*. (A) Acid-fast stain; and (B) Ziehl-Neelsen stain

- **Fluorescent staining** with auramine-phenol or acridine orange has also been reported to be a useful technique.
- Definitive identification can be made by **indirect immunofluorescence microscopy** using specific monoclonal antibody.

Histopathological Examination

Cryptosporidium can also be identified by light and electron microscopy at the apical surface of intestinal epithelium from biopsy specimen of the small bowel (jejunum being the preferred site).

Serodiagnosis

Antibody specific to *C. parvum* can be demonstrated within 2 months of acute infection.

- **Anti-oocyst antibody** persists for at least one year and can be demonstrated by ELISA or immunofluorescence.
- An ELISA for detection of *Cryptosporidium* antigens in stools using monoclonal antibody has also been developed and is highly sensitive and specific.

Molecular Diagnosis

For seroepidemiological study, **western blot** technique is employed by using a **17 kDa** and **27 kDa** sporozoite antigen.

- Polymerase chain reaction technique has also been applied to detect viable cysts.

Treatment

No chemotherapeutic agent effective against *Cryptosporidium* has been identified, although **nitazoxanide** (500 mg BD × 3 days) or **paromomycin** may be partially effective in few patients with AIDS. Improvement in immune status with ART can lead to amelioration of cryptosporidiosis. Other treatment

methods include supportive therapy with fluid, electrolytes and nutrient replacement.

KEY POINTS OF *CRYPTOSPORIDIUM PARVUM*

- Sexual and asexual cycle in a single host.
- **Infective form:** Sporulated oocyst in food and water.
- **Clinical features:** Self-limited diarrhea with abdominal pain in healthy persons. Chronic persistent watery diarrhea in immunocompromised hosts.
- **Diagnosis:** Demonstration of round oocyst in stool by direct microscopy, fluorescent microscopy and modified acid-fast stain.
- **Treatment:** Supportive therapy with electrolytes and fluids and early ART in AIDS patients.

■ *CYCLOSPORA CAYETANENSIS*

- It is a coccidian parasite.
- It was first reported from Nepal, where it caused seasonal outbreaks of prolonged diarrhea, with peak prevalence in the warm rainy months.

Morphology

The morphological form found in the feces is an oocyst.

- The oocyst is a nonrefractile sphere, measuring 8–10 μm in diameter.
- It contains two sporocysts.
- Each sporocyst contains two sporozoites. Hence, each sporulated oocyst contains four sporozoites.

Life Cycle

Oocyst shed in feces sporulates outside the host.

- The sporulated oocysts are infectious to humans.

- Man acquires infection by ingestion of food and water contaminated with feces-containing oocysts.
- Excystation of the sporocyst releases crescentic sporozoites measuring $9\ \mu\text{m} \times 1.2\ \mu\text{m}$.
- The sporozoites infect enterocytes in the small intestine.
- The sporozoites develop into unsporulated oocysts, which are excreted in feces.

Pathogenicity and Clinical Features

Infection is through fecal-oral route by ingestion of contaminated water and vegetables.

- Incubation period is of 1–7 days.
- Histopathological examination of the enterocytes shows features of acute and chronic inflammation with blunting and atrophy of villi and hyperplasia of crypts.
- It causes prolonged diarrhea with abdominal pain, low-grade fever and fatigue.
- Like other coccidian parasites the infection is more severe in immunocompromised hosts, especially with AIDS.

Diagnosis

Stool Examination

Diagnosis is by direct wet mount demonstration of oocysts in feces.

- The oocysts can be stained by ZN stain. Oocysts of *Cyclospora* are acid-fast and stain red in color.
- Under ultraviolet illumination, unstained oocysts of *C. cayetanensis* are autofluorescent.

Histopathology

Biopsy specimen from jejunum shows villous atrophy and blunting of villi along with other inflammatory changes.

- The parasite can also be seen in small bowel biopsy material by electron microscopy.

Treatment

Cyclosporiasis is treated with cotrimoxazole (trimethoprim 160 mg/sulfamethoxazole 800 mg) twice daily for 7 days. HIV-infected patients may require long-term suppressive maintenance therapy.

■ BLASTOCYSTIS HOMINIS

Blastocystis hominis was previously considered a yeast, but recently it has been reclassified as a protozoan (Fig. 10).

Habitat

It is a strict anaerobic protozoa found in large intestine of humans.

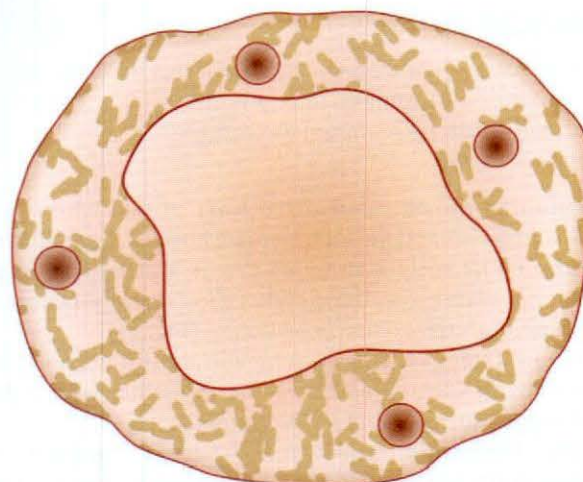


Fig. 10: *Blastocystis hominis*

Morphology

B. hominis has three morphological forms:

1. **Vacuolated form** is usually seen in stool specimen. It measures $8\ \mu\text{m}$ in diameter and is characterized by its large central vacuole, which pushes the cytoplasm and the nucleus to the periphery. It multiplies by binary fission.
2. **Ameboid form** is a polymorphous cell slightly larger than the vacuolated form occasionally seen in the feces. It multiplies by sporulation.
3. **Granular form** measures $10\text{--}60\ \mu\text{m}$ in diameter and is seen exclusively in old cultures.

Pathogenicity and Clinical Features

The pathogenicity of *B. hominis* is doubtful. However, recent studies have shown the parasite to be associated with diarrhea.

- Clinical manifestations include diarrhea, abdominal pain, nausea, vomiting, fever and chills.
- More than half of the patients suffering from infection with *B. hominis* has been found to be immunologically compromised.

Diagnosis

The condition is diagnosed by demonstration of the organism in stool smear stained by Giemsa or iron hematoxylin or trichrome stains.

Treatment

If diarrheal symptoms are prominent, either metronidazole (750 mg thrice a day for 10 days) or iodoquinol (650 mg thrice a day for 20 days) can be used.

■ SARCOCYSTIS

Three species of genus *Sarcocystis* can infect humans:

1. *S. hominis* (transmitted through cattle)
2. *S. suihominis* (transmitted through pig)
3. *S. lindemanni*.

- **Humans** are the **definitive host** of *S. hominis* and *S. suihominis* and the intermediate host for *S. lindemanni*.
- *Sarcocystis* species produce cyst in the **muscle** of the intermediate hosts. These cysts, called **sarcocysts**, contain numerous merozoites (*bradyzoites*) (**Fig. 11**).
- When sarcocyst is eaten by the definitive host, the merozoites are released in the intestine, where they develop into male and female gametes.
- After fertilization, the zygote develops into an oocyst containing two **sporocysts**, each having four sporozoites (**Fig. 12**).
- These oocysts are shed in feces and are ingested by intermediate host.
- In the intermediate hosts, the sporozoites invade the bowel wall and reach the vascular endothelial walls, where they undergo schizogony producing *merozoites* (*tachyzoites*).
- These spread to muscle fibers and develop into sarcocysts.
- **Cow** is the **intermediate host** for *S. hominis*. Human infection is acquired by eating raw or undercooked beef. Oocysts are shed in human feces, which contaminate grass and fodder eaten by cows.

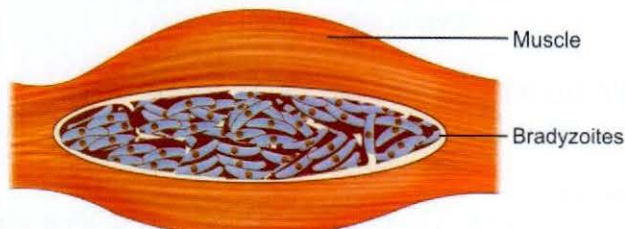


Fig. 11: Sarcocyst

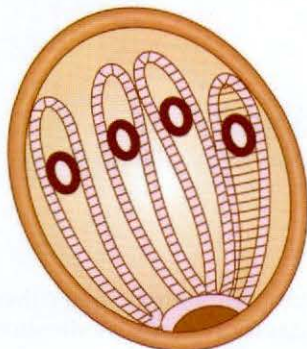


Fig. 12: Oocyst of *Sarcocystis hominis*

- In the case of *S. suihominis*, the **pig** is the intermediate host and human infection is obtained through eating contaminated pork. Human infection with *S. hominis* and *S. suihominis* is related to food habits.
- Humans are the intermediate host in *S. lindemanni*; the definitive host of which is not yet known. It is believed that *S. lindemanni* may not be a single species but a group of as yet unidentified species. Humans apparently get infected by ingestion of oocysts. Sarcocysts develop in the human skeletal muscles and myocardium.

Clinical Features

- **Intestinal sarcocystosis** is usually asymptomatic. Patients may have nausea, abdominal pain and diarrhea.
- **Muscular sarcocystosis** is also usually asymptomatic but may cause muscle pain, weakness, or myositis, depending on the size of the cyst.

Laboratory Diagnosis

Stool Examination

Characteristically sporocysts or occasionally oocysts can be demonstrated in feces of human beings. Species identification is not possible with microscopy.

Muscular Sarcocystosis

Diagnosis can be made by demonstration of sarcocysts in the skeletal muscle and cardiac muscle by biopsy or during autopsy.

Treatment

No specific treatment is available for sarcocystosis.

Prophylaxis

- By avoiding eating raw or undercooked beef or pork.
- By avoidance of contamination of food and drink with feces of cat, dog, or other carnivorous animals.

REVIEW QUESTIONS

1. Describe the life cycle, clinical features and laboratory diagnosis of *Toxoplasma gondii*.
2. Discuss in brief life cycle of *Cryptosporidium parvum*.
3. Write short notes on:
 - a. Congenital toxoplasmosis
 - b. *Cryptosporidium parvum*
 - c. Sabin-Feldman dye test
 - d. Sarcocyst

MULTIPLE CHOICE QUESTIONS

1. Route of transmission of *Toxoplasma*
 - a. Blood
 - b. Feces
 - c. Urine
 - d. None
2. *Toxoplasma gondii* lives inside the
 - a. Lumen of small intestine
 - b. Lumen of large intestine
 - c. Reticuloendothelial cell and many other nucleated cell
 - d. RBC
3. Oocyst of *toxoplasma* is found in
 - a. Cat
 - b. Dog
 - c. Mosquito
 - d. Cow
4. Toxoplasmosis in the fetus can be best confirmed by
 - a. IgM antibodies in the mother
 - b. IgM antibodies in the fetus
 - c. IgG antibodies in the mother
 - d. IgG antibodies in the fetus
5. Intermediate hosts of toxoplasmosis are
 - a. Sheep
 - b. Cattle
 - c. Pigs
 - d. All of the above
6. The following statements regarding congenital toxoplasmosis are correct except
 - a. Most severe form of congenital infection occurs, if it is acquired in 1st trimester
 - b. Chorioretinitis and hydrocephalus are common manifestations in congenital infections
 - c. Presence of *Toxoplasma*-specific IgM antibodies in an infant are suggestive of congenital infection
 - d. Most severe form of congenital infection occur if it is acquired in 3rd trimester
7. Frenkels' skin test is positive in
 - a. Spinal cord compression
 - b. Toxoplasmosis
 - c. Pemphigus
 - d. Pemphigoid
8. In humans, cryptosporidiosis presents as
 - a. Meningitis
 - b. Diarrhea
 - c. Pneumonia
 - d. Asymptomatic infection
9. Which stain demonstrates the oocyst of *Cryptosporidium* best
 - a. Hematoxylin-eosin
 - b. Gram's stain
 - c. Kinyoun modified acid fast stain
 - d. Modified trichrome stain
10. All of the following cause diarrhea except
 - a. *Entamoeba histolytica*
 - b. *Giardia lamblia*
 - c. *Naegleria fowleri*
 - d. *Cyclospora caytanensis*
11. The oval oocyst of *Isospora belli* found in human feces measures
 - a. 1–3 μm \times 5–7 μm
 - b. 3–5 μm \times 8–10 μm
 - c. 5–8 μm \times 10–15 μm
 - d. 22–33 μm \times 10–15 μm
12. Stool in *Isospora belli* infection may contain all except
 - a. High fecal content
 - b. Blood
 - c. Fatty acid crystals
 - d. Charcot-Leyden crystals

Answer

- | | | | | | | |
|------|------|-------|-------|-------|------|------|
| 1. a | 2. c | 3. a | 4. b | 5. d | 6. d | 7. b |
| 8. b | 9. c | 10. c | 11. d | 12. b | | |

Microspora

■ INTRODUCTION

Microsporidia are classified under *Phylum* Microspora. They are minute, intracellular, Gram-positive, spore-forming protozoa.

- Microsporidia are also classified based on their habitat and the infections caused by them (**Table 1**).

■ HISTORY AND DISTRIBUTION

Microsporidia are of historical interest as they are the **first protozoan parasite** to have been successfully studied and controlled by **Louis Pasteur** in 1863, during an investigation of silkworm disease epidemic in France. It was this experience, which led Pasteur to his epochal work on human and animal diseases that formed the foundation of *microbiology*. The

causative agent of the silkworm disease (**pebrine**) is *Nosema bombycis*, a microsporidian parasite.

- Microsporidia had been known as animal parasite for long, but their role as human pathogens was recognized only in the mid 1980s with the spreading of acquired immunodeficiency syndrome (AIDS).
- Some nine genera and 13 species are associated with human disease, particularly in the human immunodeficiency virus (HIV) infected and other immunocompromised subjects.

■ MORPHOLOGY

Microsporidia are **unicellular, obligate intracellular parasite**.

- They reproduce in host cells by producing *spores* (**sporogony**).

Table 1: Classification of Microsporidia

Genus	Species	Habitat and infection caused
<i>Enterocytozoon</i>	<i>E. bieneusi</i>	Small intestine epithelium (leading to diarrhea and wasting). Also found in biliary tract of patients with cholecystitis. Rarely spreads to respiratory epithelium
<i>Encephalitozoon</i>	<i>E. intestinalis</i>	Small intestine epithelium (causing diarrhea and wasting). Also causes sinusitis, cholangitis and bronchiolitis
	<i>E. hellem</i>	Conjunctival and corneal epithelium (causing keratoconjunctivitis). Also causes sinusitis, respiratory tract disease and disseminated infection
	<i>E. cuniculi</i>	<ul style="list-style-type: none"> • Small intestine epithelium (causing diarrhea) • Corneal and conjunctival epithelium (causing keratoconjunctivitis). Rarely, may cause hepatitis and renal infection
	<i>Pleistophora</i>	<i>P. ronneae</i>
<i>Brachiola</i>	• <i>B. vesicularum</i>	• Skeletal muscle (causing myositis)
	• <i>B. conori</i>	• Muscles (smooth and cardiac)
<i>Trachipleistophora</i>	• <i>T. hominis</i>	• Cornea and conjunctival epithelium (leading to keratoconjunctivitis). Also causes myositis
	• <i>T. anthropophtheria</i>	• Brain
<i>Vittaforma</i>	<i>V. corneae</i>	Corneal stroma (causing stromal keratitis)
<i>Nosema</i>	<i>N. ocularum</i>	Corneal stroma (causing stromal keratitis)
<i>Microsporidium</i>	• <i>M. ceylonensis</i>	Corneal stroma (causing stromal keratitis)
	• <i>M. africanum</i>	

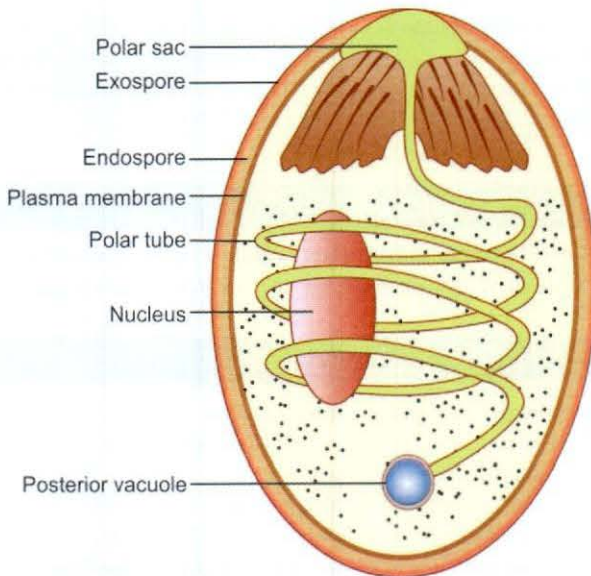


Fig. 1: Microsporidian spore

Box 1: Acid-fast parasitic organisms

- Microsporidia (spore)
- *Cyclospora cayetanensis* (oocyst)
- *Isoospora belli* (oocyst)
- *Cryptosporidium parvum* (oocyst)

- Spores are 2–4 μm in size and oval to cylindrical in shape, with a polar filament or tubule (**Fig. 1**).
- The spores are the *infective stage of microsporidia* and the only stage of life cycle capable of existing outside the host cell.
- The **polar tubule** is an extrusion mechanism for injecting infective spore contents into the host cell.
- Spores are surrounded by thick double-layered cyst wall:
 - Outer layer (**exospore**) is proteinaceous and electron-dense
 - Inner layer (**endospore**) is chitinous and electron-lucent.
- Spores are **Gram-positive** and **acid-fast** (**Box 1**).

■ LIFE CYCLE

Infection in host is probably by ingestion or inhalation of spores.

- In the duodenum, the spore with its nuclear material is injected through the polar tubule into the host cell (**enterocyte**).
- Inside the cell, the microsporidia multiply by repeated binary fission (*merogony*) and produce large number of spores (*sporogony*).

Box 2: Parasites causing opportunistic infections in immunocompromised patients [Human immunodeficiency virus (HIV)–positive cases]

- Microsporidia
- *Cyclospora cayetanensis*
- *Isoospora belli*
- *Cryptosporidium parvum*
- *Toxoplasma gondii*
- *Strongyloides stercoralis*
- *Entamoeba histolytica*

- During sporogony, a thick *spore wall* is formed that provides environmental protection to the cyst.
- The spores are then liberated free from the host cell and infect other cells.

■ CLINICAL FEATURES

They can cause wide range of opportunistic illness in patients with HIV and other immunocompromised diseases (**Box 2**).

- In patients with AIDS, *Enterocytozoon bienersi* and *Encephalitozoon intestinalis* lead to protracted and debilitating diarrhea in 10–40% of cases.
- *E. intestinalis* may also cause sinusitis, cholangitis and bronchiolitis.
- Infection with *Pleistophora* can lead to myositis and *E. hellem* can cause superficial keratoconjunctivitis, sinusitis, respiratory disease and disseminated infection.
- Stromal keratitis associated with trauma has been reported in infections with *Nosema*, *Vittaforma* and *Microsporidium* in immunocompetent patients.

■ LABORATORY DIAGNOSIS

Microscopy

Diagnosis of microsporidiosis is made by demonstration of the spores in stool, urine, cerebrospinal fluid (CSF), or small intestine biopsy specimen.

- The spores can be stained with Gram's stain, periodic acid-Schiff (PAS) stain, or modified trichrome stain.
Note: Spores of microsporidia stain poorly with hematoxylin and eosin stain.
- Although intracellular spores can be visualized by light microscopy, **electron microscopy** is the gold standard.
- Identification of species and genera of microsporidia is based on electron microscopy of spore morphology.
- **Direct fluorescent method** using monoclonal antibody is also used for detection of microsporidia in clinical samples.

Cell Culture

Microsporidia spores can be cultured in monkey and rabbit kidney cells and human fetal lung fibroblast.

Molecular Diagnosis

Microsporidial deoxyribonucleic acid (DNA) can be amplified and detected by polymerase chain reaction (PCR).

TREATMENT

There is no specific and effective drug for microsporidia.

- Intestinal microsporidia may be treated with metronidazole and albendazole.
- For superficial keratoconjunctivitis, topical therapy with fumagillin suspension can be used.

PROPHYLAXIS

Improved personal hygiene and sanitation, especially in immunocompromised persons can prevent microsporidia.

KEY POINTS OF MICROSPORIDIA

- Microsporidia are intracellular spore-forming protozoa, which belong to Phylum Microspora.
- Spores of microsporidia are oval or cylindrical in shape with polar filaments or tubules.
- *Mode of infection:* By ingestion or inhalation of spores.
- *Reproduction:* Microsporidia multiply by both merogony and sporogony.
- *Clinical features:* Protracted and debilitating diarrhea and disseminated infection in eyes, muscles and lungs.
- *Diagnosis:* By demonstration of spores in stool, urine and CSF by Gram's, PAS, or modified trichrome stains. Serological diagnosis includes direct fluorescent antibody test. PCR is also very useful. Electron microscopy is useful in species in identification of microsporidia.

- *Treatment:* There is no specific and effective treatment. Intestinal microsporidia can be treated with metronidazole and albendazole. Topical therapy with fumagillin suspension is used for superficial keratoconjunctivitis.

REVIEW QUESTIONS

1. Describe briefly the laboratory diagnosis of *Microsporidia*.
2. Write short note on the morphology of *Microsporidia* species.

MULTIPLE CHOICE QUESTIONS

1. All are true about *Microsporidia* except
 - a. First protozoan parasite studied by Louis Pasteur
 - b. Causative agent of silk worm disease
 - c. Extracellular spore-forming protozoa
 - d. Cause infection in immunocompromised subjects
2. Laboratory diagnosis of *Microsporidia* can be done by all except
 - a. Modified trichrome stain
 - b. Hematoxylin and eosin-stain
 - c. Direct fluorescent antibody
 - d. Electron microscopy
3. *Enterocytozoon bienewisi* preferentially infects
 - a. Brain
 - b. Conjunctiva
 - c. Kidneys
 - d. Small intestine
4. Microsporidial keratoconjunctivitis is commonly caused by
 - a. *Enterocytozoon bienewisi*
 - b. *Vittaforma*
 - c. *Encephalitozoon hellem*
 - d. *Encephalitozoon intestinalis*

Answer

1. c 2. b 3. d 4. c

Balantidium Coli

INTRODUCTION

Balantidium coli belongs to the Phylum Ciliophora and Family Balantiididae.

- It is the **only ciliate protozoan** parasite of humans.
- It is the **largest protozoan** parasite of humans.
- Largest protozoan parasite residing in the large intestine of man: *Balantidium coli*.

HISTORY AND DISTRIBUTION

It was first described by Malmsten in 1857, in the feces of dysenteric patients.

- It is present worldwide, but the prevalence of the infection is very low.
- The most endemic area is New Guinea, where there is a close association between man and pigs.

HABITAT

B. coli resides in the **large intestine** of man, pigs and monkeys.

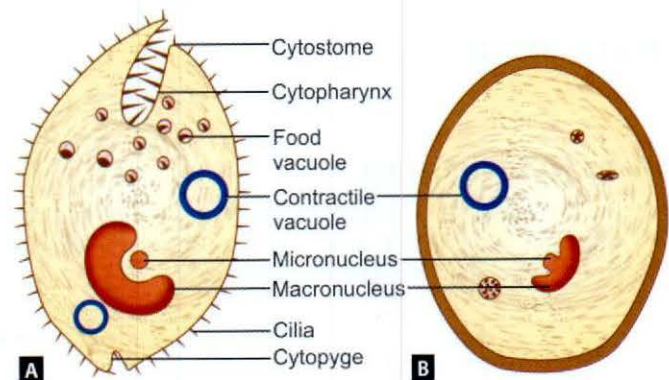
MORPHOLOGY

B. coli occurs in two stages: (1) trophozoite and (2) cyst (Figs 1A and B).

Trophozoite

The trophozoite lives in the large intestine, feeding on cell debris, bacteria, starch grains and other particles.

- The trophozoite is actively motile and is invasive stage of the parasite found in dysenteric stool.
- It is a large **ovoid cell**, about 60–70 μm in length and 40–50 μm in breadth. Very large cells, measuring up to 200 μm are sometimes seen.
- The cell is enclosed within a delicate pellicle showing longitudinal striations.
- The motility of trophozoite is due to the presence of short delicate cilia over the entire surface of the body.



Figs 1A and B: Morphology of *Balantidium coli*.
(A) Trophozoites; and (B) Cyst

- Its anterior end is narrow and posterior end is broad.
- At the anterior end, there is a groove (*peristome*) leading to the mouth (*cytostome*), and a short funnel-shaped gullet (*cytopharynx*).
- Posteriorly, there is a small anal pore (*cytopyge*).
- The cilia around the mouth are larger (*adoral cilia*).
- The cell has two nuclei: (1) a large kidney-shaped **macronucleus**, and (2) lying in its concavity a small **micronucleus**.
- The cytoplasm has one or two contractile vacuoles and several food vacuoles.

Cyst

The cyst is **spherical** in shape and measures 40–60 μm in diameter.

- It is surrounded by a thick and transparent double-layered wall.
- The cytoplasm is granular. Macronucleus, micronucleus and vacuoles are also present in the cyst.
- The cyst is the **infective stage** of *B. coli*.
- It is found in chronic cases and carriers.

■ LIFE CYCLE

B. coli passes its life cycle in one host only (**monoxenous**).

Natural Host

Pig.

Accidental Host

Man.

Reservoirs

Pig, monkey and rat.

Infective Form

Cyst.

Mode of Transmission

- Balantidiasis is a zoonosis. Human beings acquire infection by ingestion of food and water contaminated with feces containing the cysts of *B. coli*.

- Infection is acquired from pigs and other animal reservoirs or from human carriers.
- Once the cyst is ingested, excystation occurs in the small intestine (**Fig. 2**).
- From each cyst, a single trophozoite is produced which migrates to large intestine.
- Liberated trophozoites multiply in the large intestine by **transverse binary fission**. Sexual union by **conjugation** also occurs infrequently, during which reciprocal exchange of nuclear material takes place between two trophozoites enclosed within a single cyst wall.
- Encystation** occurs as the trophozoite passes down the colon or in the evacuated stool. In this process, the cell rounds up and secretes a tough cyst wall around it.
- The cysts remain viable in feces for a day or 2 and may contaminate food and water, thus it is transmitted to other human or animals.

■ PATHOGENESIS

In a healthy individual, *B. coli* lives as *lumen commensal* and is **asymptomatic**.

- Clinical disease occurs only when the resistance of host is lowered by predisposing factors such as malnourishment,

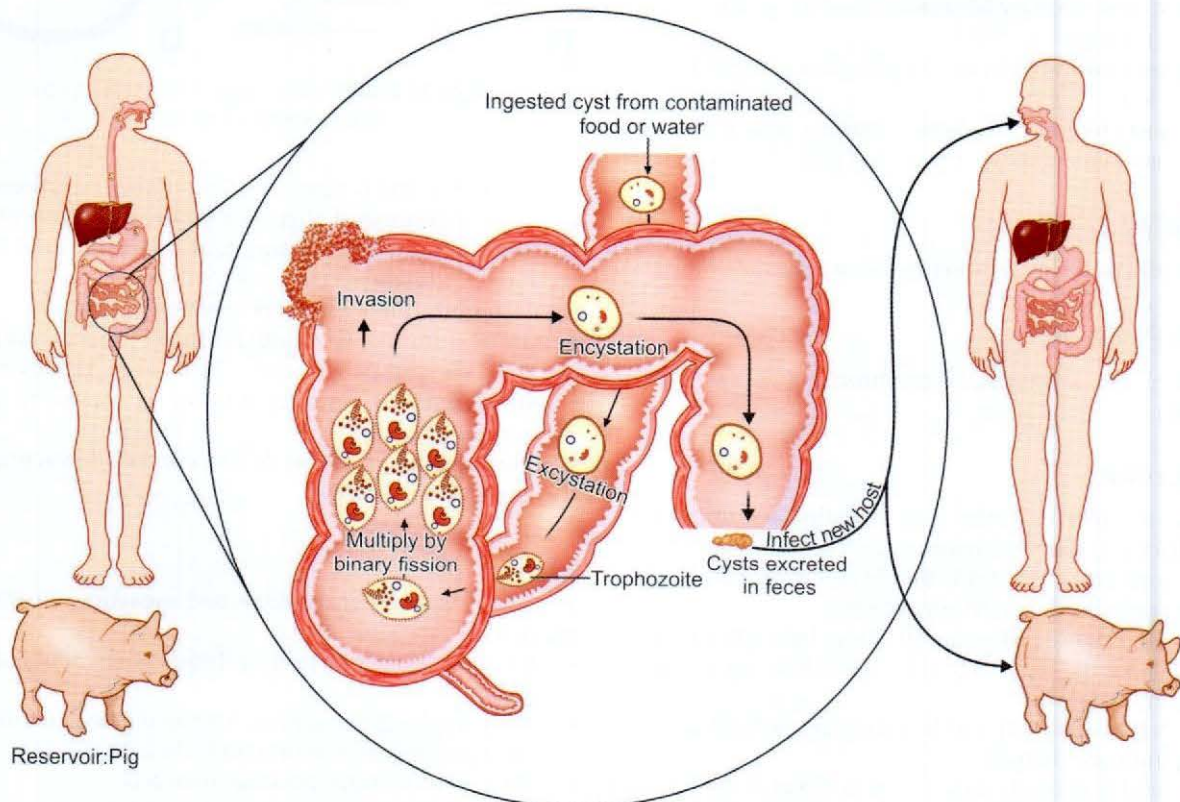


Fig. 2: Life cycle of *Balantidium coli*

alcoholism, achlorhydria, concurrent infection by *Trichuris trichiura*, or any bacterial infection.

- Clinical disease results when the trophozoites burrow into the intestinal mucosa, set up colonies and initiate inflammatory reaction. This leads to mucosal ulcers and submucosal abscesses, resembling lesions in amebiasis.
- Unlike *E. histolytica*, *B. coli* does not invade liver or any other extraintestinal sites.

■ CLINICAL FEATURES

Most infections are asymptomatic.

- Symptomatic disease or **balantidiasis** resembles amebiasis causing diarrhea or frank dysentery with abdominal colic, tenesmus, nausea and vomiting.
- *Balantidium* ulcers may be secondarily infected by bacteria.
- Occasionally, intestinal perforation peritonitis and even death may occur.
- Rarely, there may be involvement of genital and urinary tracts.
- In chronic balantidiasis, patients have diarrhea alternating with constipation.

■ LABORATORY DIAGNOSIS

Stool Examination

Diagnosis of *B. coli* infection is established by demonstration of trophozoites and cysts in feces.

- Motile trophozoites occur in diarrheic feces and cysts are found in formed stools.
- The trophozoites can be easily recognized by their large size, macronucleus and rapid-revolving motility.
- The cysts can also be recognized in the formed stools by their round shape and presence of large macronucleus.

Biopsy

When stool examination is negative, biopsy specimens and scrapings from intestinal ulcers can be examined for presence of trophozoites and cysts.

Culture

B. coli can also be cultured *in vitro* in **Locke's egg albumin** medium or NIH polyxenic medium such as *Entamoeba histolytica*, but it is rarely necessary (**Box 1**).

■ TREATMENT

Tetracycline is the drug of choice and is given 500 mg, four times daily for 10 days. Alternatively, doxycycline can be

Box 1: Parasites which can be cultured in laboratory

- *Balantidium coli*
- *Entamoeba histolytica*
- *Acanthamoeba* spp.
- *Giardia lamblia*
- *Trichomonas vaginalis*
- *Trypanosoma* spp.
- *Leishmania* spp.

given. Metronidazole and nitroimidazole have also been reported to be useful in some cases.

■ PROPHYLAXIS

- Avoidance of contamination of food and water with human or animal feces.
- Prevention of human-pig contact.
- Treatment of infected pigs.
- Treatment of individuals shedding *B. coli* cysts.

KEY POINTS OF BALANTIDIUM COLI

- It is the only ciliate parasite of humans.
- Largest protozoan parasite residing in large intestine.
- It occurs in two stages: (1) trophozoite and (2) cyst.
- Trophozoite is oval-shaped with a slightly pointed anterior end with a groove, peristome leading to the mouth, cytostome. Rounded posterior end has a small anal pore, cytopygge and has a large kidney-shaped macronucleus and small micronucleus.
- **Cyst:** It is the infective stage of the parasite.
- **Mode of infection:** Infection is acquired from pigs and other animals by ingestion of cysts in contaminated food and drink.
- Infection leads to mucosal ulcers and submucosal abscess in intestine.
- **Clinical features:** Most infections are asymptomatic. In mild infections, it causes diarrhea, abdominal colic, tenesmus, nausea and vomiting.
- **Diagnosis:** Based on demonstration of trophozoites and cysts in feces and examination of biopsy specimens and scrapings from intestinal ulcers.
- **Treatment:** Tetracycline is the drug of choice.
- **Prophylaxis:** Avoiding contamination of food and water and treatment of infected pigs and persons.

REVIEW QUESTIONS

1. Write short notes on the morphology of *Balantidium coli* along with suitable illustration.
2. Discuss briefly the life cycle and laboratory diagnosis of *Balantidium coli*.

MULTIPLE CHOICE QUESTIONS

1. Largest protozoal parasite is

- a. *Entamoeba histolytica*
- b. *Trichomonas vaginalis*
- c. *Leishmania donovani*
- d. *Balantidium coli*

2. The infective form of *Balantidium coli* is

- a. Tachyzoites
- b. Cyst
- c. Sporozoite
- d. Trophozoite

3. Which of the following acts as the main reservoir of *Balantidium coli* infection

- a. Man
- b. Monkey
- c. Pig
- d. Cow

4. Drug of choice for treating balantidiasis

- a. Doxycycline
- b. Tetracycline
- c. Metronidazole
- d. Pentamidine

Answer

1. d 2. b 3. c 4. b

Helminths: General Features

■ INTRODUCTION

The helminthic parasites are **multicellular** (metazoa) **bilaterally symmetrical** animals having three germ layers (*triploblastic metazoa*) and belong to the kingdom Metazoa.

- The term *helminth* (Greek *helmins-worm*) originally referred to intestinal worms, but now comprises many other worms, including tissue parasites as well as many free-living species.
- Helminths, which occur as parasite in humans belong to two phyla (**Table 1**):
 1. **Phylum Platyhelminthes** (*flatworms*): It includes two classes:
 - i. **Class: Cestoda** (tapeworms)
 - ii. **Class: Trematoda** (flukes or digeneans)
 2. **Phylum Nematelminthes**: It includes class Nematoda and two subclasses:
 - i. **Subclass: Adenophorea** (Aphasmidia)
 - ii. **Subclass: Secernentea** (Phasmidia).
- The differences between cestodes, trematodes and nematodes have been summarized in **Table 2**.

■ PHYLUM PLATYHELMINTHES

The Platyhelminthes are **tape-like**, dorsoventrally flattened worms.

- They either lack alimentary canal (as in cestodes) or their alimentary canal is incomplete, lacking an anus (as in trematodes).

Table 1: General features of helminths

	<i>Helminths</i>	
	<i>Nematoelminthes (Nematode)</i>	<i>Platyhelminthes (cestode, trematode)</i>
• Body	Elongated, cylindrical, unsegmented	Dorsoventrally flated leaf like or tape like segmented or unsegmented
• Sex	Separate (diecious)	Mostly hermaphrodite except schistosomes (diecious)
• Body cavity	Present	Absent
• Alimentary canal	Complete	Incomplete or absent

Table 2: Differences between cestodes, trematodes and nematodes

	<i>Cestodes</i>	<i>Trematodes</i>	<i>Nematodes</i>
<i>Shape</i>	Tape-like, segmented	Leaf-like unsegmented	Elongated, cylindrical, unsegmented
<i>Head end</i>	Suckers present; some have attached hooks	Suckers are present but no hooks	Hooks and sucker absent. Well-developed buccal capsule with teeth or cutting plates seen in some species
<i>Alimentary canal</i>	Absent	Present but incomplete, no anus	Complete with anus
<i>Body cavity</i>	Absent, but inside is filled with spongy undifferentiated mesenchymatous cells, in the midst of which lie the viscera	Same as cestodes	Present and known as <i>pseudocoel</i> . Viscera remains suspended in the pseudocoel
<i>Sex</i>	Not separate: Hermaphrodite (monoecious)	Not separate: Hermaphrodite except <i>Schistosoma</i>	Separate (diecious)
<i>Life cycle</i>	Requires two host except <i>Hymenolepis</i> (one host) and <i>Diphyllobothrium</i> (three host)	Requires three host except schistosomes (two host)	Requires one host except filarial worms (two host) and <i>Dracunculus</i> (two host)

- Body cavity is absent, viscera is suspended in gelatinous matrix.
- They are mostly *hermaphrodites* (*monoecious*).
- Phylum platyhelminthes includes two classes:
 1. **Class: Cestoda**
 2. **Class: Trematoda.**

Class Cestoda

Cestodes have tape-like, **dorsoventrally flattened**, segmented bodies.

- They do not possess an alimentary system.
- The head carries suckers and some also have hooks.
- They possess scolex, neck and proglottids.
- They are monoecious and body cavity is absent.
- They are oviparous.

Class Trematoda

Trematodes have flat or fleshy, **leaf-like** unsegmented bodies.

- The alimentary canal is present but is incomplete, i.e. without an anus.
- They possess suckers but no hooks.
- The sexes are separate in the schistosomes, while the other flukes are hermaphroditic.
- They are **oviparous**.

■ PHYLUM NEMATHELMINTHES (NEMATODA)

Nematodes are elongated, **cylindrical** worms with an unsegmented body.

- They possess a relatively well-developed complete alimentary canal, with an anus.
- Body cavity is present.
- The head does not have suckers or hooks, but may have a buccal capsule with teeth or cutting plates.
- The sexes are separate (*diecious*).
- They are either **oviparous** or **larviparous**.

■ IMPORTANT FEATURES OF HELMINTHS

Adult Worms

Helminths have an outer protective covering, the **cuticle** or **integument**, which may be tough and armed with spines or hooks. The cuticle of live helminths is resistant to intestinal digestion.

- The mouth may be provided with teeth or cutting plates. Many helminths possess suckers or hooks for attachment to host tissues.
- They do not possess organs of locomotion, but in some species the suckers assist in movement.
- **Locomotion** is generally by muscular contraction and relaxation.

- Many helminths have a primitive nervous system.
- The excretory system is better developed.
- The greatest development is seen in the reproductive system. Helminths may be *monoecious* (with functioning male and female sex organs in the same individual) or *diecious* (the two sexes, male and female, separate). In the hermaphroditic helminths, both male and female reproductive systems are present in the same worm and self-fertilization as well as *cross-fertilization* takes place (e.g. *Taenia solium*). In the diecious species, males and females are separate, the male being smaller than the female (e.g. *Ascaris lumbricoides*). Rarely, the female is *parthenogenic*, being able to produce fertile eggs or larvae without mating with males (e.g. *Strongyloides*).

Eggs

The *eggs* or *larvae* are produced in enormous numbers—as many as 200,000 or more per female per day.

Various helminths have distinct morphology of eggs, which can be used to differentiate the helminths (discussed in the respective chapters).

Larval Forms

There are various larval forms of helminths found in man and other hosts. These forms are as follows:

- **Cestodes:** The various larval forms are cysticercus, coenurus, coracidium, cysticercoid, proceroid, hydatid cyst and plerocercoid forms.
- **Trematodes:** The various larval forms are miracidium, cercaria, redia, metacercaria and sporocyst.
- **Nematodes:** The various larval forms are microfilaria, filariform larva and rhabditiform larva.

Multiplication

Helminths differ from protozoans in their inability to multiply in the body of the host. Protozoans multiply in the infected person, so that disease could result from a single infection. But helminths, apart from very rare exceptions, do not multiply in the human body, therefore, a single infection does not generally leads to disease. Heavy worm load follows multiple infections. Sometimes, multiplication occurs within larval forms in Platyhelminthes.

Life Cycle

- **Cestodes:** They complete their life cycle in **two different** hosts, except *Hymenolepis nana*, which completes its life cycle in a single host and *Diphyllobothrium latum* which completes its life cycle in three hosts.
- **Trematodes:** They complete their life cycle in **one definitive** host (man) and **two intermediate** hosts.

Fresh water snail or mollusc act as first intermediate host and fish or crab act as second intermediate host except schistosomes which require two hosts: (1) one definitive host (man) and (2) other intermediate host (snail).

- **Nematodes:** Nematodes require **only one** host to complete their life cycle **except** filarial nematodes and *Dracunculus medinensis*, which complete their life cycle in two hosts.
- **Pathogenicity:** The pathological lesions in helminthic diseases are due to direct damage caused by helminths or due to indirect damage by host response, for example allergic response of the host to the helminths. Many helminths cause malnutrition of the host. Malnutrition interferes with antibody production.

ZOOLOGICAL CLASSIFICATION OF HELMINTHS

Phylum Platyhelminthes

Class Trematoda

- Blood flukes (sexes separate, infection by cercarial penetration).
 - **Family:** Schistosomatidae (schistosomes)
 - ♦ **Genus:** *Fasciola, Fasciolopsis*
- Hermaphroditic flukes (bisexual, infection by ingestion of cercariae).
 - **Family:** Fasciolidae (large flukes, cercariae encyst on aquatic vegetation)
 - ♦ **Genus:** *Fasciola, Fasciolopsis*
 - **Family:** Paramphistomatidae (large ventral sucker posteriorly)
 - ♦ **Genus:** *Gastrodiscoides*
 - **Family:** Echinostomatidae (collar of spines behind oral sucker, cercariae encyst in mollusc or fish)
 - ♦ **Genus:** *Echinostoma*
 - **Family:** Triglotremitidae (testes side-by-side behind ovary, cercariae encyst in Crustacea)
 - ♦ **Genus:** *Paragonimus*
 - **Family:** Opisthorchidae (testes in tandem behind ovary, cercariae encyst in fish)
 - ♦ **Genus:** *Clonorchis, Opisthorchis*
 - **Family:** Dicrocoelidae (testes in front of ovary, cercariae encyst in insects)
 - ♦ **Genus:** *Dicrocoelium*
 - **Family:** Heterophyidae (minute flukes, cercarial encyst in fish)
 - ♦ **Genus:** *Heterophyes, Metagonimus*.

Class Cestoda

- **Order:** Pseudophyllidea (scolex has grooves)
 - **Genus:** *Diphyllobothrium*
- **Order:** Cyclophyllidea (scolex has suckers)
 - **Family:** Taeniidae (proglottid longer than broad, numerous testes, one genital pore, larva in vertebrates)
 - ♦ **Genus:** *Taenia, Multiceps, Echinococcus*
 - **Family:** Hymenolepididae (transverse proglottids, one genital pore, larva in insects)
 - ♦ **Genus:** *Hymenolepis*
 - **Family:** Dilepidiidae (two genital pores)
 - ♦ **Genus:** *Dipylidium*.

Phylum Nematelminthes

It includes class Nematoda which is further divided into:

- **Subclass:** Adenophorea or Aphasmdia (no phasmids, no caudal papillae in male)
- **Subclass:** Secernentea or Phasmidia (phasmids present, numerous caudal papillae).

Detailed classification of class Nematodes is given in Chapter 13.

KEY POINTS OF HELMINTHS

- Helminths are multicellular and bilateral symmetrical parasite.
- Helminths are divided into two broad phyla—the cylindrical worms belonging to phylum Nematohelminthes (class Nematoda) and flat tape or leaf like helminths belonging to phylum platyhelminthes (class Cestoda and Trematoda).
- Sexes are separate in Nematodes. Cestodes and trematodes are hermaphrodites.
- Trematodes are cestodes require two or three hosts. Nematodes requires one host except filarial worms which require two host.

REVIEW QUESTIONS

1. **Short notes on:**
 - a. General features of helminths
 - b. Phylum Nematoda
2. **Differentiate between:**
 - a. Trematodes and nematodes
 - b. Cestodes and nematodes

MULTIPLE CHOICE QUESTIONS

1. Digestive tract is completely absent in
 - a. Trematodes
 - b. Cestodes
 - c. Nematodes
 - d. All of the above
2. Sexes are always separate in
 - a. Cestodes
 - b. Trematodes
 - c. Nematodes
 - d. None of the above
3. Nematodes are differentiated from other worms by the following except
 - a. Absent fragmentation
 - b. Flat or fleshy leaf-like worm
 - c. Separate sexes
 - d. Cylindrical body
4. Which of the following worm requires two intermediate host
 - a. *Taenia saginata*
 - b. *Diphyllobothrium latum*
 - c. *Hymenolepis nana*
 - d. *Echinococcus granulosus*
5. Which of the following statement is true in respect to trematodes
 - a. Dorsoventrally flattened
 - b. Intermediate host is snail
 - c. Hermaphrodite except schistosomes
 - d. All of the above

Answer

1. b 2. c 3. b 4. b 5. d

Cestodes: Tapeworms

■ INTRODUCTION

Cestodes (Greek *kestos*—*girdle* or *ribbon*) are multi-segmented, dorsoventrally flattened tape-like worms whose sizes vary from a few millimeters to several meters. The adult worms are found in the small intestine of humans.

■ CLASSIFICATION OF CESTODES

Systemic Classification

Cestodes belong to Phylum **Platyhelminthes** and class Cestoidea. The class Cestoidea includes two orders:

1. Pseudophyllidea
2. Cyclophyllidea

For detailed classification see **Table 1**.

Classification of Cestodes Based on the Form of Parasite Important to Man

The detailed classification is given in **Table 2**.

■ TAPEWORMS: GENERAL CHARACTERISTICS

Adult Worms

- The adult worm consists of three parts:
 - Head (scolex)
 - Neck
 - Trunk (strobila) (**Figs 1A to D**).

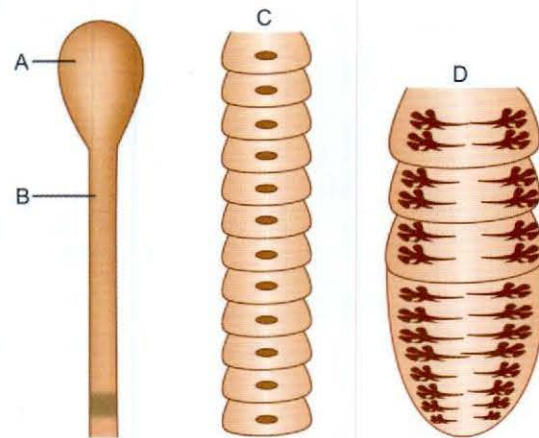
Head (Scolex)

It is the organ of attachment to the intestinal mucosa of the definitive host, human or animal (**Figs 1A to D**).

- In parasites of the order Cyclophyllidea, the scolex possesses **four suckers** (or **acetabula**). In some Cyclophyllidea like *Taenia solium*, scolex has an apical

Table 1: Classification of medically important Cestodes

Order	Family	Genus
Pseudophyllidea	Diphyllobothriidae	• <i>Diphyllobothrium</i> • <i>Spirometra</i>
Cyclophyllidea	Taeniidae	• <i>Taenia</i> • <i>Echinococcus</i>
	Hymenolepididae	<i>Hymenolepis</i>
	Dipylidiidae	<i>Dipylidium</i>



Figs 1A to D: Tapeworm. (A) Scolex or head; (B) Neck, leading to the region of growth below, showing immature segments; (C) Mature segments; and (D) Gravid segments filled with eggs

protrusion called as the **rostellum**. The rostellum may or may not be armed with hooks.

- In parasites of the order Pseudophyllidea, the scolex does not possess suckers but possesses a pair of longitudinal grooves called as **bothria**, by which it attaches to the intestine of the host.

Table 2: Classification of Cestodes based on the form of parasite important to man

Order	Adult worm seen in human intestine	Larval stage seen in humans
Pseudophyllidea	<i>Diphyllobothrium latum</i> , the fish tapeworm	<ul style="list-style-type: none"> • <i>Spirometra mansoni</i> • <i>Spirometra theileri</i> • <i>Spirometra erinacei</i> (larval stage causing sparganosis)
Cyclophyllidea	<ul style="list-style-type: none"> • <i>Taenia saginata</i>, the beef tapeworm • <i>Taenia solium</i>, the pork tapeworm • <i>Hymenolepis nana</i>, the dwarf tapeworm • <i>Hymenolepis diminuta</i>, the rat tapeworm (rare) • <i>Dipylidium caninum</i>, the double-pored dog tapeworm (rare) 	<ul style="list-style-type: none"> • <i>Taenia solium</i>, the pork tapeworm (larval form can cause cysticercus cellulosae) • <i>Echinococcus granulosus</i>, the dog tapeworm (larval form causes hydatid disease in man) • <i>Echinococcus multilocularis</i> (larval stage causes alveolar or multilocular hydatid disease) • <i>Multiceps multiceps</i> and other species (larval stage may cause coenurosis in man)













	<i>Taenia solium</i>	<i>Taenia saginata</i>	<i>Hymenolepis nana</i>	<i>Hymenolepis diminuta</i>	<i>Diphyllobothrium latum</i>	<i>Echinococcus granulosus</i>
Heads						
Proglottids	4 suckers 2 rows of hooks	4 suckers No hooks	4 suckers single row of 20–30 hooks	4 suckers No hooks	2 Suctorial grooves or bothria, no suckers, No hooks	4 suckers 2 rows of hooks
						
	Longer than broad 7–12 uterine branches on each side	Longer than broad 15–30 uterine branches on each side	Broader than long	Broader than long	Broader than long Uterus coiled	Longer than broad

Fig. 2: Differences between heads and proglottids of various Cestodes

Neck

It is the part, immediately behind the head and is the region of growth from where the segments of the body (proglottids) are being generated continuously.

Trunk (Strobila)

The trunk also called as **strobila** is composed of a chain of **proglottids** or **segments** (Figs 1A to D).

- The proglottids near the neck, are the young *immature* segments, behind them are the *mature* segments, and at the hind end, are the *gravid* segments.
- Tapeworms are **hermaphrodites** (*monoecious*) and every mature segment contains both male and female

sex organs. In the immature segments, the reproductive organs are not well-developed. They are well-developed in the mature segments. The gravid segments are completely occupied by the uterus filled with eggs.

- Tapeworms do not have a body cavity or alimentary canal.
 - Rudimentary excretory and nervous systems are present.
- The differences between heads and proglottids of various Cestodes have been illustrated in **Figure 2**.

Eggs

The eggs of Cyclophyllidea and Pseudophyllidea are different from each other (**Table 3**).

Table 3: Differences between eggs of Orders Cyclophyllidea and Pseudophyllidea

Cyclophyllidean egg	Pseudophyllidean egg
• Covered by two layers: (1) egg shell and (2) embryophore	• Covered by one layer: egg shell
• Spherical	• Ovoid in shape
• Embryonated from the beginning	• Freshly-passed eggs in feces are unembryonated
• Eggs are not operculated and the embryo is not ciliated	• Eggs are operculated and the embryo is ciliated

- The embryo inside the egg is called the *oncosphere* (meaning *hooked ball*) because it is spherical and has hooklets.
- Oncospheres of human tapeworms typically have three pairs of hooklets and so, are called *hexacanth* (meaning *six-hooked*) embryos.

Life Cycle

Cestodes complete their life cycle in two hosts: (1) definitive host and (2) intermediate host.

- **Humans** are the **definitive host** for most tapeworms, which cause human infection. An important exception is the dog tapeworm, *Echinococcus granulosus*, for which **dog** is the definitive host and man is the intermediate host. In *Taenia solium*, man is ordinarily the definitive host, but its larval stages can also develop in the human body.
- Cestodes complete their life cycle in two different hosts. Exceptions are:
 - *Hymenolepis* that requires only one host, man and *Diphyllobothrium* that requires three hosts, (1) **definitive host**: man; (2) **first intermediate host**: *Cyclops*; and (3) **second intermediate host**: fish.
- Clinical disease can be caused by the adult worm or the larval form. In general, adult worm causes only minimal disturbance, while the larvae can produce serious illness, particularly when they lodge in critical areas like the brain or the eyes.
- **Pseudophyllidean** tapeworms have a central *unbranched convoluted uterus*, which opens through a pore, possess ventrally situated genital pores, and produce operculated eggs that give rise to *ciliated larvae*.
- In **Cyclophyllidean** tapeworms, the uterus is *branched* and does not have an opening. They have lateral genital pores and produce nonoperculated eggs that yield larvae, which are not ciliated. Their larvae are called “bladder worms” and occur in four varieties: (1) *cysticercus*, (2) *cysticercoid*, (3) *coenurus* and (4) *Echinococcus*.

■ PSEUDOPHYLLIDEAN TAPEWORMS

Diphyllobothrium Latum

Common Name

Fish tapeworm/Broad tapeworm.

History and Distribution

The head of the worm was found by Bonnet in 1777, and its life cycle was worked out by Janicki and Rosen in 1917.

- Diphyllobothriasis (infection with *Diphyllobothrium*) occurs in Central and Northern Europe, particularly in the Scandinavian countries. It is also found in Siberia, Japan, North America and Central Africa.
- In countries like India, where fish is eaten only after cooking, the infection does not occur.
- **Longest cestode** infecting man: *Diphyllobothrium latum*
- **Smallest cestode** infecting man: *Hymenolepis nana*.

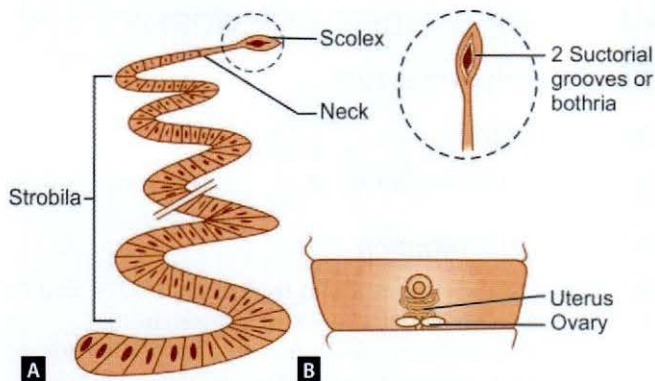
Habitat

The adult worm is found in the small intestine, usually in the ileum, where it lies folded in several loops with the scolex embedded in the mucosa.

Morphology

Adult worm: It is *ivory-colored* and very long, measuring up to 10 meters or more. It is the **largest tapeworm** inhabiting the small intestine of man.

- As in all cestodes, the adult worm has three parts: (1) scolex, (2) neck and (3) strobila.
- **Scolex** (head) is *spatulate* or **spoon-shaped**, about 2–3 mm long and 1 mm broad. It carries two slit-like longitudinal sucking grooves (*bothria*), one dorsal and the other ventral. The scolex lacks suckers and hooks (**Fig. 3A**).
- **Neck** is thin, unsegmented and is much more longer than the head.
- **Strobila** consists of 3,000–4,000 proglottids, consisting of immature, mature and gravid segments in that order from front to backwards.
- The mature proglottid is broader than long, about 2–4 mm long and 10–20 mm broad and is practically filled with male and female reproductive organs (**Fig. 3B**).
- The testes are represented by numerous minute follicles situated laterally in the dorsal plane.
- The female reproductive organs are arranged along the midline, lying ventrally. The ovary is **bilobed**. The large rosette-like uterus lies convoluted in the center.
- Three genital openings are present ventrally along the midline—the openings of the vas deferens, vagina and uterus in that order, from front to backwards.



Figs 3A and B: *Diphylobothrium latum*. (A) Adult worm showing spatulate scolex, neck and strobila; and (B) Mature proglottid

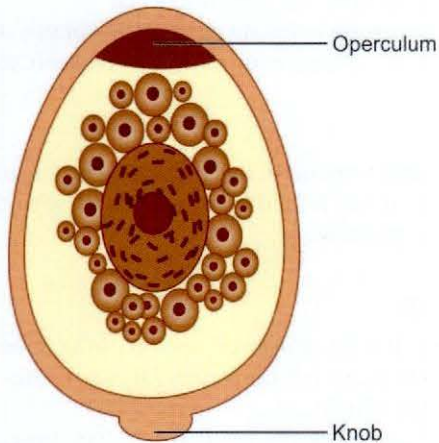


Fig. 4: Operculated egg of *Diphylobothrium latum*

- The fertilized ova develop in the uterus and are discharged periodically through the uterine pore.
- The terminal segments become dried up after delivering many eggs and are discharged in strands of varying lengths in the feces.

Egg: *D. latum* is a prolific egg layer and a single worm may pass about a million eggs in a day.

- Egg is broadly ovoid, about 65 μm by 45 μm , with a thick, light brown shell (Fig. 4).
- It has an **operculum** at one end and often a **small knob** at the other.
- The freshly-passed egg contains an immature embryo surrounded by yolk granules. The eggs are resistant to chemicals but are killed by drying. The embryo with **six hooklets** inside the egg is called the **oncosphere**.
- The egg **does not float** in saturated salt solution and is bile stained.
- They are not infective to humans.

Larval stages: There are three stages of larval development:

1. First stage larva (*coracidium*)
2. Second stage larva (*proceroid*)
3. Third stage larva (*plerocercoid*).

Life Cycle

Definitive hosts: Man, dog and cat. Man is the optimal host.

First intermediate host: Freshwater copepod, mainly of genera *Cyclops* or *Diaptomus*.

Second intermediate host: Freshwater fish (salmon, trout, etc.).

Infective form to human: **Third stage plerocercoid larva.**

- The adult worm lives in the small intestine. It lays operculated eggs which are passed along with the feces in water (Fig. 5).
- The freshly-passed egg contains an immature embryo surrounded by yolk granules. The embryo with six hooklets (**hexacanth embryo**) inside the egg is called the **oncosphere**.
- In water, it matures in about 10–15 days and **ciliated first stage larva**, called **coracidium** emerges through the operculum.
- Coracidium (first stage larva) can survive in water for about 12 hours, by which time it should be ingested by the fresh water crustacean copepod **Cyclops**, which is the first intermediate host (Fig. 5).
- In the midgut of the *Cyclops*, the coracidium casts off its ciliated coat and by means of its six hooklets, penetrates into the hemocele (body cavity). In about 3 weeks, it becomes transformed into the **elongated second stage larva** about 550 μm long, which is called the **proceroid larva**.
- **Proceroid larva** has a rounded caudal appendage (**cercomer**) which bears the now useless hooklets.
- If the infected *Cyclops* is now eaten by a freshwater fish (second intermediate host), the proceroid larva penetrates the intestine of the fish and grows.
- In the fish, proceroid larva loses its caudal appendage and develops into the **third stage larva** called the **plerocercoid larva** or **sparganum** (Fig. 5).
- **Plerocercoid larva** has a glistening white flattened unsegmented vermicule, with a wrinkled surface, is about 1–2 cm long, and possesses rudimentary scolex. This is the stage **infective** for humans.
- Man gets infection by eating raw or undercooked fish containing plerocercoid larva.
- The larva develops into adult worm in the small intestine.
- The worm attains maturity in about 5–6 weeks and starts laying eggs, which are passed along with the feces. The cycle is thus repeated.
- The adult worm may live for about 10 years or more.

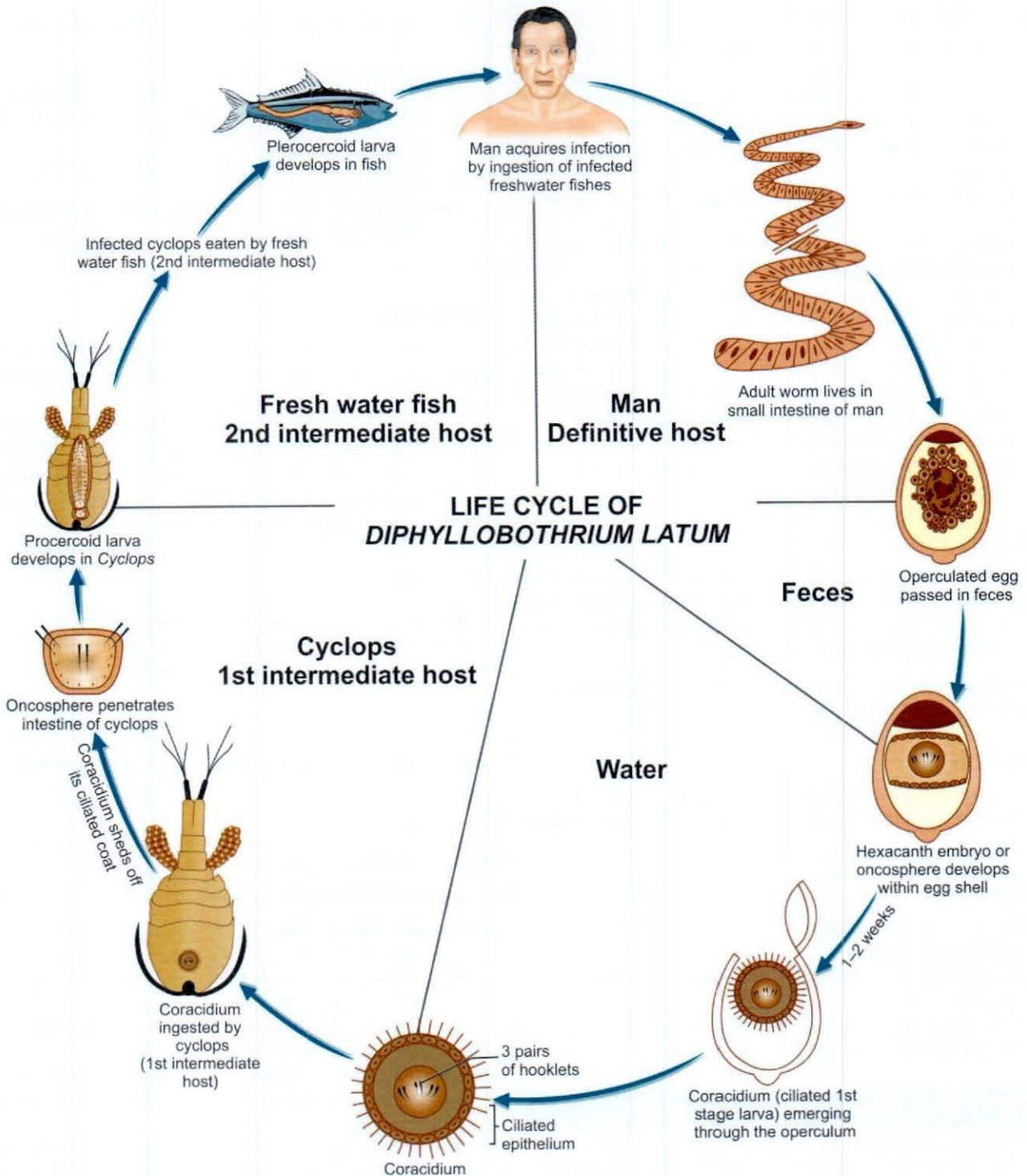


Fig. 5: Life cycle of *Diphyllobothrium latum*

Pathogenicity and Clinical Features

The pathogenic effects of *diphyllobothriasis* depend on the mass of the worm, absorption of its byproducts by the host and deprivation of the host's essential metabolic intermediates.

- In some persons, infection may be entirely asymptomatic, while in others there may be an evidence of mechanical obstruction.
- Transient abdominal discomfort, diarrhea, nausea, weakness, weight loss and anemia are the usual manifestations. Patients may be frightened by noticing the strands of proglottids passed in their feces.
- A kind of pernicious anemia, sometimes caused by the infection, is called *bothriocephalus anemia*. This was formerly believed to be racially determined, being common in Finland and rare elsewhere. The anemia develops because the tapeworm absorbs large quantity of vitamin B₁₂ and interferes with its ileal absorption, leading to **vitamin B₁₂ deficiency**.
- In severe cases, patients may exhibit neurologic sequelae of vitamin B₁₂ deficiency.

Laboratory Diagnosis

Stool microscopy: Eggs are passed in very large number in feces, and therefore, their demonstration in feces offers an easy method of diagnosis. The proglottids passed in feces can also be identified by their morphology.

Serodiagnosis: A coproantigen detection test is available to diagnose diphyllobothriasis.

Treatment

- Praziquantel in a single dose of 10 mg/kg is effective.
- Parenteral vitamin B₁₂ should be given, if B₁₂ deficiency is present.

Prophylaxis

Infection can be prevented by:

- Proper cooking of fish.
- Deep freezing (-10°C for 24–48 hours) of fish, if it is to be consumed raw.
- Prevention of fecal pollution of natural waters.
- Periodical deworming of pet dogs and cats.

KEY POINTS OF *DIPHYLLOBOTHRIUM LATUM*

- Longest tapeworm found in man.
- Adult worm up to 10 meters in length having spoon-shaped head with two slit-like grooves (bothria).
- **Definitive host:** Man (optimal host), dogs and cats.
- **First intermediate host:** *Cyclops*.
- **Second intermediate host:** Freshwater fish.

- Eggs are oval, operculated, bile stained and not infective to man.
- **Infective stage:** Plerocercoid larva.
- **Mode of transmission:** Man gets infection by consuming uncooked or undercooked fish containing third stage plerocercoid larva.
- **Clinical features:** Abdominal discomfort, nausea and megaloblastic anemia.
- **Diagnosis:** Stool microscopy for egg and coproantigen test.
- **Treatment:** Praziquantel and if required, vitamin B₁₂.

Spirometra

Genus *Spirometra* belongs to Diphyllobothriidae family. Species of this genera which are medically important are—*S. mansoni*, *S. theileri* and *S. erinacei*.

- *Spirometra* along with other *Diphyllobothrium* tapeworms that are not normal human parasite, can accidentally infect man and cause disease called as **sparganosis**.
- The disease is so named because it is caused by *sparganum* (*plerocercoid larva*) of the parasite.

Distribution

Sparganosis has been reported mostly from Japan and Southeast Asia; less often from America and Australia. A few cases have been reported from India also.

Habitat

Adult worms live in the intestinal tract of cats and dogs.

Life Cycle

Definitive host: Dog and cat.

First intermediate host: *Cyclops*.

Second intermediate host: Snakes, frogs and fishes.

- Adult worms live in the intestinal tract of dogs and cats and produce large number of eggs which pass out along with feces in water (**Fig. 6**).
- Eggs hatch in fresh water to release ciliated *first stage larva* called as *coracidium*.
- The coracidium is ingested by *Cyclops* (first intermediate host), where it develops into *second stage larva* called as *proceroid larva*.
- When the infected *Cyclops* is ingested by fish, snakes, amphibians (second intermediate host), the proceroid larva migrates to various organs of the body and develops into *plerocercoid larva* (*sparganum larva*). This is the *infective stage* of the larva for dogs and cats (definitive host) (**Fig. 6**).

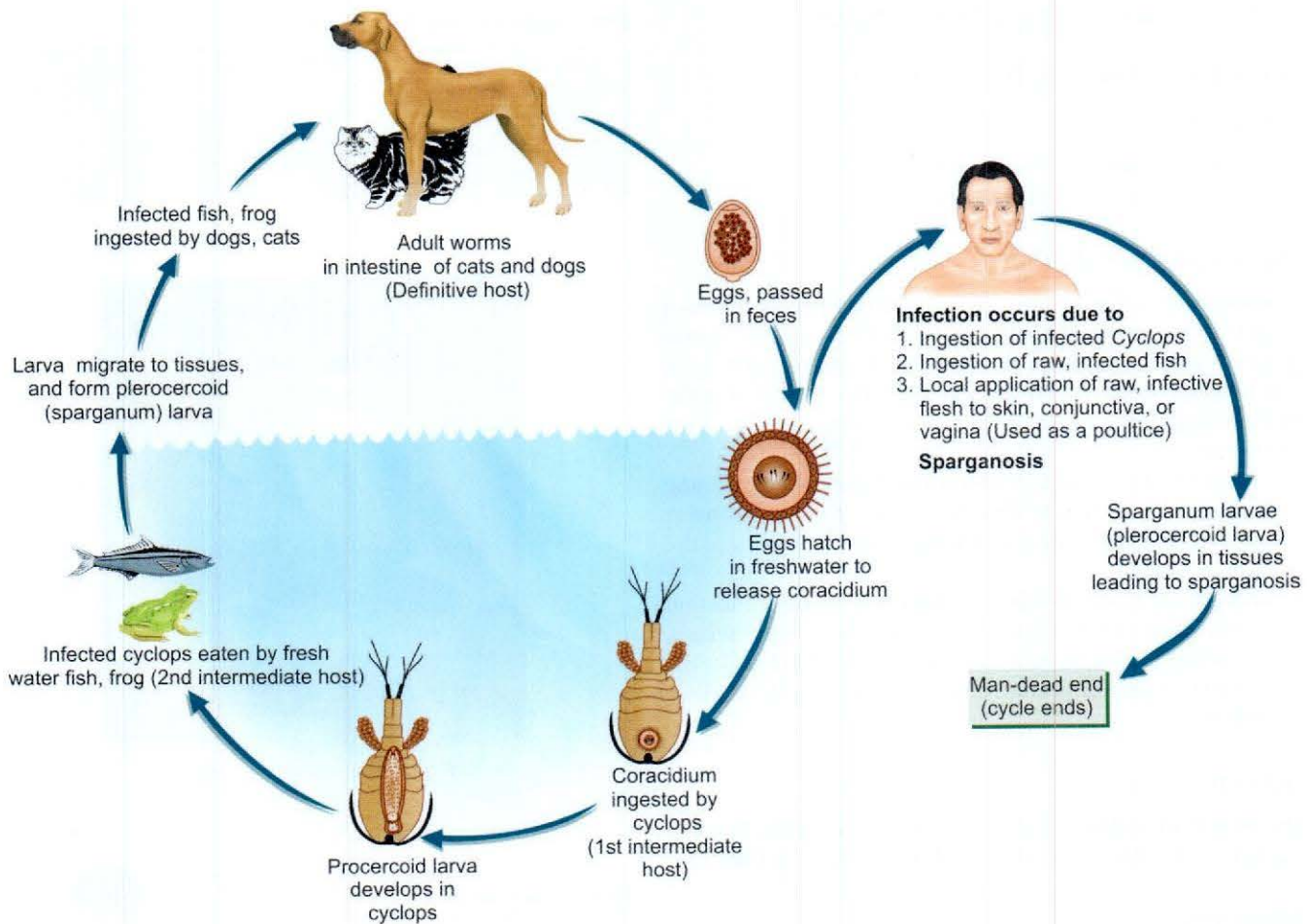


Fig. 6: Life cycle of *Spirometra*

- When a cat or dog eats the second intermediate host, the plerocercoid larva develops into adult worms in the intestine.
- Man acts as an **accidental host** and gets infection by:
 - Ingestion of *Cyclops* containing proceroid larva.
 - Ingestion of plerocercoid larva present in uncooked meat of animals or birds, frogs.
 - Local application of raw flesh of infected animals on skin or mucosa. The last method follows the practice prevalent among the Chinese, of applying split frogs on skin or eye sores as a poultice.

Sparganosis: The term sparganosis is used for ectopic infection by sparganum (plerocercoid larva) of *Spirometra* and some *Diphyllobothrium* species.

- The *sparganum* (L3 larva) are liberated from the *Cyclops* in the human intestine. They penetrate the intestinal wall and migrate to subcutaneous tissue, where they become encysted and develop into *spargana*.

- The sparganum is usually found in the subcutaneous tissues in various parts of the body, but may also be present in the peritoneum, abdominal viscera, or brain.

Laboratory Diagnosis

Diagnosis is usually possible only after surgical removal of the nodules and demonstration of the worm.

Treatment

Definitive treatment is surgical removal of the nodule.

Prophylaxis

Human's sparganosis is prevented by:

- Properly filtering and boiling drinking water.
- Eating properly cooked flesh.

■ CYCLOPHYLLIDEAN TAPEWORMS

Taenia Saginata and *Taenia Solium*

Common Name

- *Taenia saginata*: Beef tapeworm
- *Taenia solium*: Pork tapeworm.

History and Distribution

T. saginata has been known as an intestinal parasite of man from very ancient times. But it was only in 1782 when Goeze differentiated it from the pork tapeworm, *T. solium*. Its life cycle was elucidated when Leuckart, in 1861, first experimentally demonstrated that cattle serve as the intermediate host for the worm.

- The name *Taenia* is derived from the Greek word meaning *tape or band*. It was originally used to refer to most tapeworms, but is now restricted to the members of the Genus *Taenia*.
- *T. saginata* is worldwide in distribution, but the infection is not found in vegetarians and those who do not eat beef.
- *T. solium* is also worldwide in distribution except in the countries and communities, which proscribe pork as taboo.

Habitat

The adult worms of both *T. saginata* and *T. solium* (Fig. 7) live in the human small intestine, commonly in the jejunum (Box 1).

Morphology

Adult worm of *T. saginata*: The adult *T. saginata* worm is opalescent white in color, ribbon-like, dorsoventrally flattened and segmented, measuring 5–10 meters in length.

- The adult worm consists of head (scolex), neck and strobila (body). The general features of adult worm are similar to any cyclophyllidean cestodes.
- **Scolex:** The scolex (head) of *T. saginata* is about 1–2 mm in diameter, **quadrate** in cross-section, bearing **four** hemispherical suckers situated at its four angles. They may be pigmented. The scolex has no rostellum or hooklets (which are present in *T. solium*). *T. saginata* is, therefore called the *unarmed tapeworm*. The suckers serve as the sole organ for attachment (Fig. 8).
- The **neck** is long and narrow. The **strobila** (trunk) consists of 1,000–2,000 proglottids or segments—immature, mature and gravid.
- The gravid segments are nearly four times long as they are broad, about 20 mm long and 5 mm broad. The segment contains male and female reproductive structures. The testes are numerous, 300–400 (twice as many as in *T. solium*). The gravid segment has 15–30 lateral branches

Box 1: Cestodes living in small intestine

- *Diphyllobothrium latum*
- *Taenia solium*
- *Taenia saginata saginata*
- *Taenia saginata asiatica*
- *Hymenolepis nana*



Fig. 7: Adult worm of *T. solium*

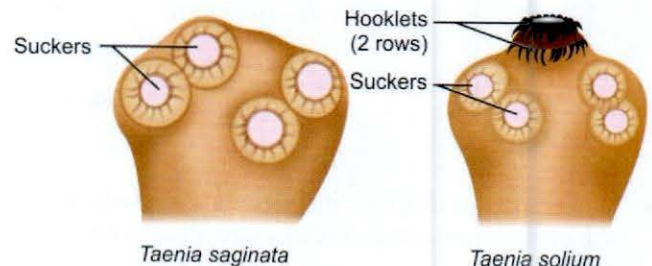


Fig. 8: Scolex of *Taenia saginata* and *Taenia solium*

(as against 7–13 in *T. solium*). It differs from *T. solium* also in having a **prominent vaginal sphincter** and in **lacking the accessory ovarian lobe**. The common genital pore opens on the lateral wall of the segments.

- The gravid segments break away and are expelled singly, actively forcing their way out through the anal sphincter. As there is no uterine opening, the eggs escape from the uterus through its ruptured wall.

Adult worm of *T. solium*:

- The adult worm is usually 2–3 meters long.
- The scolex of *T. solium* is small and **globular** about 1 mm in diameter, with **four large cup-like suckers** (0.5 mm in

Table 4: Difference between *Taenia saginata* and *Taenia solium*

	<i>Taenia saginata</i>	<i>Taenia solium</i>
Length	5–10 meter	2–3 meter
Scolex	Large quadrate	Small and globular
	Rostellum and hooks are absent	Rostellum and hooks are present
	Suckers may be pigmented	Suckers not pigmented
Neck	Long	Short
Proglottids	1,000–2,000	Below 1,000
Measurement (gravid segment)	20 mm × 5 mm	12 mm × 6 mm
Expulsion	Expelled singly	Expelled passively in chains of 5 or 6
Uterus	Lateral branches 15–30 on each side; thin and dichotomous	Lateral branches 5–10 on each side; thick and dendritic
Vagina	Present	Absent
Accessory lobe of ovary	Absent	Present
Testes	300–400 follicles	150–200 follicles
Larva	Cysticercus bovis; present in cow not in man	Cysticercus cellulosae; present in pig and also in man
Egg	Not infective to man	Infective to man
Definitive host	Man	Man
Intermediate host	Cow	Pig, occasionally man
Disease	Causes intestinal taeniasis	Causes intestinal taeniasis and cysticercosis

diameter), and a conspicuous rounded rostellum, armed with a double row of alternating round and small **dagger-shaped hooks**, 20–50 in number.

- The **neck** is short and half as thick as the head.
- The **proglottids** number less than a 1,000. They resemble those of *T. saginata* in general. The gravid segments are twice as long as broad, 12 mm by 6 mm. The testes are composed of 150–200 follicles. There is an accessory lobe for the ovary. The vaginal sphincter is absent. The uterus has only 5–10 (under 13) thick lateral branches. A lateral thick-lipped genital pore is present, alternating between the right and left sides of adjacent segments.
- The gravid segments are not expelled singly, but pass passively out as short chains. The eggs escape from the ruptured wall of the uterus.

The other differentiating features of *T. saginata* and *T. solium* are given in **Table 4**.

Eggs: Eggs of both species are indistinguishable.

- The egg is **spherical**, measuring 30–40 μm in diameter.
- It has a thin hyaline embryonic membrane around it, which soon disappears after release.
- The **inner embryophore** is radially striated and is yellow-brown due to **bile staining** (**Figs 9A and B**).
- In the center is a fully-developed embryo (**oncosphere**) with three pairs of hooklets (**hexacanth embryo**).
- The eggs do not float in saturated salt solution.
- The eggs of *T. saginata* are infective only to cattle and not to humans, whereas the eggs of *T. solium* are infective to pigs and humans too.

Larva: The larval stage of *Taenia* is called as **cysticercus**.

- Cysticercus bovis is the larva of *T. saginata* (**Fig. 10**).
- Cysticercus cellulosae is the larva of *T. solium* (**Fig. 12**).

Cysticercus bovis:

- It is the larval form of *T. saginata*.
- The name cysticercus is derived from the Greek, *kystis*—*bladder and kerkos*—*tail*.
- The larva (cysticercus bovis) is **infective stage** for humans.
- The cysticercus is an ovoid, milky-white opalescent fluid-filled vesicle measuring about 5 mm × 10 mm in diameter, and contains a single invaginated scolex (**bladder worm**).
- The cysticerci are found in the muscles of mastication, cardiac muscles, diaphragm and tongue of infected cattle (**Fig. 10**).
- They can be seen on visual inspection as shiny white dots in the **infected beef** (**measly beef**) (**Fig. 11**).
- Cysticercus bovis is unknown in humans.

Cysticercus cellulosae:

- It is the larval form of *T. solium* and also the **infective form** of the parasite.
- It can develop in various organs of pig as well as in man.
- The cysticercus cellulosae or “**bladder worm**” is ovoid opalescent milky-white, measuring 8–10 mm in breadth and 5 mm in length.
- The scolex of the larva, with its suckers, lies invaginated within the bladder and can be seen as a thick white spot. It remains viable for several months (**Fig. 12**).

Life Cycle of *Taenia Saginata*

T. saginata passes its life cycle in two hosts (**Fig. 13**):

1. **Definitive host:** Humans are the definitive hosts and harbor the adult worm.
2. **Intermediate host:** Cattle (cow or buffalo) are the intermediate host and harbor the larval stage of the worm.

Infective stage: Cysticercus bovis (larval stage) is the infective stage to man, while eggs are infective to cattle.

- The adult worm lives in the small intestine of man. The gravid segments from the adult worm break away and are expelled singly. They actively force their way out through the anal sphincter.

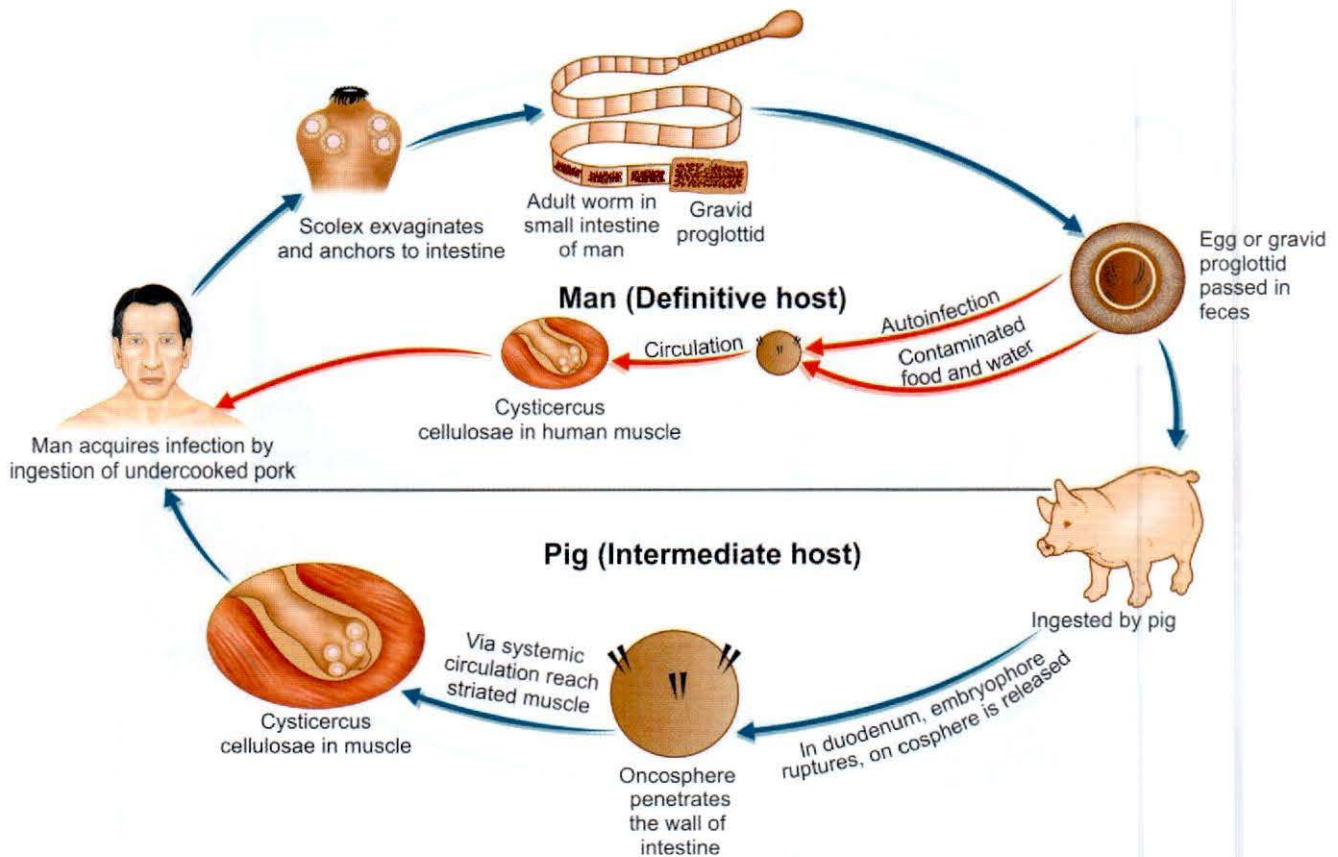


Fig. 14: Life cycle of *Taenia solium*

- They are filtered out principally in the muscles, where they develop into the larval stage, *cysticercus cellulosae* in about 60–70 days.
- In humans, it is a dead end and the larvae die without further development.
- Intestinal infection with *T. solium* occurs only in persons eating undercooked pork and usually in persons of low socioeconomic condition with poor sanitation. It is uncommon in Jews and Mohammedans, who are not generally pork eaters. But cysticercosis may occur in any person residing in endemic areas, even in vegetarians because the mode of infection is contamination of food or drink with egg deposited in soil.
- Eggs of *T. solium* are infective to pigs as well as to man.

Pathogenicity and Clinical Features

Intestinal taeniasis: It can be caused by both *T. saginata* and *T. solium*.

- The adult worm, in spite of its large size, causes surprisingly little inconvenience to the patient.
- When the infection is symptomatic, vague abdominal discomfort, indigestion, nausea, diarrhea and weight

loss may be present. Occasional cases of acute intestinal obstruction, acute appendicitis and pancreatitis have also been reported.

Cysticercosis: It is caused by larval stage (*cysticercus cellulosae*) of *T. solium*.

- *Cysticercus cellulosae* may be solitary or more often multiple.
- Any organ or tissue may be involved, the most common being subcutaneous tissues and muscles. It may also affect the eyes, brain, and less often the heart, liver, lungs, abdominal cavity and spinal cord.
- The cysticercus is surrounded by a fibrous capsule except in the eye and ventricles of the brain.
- The larvae evoke a cellular reaction starting with infiltration of neutrophils, eosinophils, lymphocytes, plasma cells, and at times, giant cells. This is followed by fibrosis and death of the larva with eventual calcification.
- The clinical features depend on the site affected:
 - **Subcutaneous nodules** are mostly asymptomatic.
 - **Muscular cysticercosis** may cause acute myositis.
 - **Neurocysticercosis** (cysticercosis of brain) is the most common and most serious form of

cysticercosis. About 70% of adult-onset epilepsy is due to neurocysticercosis. Other clinical features of neurocysticercosis are increased intracranial tension, hydrocephalus, psychiatric disturbances, meningoencephalitis, transient paresis, behavioral disorders, aphasia and visual disturbances. It is considered as the second most common cause of intracranial space occupying lesion (ICSOL) after tuberculosis in India.

- In **ocular cysticercosis**, cysts are found in vitreous humor, subretinal space and conjunctiva. The condition may present as blurred vision or loss of vision, iritis, uveitis and palpebral conjunctivitis.

Laboratory Diagnosis

Stool examination:

Eggs:

- Microscopic examination of feces shows characteristic eggs of *Taenia* in 20–80% of patients.
- Formol-ether sedimentation method of stool concentration is useful.
- Eggs can also be detected by *cellophane swab method* (NIH swab) in 85–95% patients.
- Species identification cannot be made from the eggs, since the eggs of *T. saginata* and *T. solium* are similar (**Flow chart 1**).

Proglottids:

Species identification can be done by examining with a hand lens, the gravid proglottid pressed between two slides, when branching can be made out (15–20 lateral branches in *T. saginata*; under 13 in *T. solium*).

Scolex:

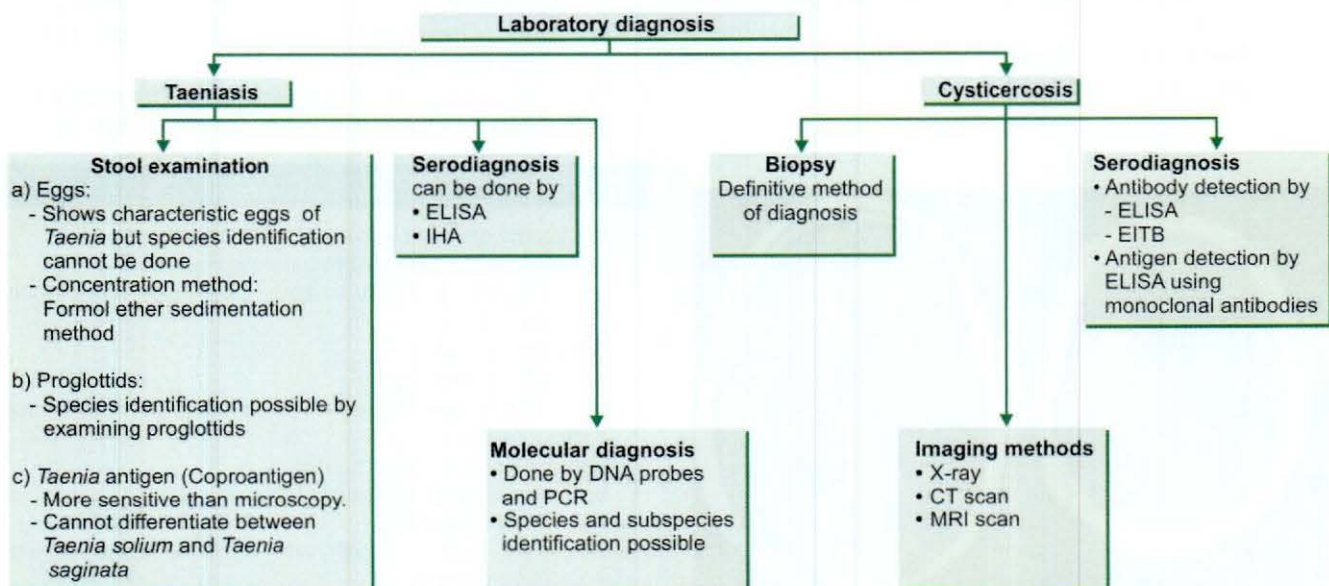
Definitive diagnosis can also be established by demonstration of unarmed scolex in case of *T. saginata* after anthelmintic treatment.

Detection of *Taenia* antigen in feces: Antigen capture enzyme-linked immunosorbent assay (ELISA) using polyclonal antisera against *Taenia* are employed to detect **coproantigen** in feces since 1990 and is more sensitive than microscopy (specificity 100% and sensitivity 98%). The drawback of the test is that it cannot differentiate between *T. saginata* and *T. solium* (**Flow chart 1**).

Serodiagnosis: Specific antibodies to adult stage antigen in serum can be demonstrated by ELISA, indirect immunofluorescence test and indirect hemagglutination (IHA) test (**Flow chart 1**).

Molecular diagnosis: Both deoxyribonucleic acid (DNA) probes and polymerase chain reaction (PCR) technique are used to detect and differentiate between eggs and proglottids of *T. saginata* and *T. solium* (**Flow chart 1**). It can also differentiate between the two subspecies of *T. saginata*, viz. *T. saginata saginata* and *T. saginata asiatica*.

Flow chart 1: Laboratory diagnosis of *Taenia* spp.

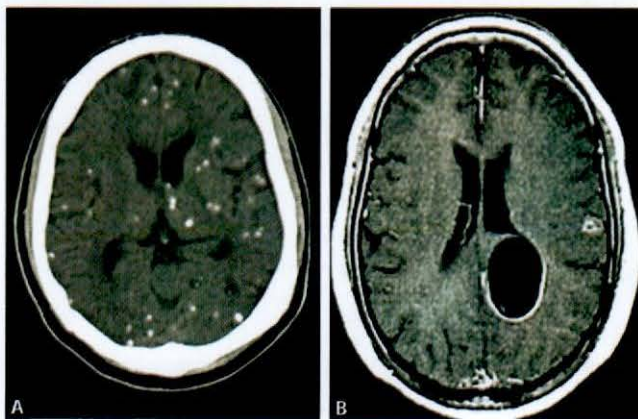


Abbreviations: CT, computed tomography; DNA, deoxyribonucleic acid; EITB, enzyme-linked immunoelectrotransfer blot; ELISA, enzyme-linked immunosorbent assay; IHA, indirect hemagglutination; MRI, magnetic resonance imaging; PCR, polymerase chain reaction

Laboratory Diagnosis of Cysticercosis

Diagnosis of cysticercosis is based on the following (Flow chart 1):

- **Biopsy:** Definitive diagnosis of cysticercosis is by biopsy of the lesion and its microscopic examination to show the invaginated scolex with suckers and hooks.
- **Imaging methods:**
 - **X-ray:** Calcified cysticerci can be detected by radiography of subcutaneous tissue and muscles particularly in the buttocks and thigh. X-ray of the skull may demonstrate cerebral calcified cyst.
 - **Computed tomography (CT) scan** of brain is the best method for detecting dead calcified cysts. The cysticercal lesions appear as small hypodensities (ring or disk-like) with a bright central spot (Figs 15A and B).
 - **Magnetic resonance imaging (MRI) scan** of the brain is more helpful in detection of noncalcified cysts and ventricular cysts. It also demonstrates spinal cysticerci.
- **Serology:**
 - **Antibody detection:** Anticysticercus antibodies in serum or cerebrospinal fluid (CSF) can be detected by "ELISA" and enzyme-linked immunoelectrotransfer blot (EITB) tests.
 - **Antigen detection:** Antigen can be detected in serum and CSF by ELISA, using monoclonal antibodies and indicate recent infection.
- **Others:**
 - **Ocular cysticercosis** can be made out by ophthalmoscopy.
 - **Eosinophilia:** Usually occurs in early stage of cysticercosis, but is not constant.



Figs 15A and B: (A) Computed tomography (CT) scan shows multiple calcified cysts of cysticercus cellulosae in the brain parenchyma; and (B) CT scan of brain shows clear cyst wall in a cysticercal lesion

Treatment

Intestinal taeniasis: Single dose of praziquantel (10–20 mg/kg) is the drug of choice.

- Niclosamide (2 g), single dose, is another effective drug.
- Purgation is not considered necessary.

Cysticercosis:

- For cysticercosis, **excision** is the best method, wherever possible.
- Asymptomatic neurocysticercosis requires no treatment.
- For symptomatic cerebral cysticercosis, **praziquantel** in a dose of 50 mg/kg in three divided doses for 20–30 days and **albendazole** in a dose of 400 mg twice daily for 30 days may be administered.
- Corticosteroids may be given along with praziquantel or albendazole to reduce the inflammatory reactions caused by the dead cysticerci.
- In addition, antiepileptic drugs should be given until the reaction of the brain has subsided.
- Operative intervention is indicated for hydrocephalus.

Prophylaxis

- Beef and pork to be eaten by man should be subjected to effective inspection for cysticerci in slaughter house.
- Avoidance of eating raw or undercooked beef and pork. The critical thermal point of cysticercus is 56°C for 5 minutes.
- Maintenance of clean personal habits and general sanitary measures.
- For control of cysticercosis, prevention of fecal contamination of soil, proper disposal of sewage and avoidance of eating raw vegetables grown in polluted soil are useful measures.
- Detection and treatment of persons harboring adult worm, as they can develop cysticercosis due to autoinfection.

KEY POINTS OF TAENIA SAGINATA

- Most common, large ribbon-like tapeworm.
- Rostellum and hooks absent (unarmed tapeworm).
- 1,000–2,000 proglottids with 15–30 dichotomously branched uterus.
- **Definitive host:** Man.
- **Intermediate host:** Cow.
- **Mode of infection:** Undercooked (measly) beef containing cysticercus bovis
- Eggs are not infective to human.
- Asymptomatic, clinical features occur occasionally—abdominal discomfort, indigestion.
- **Diagnosis:** Eggs or proglottids in stool, serodiagnosis, molecular diagnosis.
- **Treatment:** Praziquantel is the drug of choice and excision in case of cysticercosis.
- **Prophylaxis:** By avoidance of eating undercooked beef.

KEY POINTS OF *TAENIA SOLIUM*

- Smaller than *T. saginata* with rostellum and hooks (armed tapeworm).
- Less than 1,000 proglottids with 5–10 thick dendritic branched uterus.
- *Definitive host*: Man.
- *Intermediate host*: Pig, occasionally man (in case of cysticercosis).
- *Mode of infection*: Undercooked (measly) pork containing cysticercus cellulosae; autoinfection and egg in contaminated vegetable, food and water.
- Eggs are infective to human.
- *Clinical features*: Adult worm is asymptomatic. Larval forms cause cystic lesion in subcutaneous tissue, muscle, brain (neurocysticercosis) and eye.
- *Diagnosis*: Intestinal taeniasis—egg or proglottids in stool; cysticercosis—biopsy, X-ray, CT scan, MRI and serology.
- *Treatment*: Praziquantel, albendazole, antiepileptics in neurocysticercosis.
- *Prophylaxis*: By avoidance of eating undercooked pork and raw vegetables.

Taenia Saginata Asiatica

T. saginata asiatica is closely related to *T. saginata* and is found mainly in Asia.

- It is morphologically similar to *T. saginata* except:
 - It is **smaller** than *T. saginata*.
 - Intermediate host is pig (not cow).
 - Its cysticerci are located primarily in liver of the pig (not muscle).
- Clinical features, diagnosis and treatment are similar to that of *T. saginata*.

Multiceps Multiceps (Taenia Multiceps)

Tapeworms of the Genus *Multiceps* (*M. multiceps*, *M. serialis*, *M. glomeratus*, etc.) are widespread natural parasites of dogs and other canines.

Definitive host: Dog, wolf and fox.

Intermediate host: Sheep, cattle, horses and other ruminants.

- Humans act as accidental intermediate host.
- Humans get infected by ingesting food or water contaminated with dogs feces containing eggs.
- Oncospheres hatch out from the eggs, penetrate the intestine and migrate to various organs, usually central nervous system (CNS) where it transforms into the larval stage called as **coenurus**.
- Coenurus is a roughly spherical or ovoid bladder worm, up to 3 cm in size, and bearing multiple invaginated protoscolices (hence, the name *multiceps*).

- In sheep, coenurus is typically seen in the brain and spinal cord. Affected sheep develop cerebellar ataxia, giving the disease its name “**staggers**”.
- Human coenurosis has been reported from Africa, Europe and the United States of America (USA). The sites affected mainly are the orbit, brain and subcutaneous tissue.
- Clinical disease is due to pressure effects, symptoms being headache, vomiting, paresis and seizures and also due to allergic reactions.
- Surgical removal, where feasible is the only mode of treatment.

Echinococcus Granulosus

Common Name

Dog tapeworm.

History and Distribution

Hydatid cysts had been described by Hippocrates and other ancient physicians.

- Adult *E. granulosus* was described by Hartmann in the small intestine of dog in 1695 and the larval form (hydatid cysts) was recognized in 1782 by Goeze.
- The disease is prevalent in most parts of the world, though it is most extensive in the sheep and cattle-raising areas of Australia, Africa and South America. It is also common in Europe, China and the Middle East.
- It is a significant health problem in India. It is seen more often in temperate than in tropical regions.

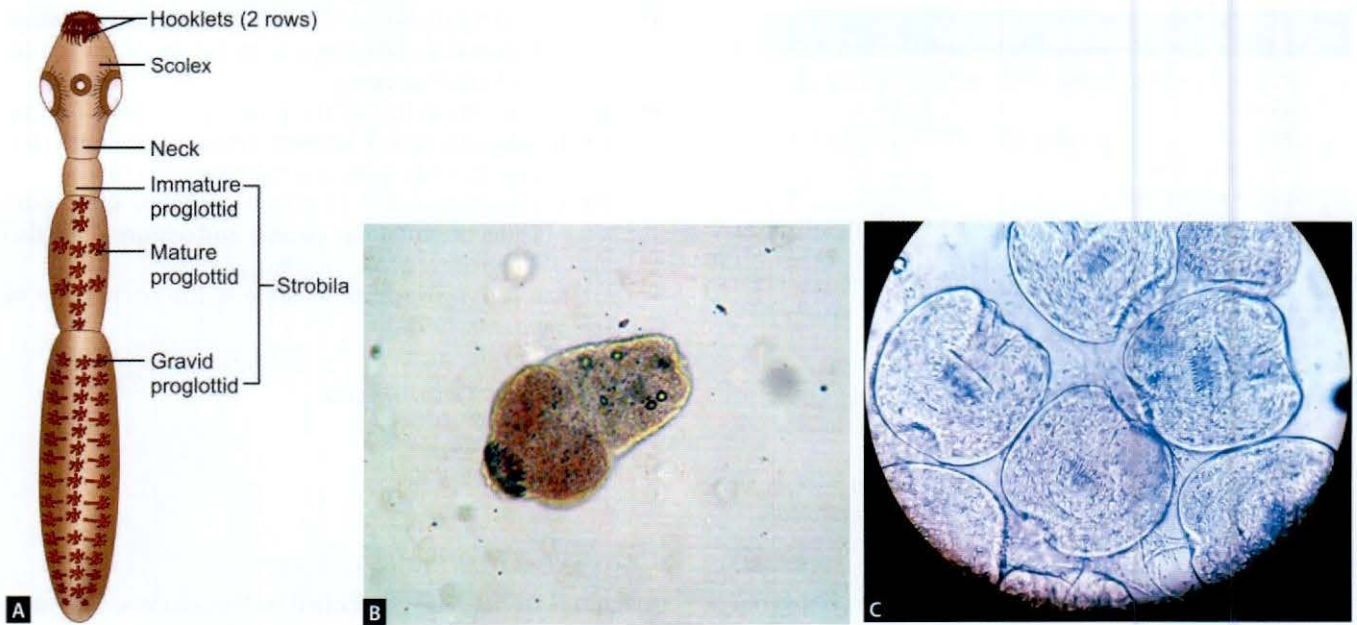
Habitat

- The adult worm lives in the **jejunum** and **duodenum of dogs** and other canine carnivora (wolf and fox).
- The larval stage (hydatid cyst) is found in humans and herbivorous animals (sheep, goat, cattle and horse).

Morphology

Adult worm: It is a small tapeworm, measuring only 3–6 mm in length.

- It consists of a **scolex**, a short **neck** and **strobila**.
- The scolex is **pyriform**, with four suckers and a prominent rostellum bearing two circular rows of hooklets (25–30).
- The neck is short than the rest of the worm (3 mm × 6 mm).
- The strobila is composed of only three proglottids: (1) the anterior immature, (2) the middle mature and (3) the posterior gravid segment (**Figs 16A to C**).
- The terminal proglottid is longer and wider than the rest of the worm and contains a branched uterus filled with eggs.
- The adult worm lives for 6–30 months.



Figs 16A to C: *Echinococcus granulosus*. (A) Schematic diagram of adult worm; (B) Microscopic appearance of scolex of *Echinococcus*; and (C) Microscopic appearance of scolex in tongue

Egg:

- The eggs of *Echinococcus* are indistinguishable from those of *Taenia* species.
- It is ovoid in shape and brown in color.
- It contains an embryo with three pairs of hooklets.

Larval form: The larval form is found within the **hydatid cyst** developing inside various organs of the intermediate host.

- It represents the structure of the scolex of adult worm and remains **invaginated** within a vesicular body.
- After entering the definitive host, the scolex with suckers and rostellar hooklets, becomes **exvaginated** and develops into adult worm.

Life Cycle

The worm completes its life cycle in two hosts (**Fig. 17**):

1. **Definitive hosts:** Dog (optimal host), wolf, jackal and fox.
2. **Intermediate host:** Sheep and cattle. Sheep is the ideal intermediate host.
 - Man acts as an accidental intermediate host (dead end).
 - The larval stage of the parasite is passed in intermediate hosts, including man, giving rise to hydatid cyst.
 - The adult worm lives in the small intestine of dogs and other canine animals. These animals discharge numerous eggs in the feces.
 - Intermediate hosts (sheep and cattle) ingest them while grazing.

- Human infection follows ingestion of the eggs due to intimate handling of infected dogs or by eating raw vegetables or other food items contaminated with dog feces.
- The ova ingested by man or by sheep and cattle are liberated from the chitinous wall by gastric juice liberating the **hexacanth embryos** which penetrate the intestinal wall and enter the **portal venules**, to be carried to the liver along the portal circulation.
- These are trapped in hepatic sinusoids, where they eventually develop into hydatid cyst. About 75% of hydatid cyst develops in liver, which acts as the first filter for embryo.
- However, some embryo which pass through the liver, enter the right side of heart and are caught in **pulmonary capillaries** (forming pulmonary hydatid cysts), so that the lung acts as the **second filter**.
- A few enter the systemic circulation and get lodged in various other organs and tissues such as the spleen, kidneys, eyes, brain, or bones.
- When sheep or cattle harboring hydatid cysts die or are slaughtered, dogs may feed on the carcass or offal. Inside the intestine of dogs, the scolices develop into the adult worms that mature in about 6-7 weeks and produce eggs to repeat the life cycle.
- When infection occurs in humans **accidentally**, the cycle comes to a dead end because the human hydatid cysts are unlikely to be eaten by dogs.

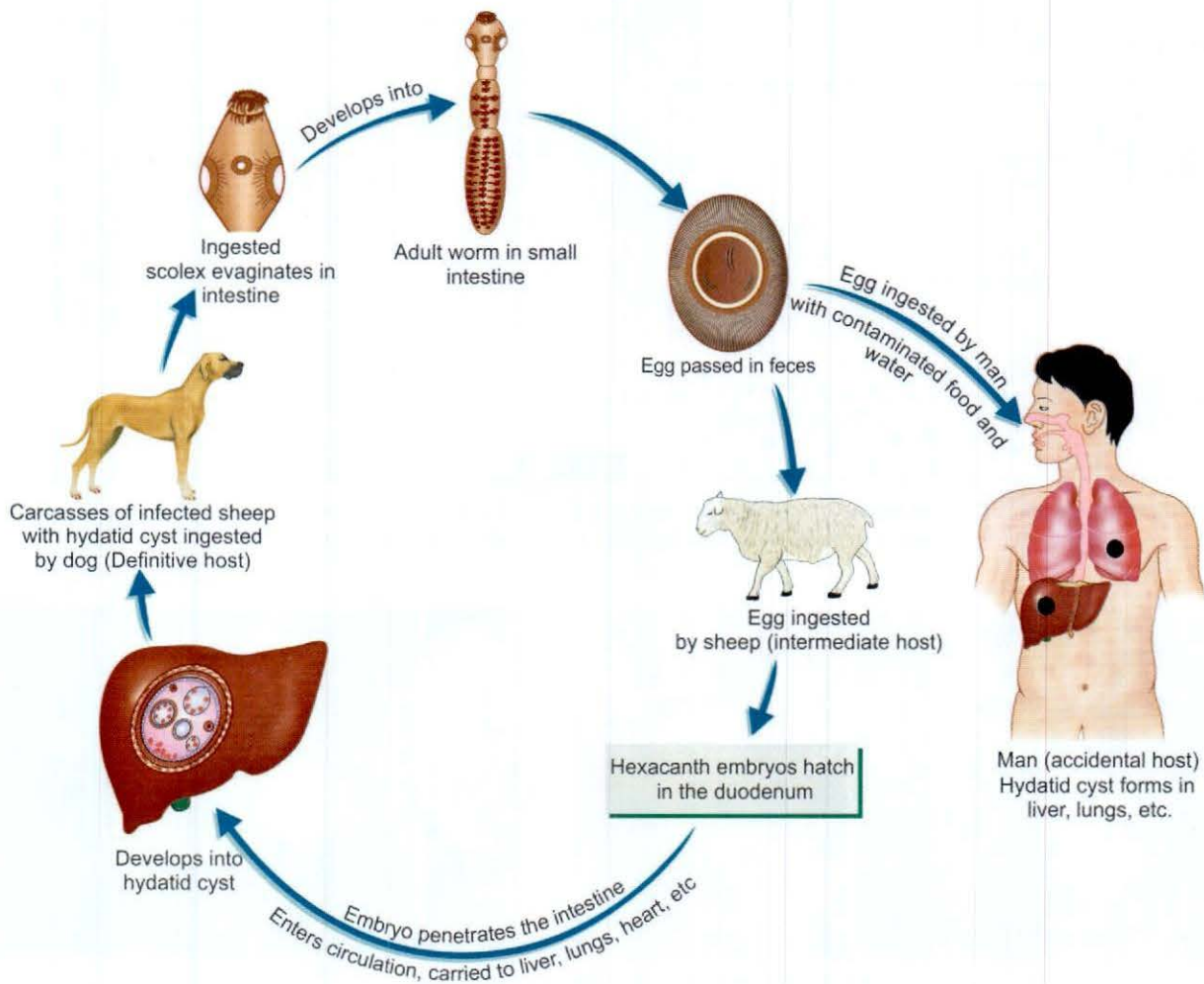


Fig. 17: Life cycle of *Echinococcus granulosus*

Pathogenesis

Evolution of hydatid cyst: At the site of deposition, the embryo slowly develops into a hollow bladder or cyst filled with fluid (Figs 18 to 20). This becomes the hydatid cyst (Greek *hydatis*: a drop of water).

- It enlarges slowly and reaches a diameter of 0.5-1 cm in about 6 months. The growing cyst evokes host tissue reaction leading to the deposition of fibrous capsule around it.
- The cyst wall secreted by the embryo consists of three indistinguishable layers (Figs 18 and 19):

1. **Pericyst** is the outer host inflammatory reaction consisting of fibroblastic proliferation, mononuclear cells, eosinophils and giants cells, eventually

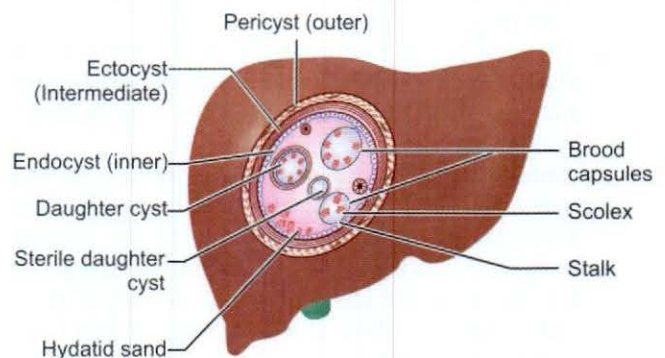


Fig. 18: Hydatid cyst in the liver

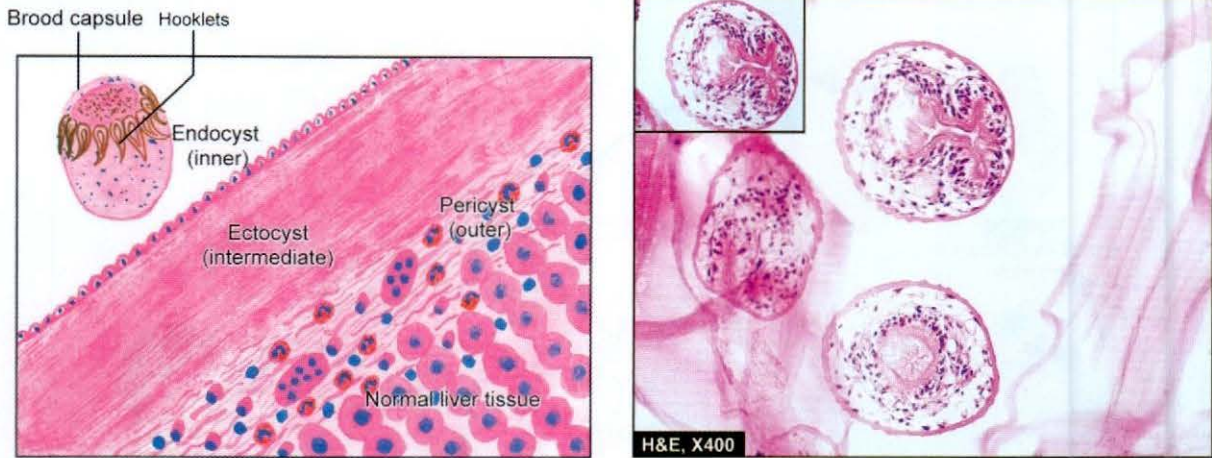
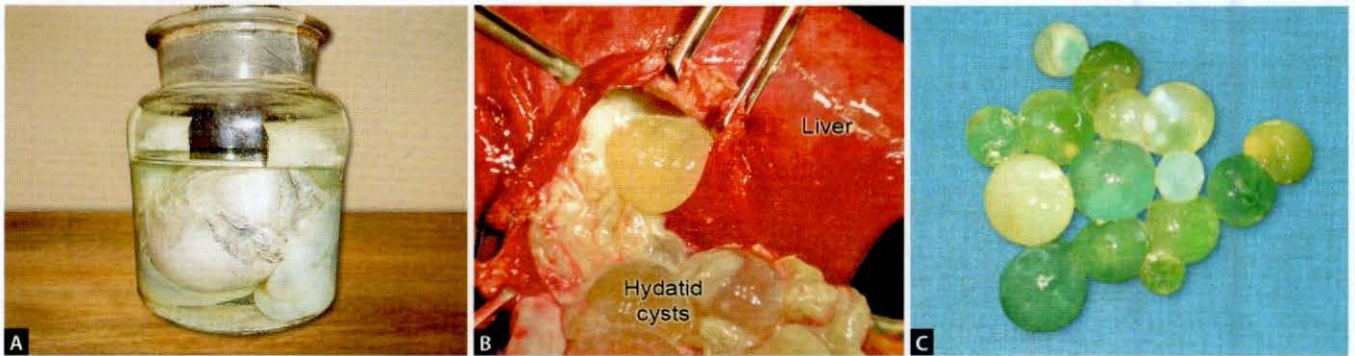


Fig. 19: Microscopy shows three layers in the wall of hydatid cyst. Inset in the right photomicrograph shows a scolex with a row of hooklets

Source: Mohan H. Textbook of Pathology, 6th edition. New Delhi: Jaypee Brothers Medical Publishers; 2010. p. 617.



Figs 20A to C: Hydatid cyst of the liver—typical look

Source: Bhat S. SRB's Manual of Surgery, 4th edition. New Delhi: Jaypee Brothers Medical Publishers; 2012. p. 639.

developing into dense fibrous capsule which may even calcify.

2. **Ectocyst** is the intermediate layer composed of characteristic acellular, chitinous, laminated hyaline material. It has the appearance of the white of a hard boiled egg.
 3. **Endocyst** is the inner germinal layer which is cellular and consists of number of nuclei embedded in a protoplasmic mass and is extremely thin (22–25 μm). The germinal layer is the vital layer of the cyst and is the site of asexual reproduction giving rise to brood capsules with scolices. It also secretes hydatid fluid, which fills the cyst.
- **Hydatid fluid:** The interior of the cyst is filled with a clear colorless or pale yellow fluid called as *hydatid fluid*.
 - pH of the fluid is 6.7 (acidic).

- **Composition:** It contains salts (sodium chloride 0.5%, sodium sulfate, sodium phosphate, and salts of succinic acid) and proteins.
- It is antigenic and highly toxic so that its liberation into circulation gives rise to pronounced eosinophilia or may even cause anaphylaxis.
- The fluid was used as the antigen for Casoni's intradermal test.

- A granular deposit or **hydatid sand** is found at the bottom of the cyst, consisting of **free brood capsules** and protoscolices and loose hooklets.

Brood capsules: From the germinal layer, small knob-like excrescences or gemmules protrude into the lumen of the cyst. These enlarge, become vacuolated, and are filled with fluid. These are called as *brood capsules*.

- They are initially attached to the germinal layer by a stalk, but later escape free into the fluid-filled cyst cavity.
- From the inner wall of the brood capsules, protoscolices (new larvae) develop, which represent the head of the potential worm, complete with invaginated scolex, bearing suckers and hooklets.
- Several thousands of protoscolices develop into a mature hydatid cyst, so that this represents an asexual reproduction of great magnitude.
- Inside mature hydatid cysts, further generation of cyst, **daughter** cysts and **granddaughter** cysts may develop. The cyst grows slowly often taking 20 years or more to become big enough to cause clinical illness and is therefore, particularly seen in man.

Acephalocysts: Some cysts are sterile and may never produce brood capsules, while some brood capsule may not produce scolices. These are called acephalocysts.

Fate of hydatid cysts: The cyst may get calcified or spontaneously evacuated following inflammatory reaction. Hydatid cyst of liver may rupture into lung or other body cavity producing disseminated hydatid lesions.

Clinical Features

- Most of the times infection is **asymptomatic** and accidentally discovered.
- Clinical disease develops only when the hydatid cyst has grown big enough to cause obstructive symptoms. Disease results mainly from **pressure effects** caused by the enlarging cysts.
- In about half the cases, the primary hydatid cyst occurs in **liver** (63%) (**Figs 20A to C**), mostly in the right lobe.

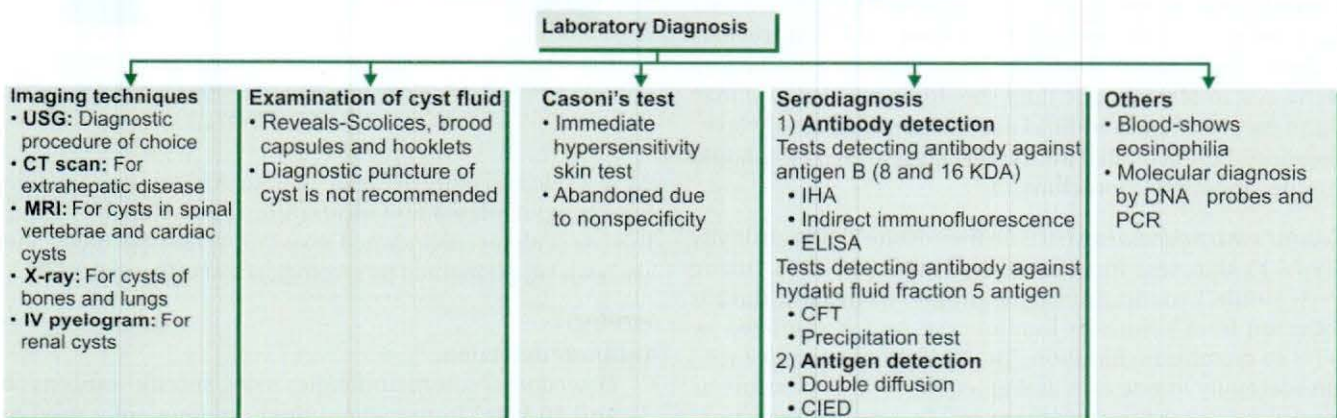
Hepatomegaly, pain and obstructive jaundice are the usual manifestations.

- The next common site is the **lung** (25%) (most common being the lower lobe of the right lung). Cough, hemoptysis, chest pain, pneumothorax and dyspnea constitute the clinical picture.
- In the **kidney** (2%), hydatid cyst causes pain and hematuria.
- **Other sites** affected include spleen (1%), brain (1%), pelvic organs, orbit and bones (3%).
 - Cerebral hydatid cysts may present as **focal epilepsy**.
 - When hydatid cyst is formed inside the **bones**, the laminated layer is not well-developed because of confinement by dense osseous tissues. The parasite migrates along the bony canals as naked excrescences that erode the bone tissue. This is called osseous hydatid cyst. Erosion of bone may lead to pathological fractures.
- Apart from pressure effects, another pathogenic mechanism in hydatid disease is **hypersensitivity** to the echinococcal antigen. The host is sensitized to the antigen by minute amounts of hydatid fluid seeping through the capsule. Hypersensitivity may cause **urticaria**. But if a hydatid cyst ruptures spontaneously or during surgical interference, massive release of hydatid fluid may cause severe, even **fatal anaphylaxis**.

Laboratory Diagnosis

Imaging: Radiological examinations and other imaging techniques such as ultrasonography (USG), CT scan and MRI reveal the diagnosis in most cases of **cystic echinococcosis** (**Flow chart 2**).

Flow chart 2: Laboratory diagnosis of *Echinococcus granulosus*



Abbreviations: CT, computed tomography; CFT, complement fixation test; CIED, cardiac implantable electronic device; DNA, deoxyribonucleic acid; ELISA, enzyme-linked immunosorbent assay; IHA, indirect hemagglutination; IV, intravenous; MRI, magnetic resonance imaging; PCR, polymerase chain reaction; USG, ultrasonography

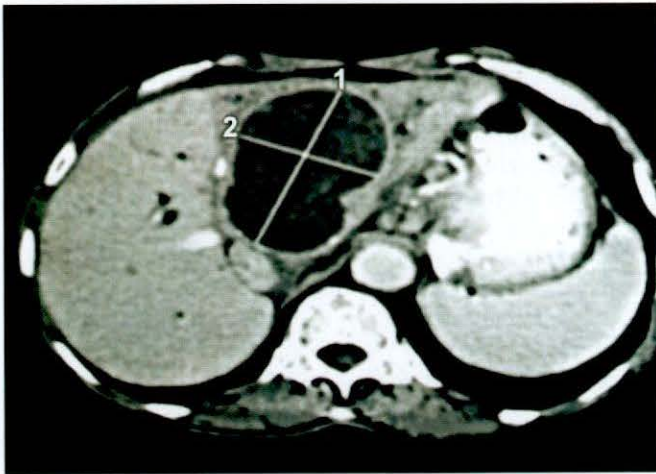


Fig. 21: Computed tomography (CT) scan shows a large noncalcified hydatid cyst in right hepatic lobe
Source: Dr Soma Sarkar



Fig. 22: Computed tomography (CT) scan showing a hydatid cyst with noncalcified wall in right lower lobe of lung
Source: Dr Himanshu Roy

- **Ultrasonography** is the diagnostic procedure of choice. Cyst wall typically shows double echogenic lines separated by a hypoechoic layer (**double contour**). Pathogenic findings include *daughter cysts* and the “**water-lily**” sign due to detached endocyst floating within the cavity.
- **Computed tomography scan** is superior for the detection of extrahepatic disease (**Figs 21 and 22**).
- **Magnetic resonance imaging** appears to add diagnostic benefit for cysts, especially at difficult sites such as spinal vertebrae and cardiac cysts.
- **Plain X-rays** permit the detection of hydatid cyst in lung and bones. In cases where long bones are involved, a mottled appearance is seen in the skiagram (**Fig. 23**).
- **Intravenous (IV) pyelogram** is often helpful for detection of renal hydatid cyst.

Examination of cyst fluid: Examination of aspirated cyst fluid under microscope after trichome staining reveals scolices, brood capsules and hooklets. Exploratory puncture of the cyst to obtain cystic fluid should be avoided as it may cause escape of hydatid fluid and consequent anaphylaxis. Therefore, fluid aspirated from surgically removed cyst should only be examined (**Flow chart 2**).

Casoni's intradermal test: It is an immediate hypersensitivity (Type 1) skin test introduced by Casoni in 1911, using fresh sterile hydatid fluid. The antigen in hydatid fluid is collected from animal or human cysts and is sterilized by Seitz or membrane filtration. The fluid is injected (0.2 mL) intradermally in one arm and an equal volume of saline as control is injected in the other arm. In a positive reaction, a large wheal of about 5 cm in diameter with multiple pseudopodia like projections appears within half an hour at

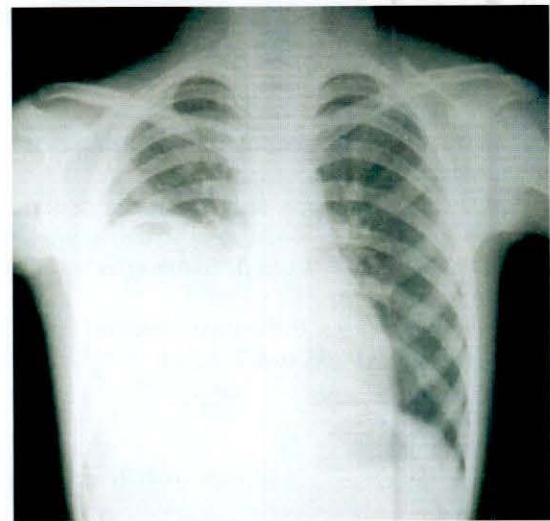


Fig. 23: Chest X-ray shows homogenous radiopaque opacity involving right lower lung with costophrenic angle
Source: Dr Soma Sarkar

the test side and fades in about an hour. A secondary reaction consisting of edema and induration appears after 8 hours. The test is almost abandoned now due to nonspecificity and has been supplemented by serological tests (**Flow chart 2**).

Serology:

Antibody detection:

- Detection of serum antibodies using specific antigens (**8 and 16 kDa**) from hydatid fluid are frequently used to support the clinical diagnosis of cystic echinococcosis. The tests include indirect hemagglutination (IHA),

indirect immunofluorescence and ELISA. In hepatic cysts, the sensitivity of test is relatively superior (85–98%) than pulmonary cyst (50–60%).

- The slide latex agglutination test and immune electrophoresis using hydatid fluid fraction 5 antigen are also widely used. Precipitin test and complement fixation test (CFT) with hydatid antigen have also been found to be positive. CFT is not very sensitive and false-positive reaction is seen in those receiving neural antirabic vaccine. CFT is useful after surgical removal of cysts, when a negative test has a better prognostic value (**Flow chart 2**).

Antigen detection: Specific **echinococcal antigen** in sera and in CSF can be detected by double diffusion and counter immunoelectrophoresis (CIEP) technique (**Flow chart 2**).

Blood examination: It may reveal a generalized **eosinophilia** of 20–25%.

Excretion of the scolices: Excretion of scolices into the sputum or urine may be observed in pulmonary or renal cyst, respectively and can be demonstrated by acid-fast staining or lactophenol cotton blue (LPCB) staining.

Specific molecular diagnostic: Specific molecular diagnostic methods have been developed involving DNA probes and PCR, but their application is limited by their technical complexity.

Treatment

Traditionally **surgical removal** was considered as the best mode of treatment of cysts. Currently, ultrasound staging is recommended and management depends on the stage.

In early stages, the treatment of choice is **puncture, aspiration, injection and reaspiration (PAIR)**.

- Puncture, aspiration, injection and reaspiration, considered as a controversial procedure earlier, is now widely used in early stages of the disease (**Box 2**).
- The basic steps involved in PAIR include:
 - Ultrasound or CT-guided puncture of the cyst.
 - Aspiration of cyst fluid.
 - Infusion of scolicidal agent (usually 95% ethanol; alternatively, hypertonic saline) (**Box 3**).
 - Reaspiration of the fluid after 5 minutes.
- Great care is taken to avoid spillage and cavities are sterilized with 0.5% silver nitrate or 2.7% sodium chloride for prophylaxis of secondary peritoneal echinococcosis due to inadvertent spillage of fluid during PAIR (**Box 4**).
- **Albendazole** (15 mg/kg in two divided doses) is initiated 4 days before the procedure and continued for 4 weeks afterwards.

Surgery: It is the treatment of choice for complicated *E. granulosus* cysts like those communicating with the biliary tract and in those cysts where PAIR is not possible.

Box 2: Indications of puncture, aspiration, injection and reaspiration (PAIR)

- Cysts with internal echoes on ultrasound (*snowflake sign*) multiple cysts, cysts with detached laminar membrane.
- Contraindications of PAIR for superficially located cysts, cysts with multiple thick internal septal divisions (honeycombing pattern), cysts communicating with biliary tree.

Box 3: Scolicidal agents and their complications

- **Cetrimide:** It can cause acidosis
 - **Alcohol 95%:** It can cause cholangitis
 - **Hypertonic saline:** Hypernatremia
 - **Sodium hypochlorite:** Hypernatremia
 - **Hydrogen peroxide.**
- Note:* In cases with biliary communication only hypertonic saline (15–20%) is used.

Box 4: *Echinococcus* species and the diseases caused by them

- *Echinococcus granulosus:* Hydatid disease
- *Echinococcus multilocularis:* Alveolar or multilocular hydatid disease
- *Echinococcus vogeli* and *Echinococcus oligarthrus:* Polycystic hydatid disease

- The preferred surgical approach is pericystectomy. For pulmonary cyst, treatment consists of wedge resection or lobectomy.
- Recurrence after surgery is common.
- Pre and postoperative chemotherapy with albendazole for 2 years after curative surgery is recommended.
- Positron emission tomography (PET) scanning can be used to follow disease activity.
- Other new treatment modalities include laparoscopic hydatid liver surgery and percutaneous thermal ablation (PTA) of the germinal layer of the cyst using radiofrequency ablation device.

Chemotherapy: Chemotherapy with benzimidazole agents are restricted to residual, postsurgical and inoperable cysts. Albendazole (400 mg BD for 3 months) and praziquantel (20 mg/kg/day for 2 weeks) have proved beneficial.

Prophylaxis

E. granulosus infection can be prevented by:

- Ensuring pet dogs do not eat animal carcass or offal.
- Periodical deworming of pet dogs.
- Destruction of stray and infected dogs.
- Maintaining personal hygiene such as washing of hands after touching dogs and avoidance of kissing pet dogs.

KEY POINTS OF *ECHINOCOCCUS GRANULOSUS*

- *Echinococcus* causes hydatid cyst in man.
- Smaller than other cestodes
- It measures 3–6 mm and consists of pyriform shaped, scolex, short neck and strobila consists of 3 proglottids.
- Eggs are similar to taenia
- Larval form is called hydatid cyst which develops inside various organs of the intermediate host
- Hydatid cyst consists of three layers—pericyst, ectocyst and endocyst and filled with hydatid fluid
- Hydatid cyst may be a symptomatic or may cause pressure effect and anaphylactic reactions.
- Laboratory diagnosis by USG, CT scan, MRI and rays.
- Treatment option includes surgery, PAIR and chemotherapy with albendazole praziquantel.

Echinococcus Multilocularis

This causes the rare but serious condition of **alveolar** or **multilocular hydatid** disease in humans (**Box 5**).

- It is found in the northern parts of the world, from Siberia in the East to Canada in the West.
- The adult worm is smaller than *E. granulosus* and lives in the intestines of foxes, dogs and cats which are the definitive host.
- Rodents are the main intermediate hosts.
- Human infection develops from eating fruits or vegetables contaminated with their feces.
- *E. multilocularis* leads to multilocular hydatid cyst. The liver is the most commonly affected organ. The multilocular infiltrating lesion appears like a grossly invasive growth, without any fluid or free brood capsule or scolices which can be mistaken for a malignant tumor.
- Patients present with upper quadrant and epigastric pain. Liver enlargement and **obstructive jaundice** may also be present. It may also metastasize to the spleen, lungs and brain in 2% cases.
- The prognosis is very grave and if untreated, 70% cases progress to death.
- Surgical resection, when possible, is the best method of treatment. Albendazole therapy is recommended for 2 years after curative surgery. In those cases, where surgery is not possible, indefinite treatment with albendazole is recommended.

Hymenolepis Nana

Common Name

Dwarf tapeworm.

Box 5: Malignant hydatid disease

- It is a misnomer, as it is a benign condition.
- It is caused by *Echinococcus multilocularis* (*alveolaris*). It presents with multiple small cysts in both lobes of the liver.
- It is difficult to treat and mimics clinically and prognosis wise to malignancy; hence the name.
- Patients die of liver failure.

History and Distribution

The name *Hymenolepis* refers to the thin membrane covering the egg (Greek *hymen*—*membrane*, *lepis*—*rind* or *covering*) and *nana* to its small size (*nanus*—*dwarf*). It was first discovered by Bilharz in 1857.

- It is cosmopolitan in distribution but is more common in warm than in cold climates.
- Infection is most common in school children and institutional populations.
- *Hymenolepis nana* is the **smallest** and the **most common** tapeworm found in the human intestine.
- It is unique that it is the only cestode which completes its life cycle in *one* host—humans.

Habitat

The adult worm lives in the proximal ileum of man. *H. nana* var. *fraterna* is found in rodents like mice and rats, where they are found in the posterior part of the ileum.

Morphology

Adult worm: *H. nana* is the smallest intestinal cestode that infects man.

- It is 5–45 mm in length and less than 1 mm thick. The *scolex* has four suckers and a retractile rostellum with a single row of hooklets (**Fig. 24**).
- The long slender *neck* is followed by the *strobila* consisting of 200 or more proglottids, which are much broader than long.
- Genital pores are situated on the same side along the margins.
- The uterus has lobulated walls and the testis is round and three in number.
- Eggs are released in the intestine by disintegration of the distal gravid segments.

Egg: The egg is roughly spherical or ovoid, 30–40 µm in size.

- It has a thin colorless outer membrane and inner *embryophore* enclosing the **hexacanth oncosphere** (**Figs 25A and B**).

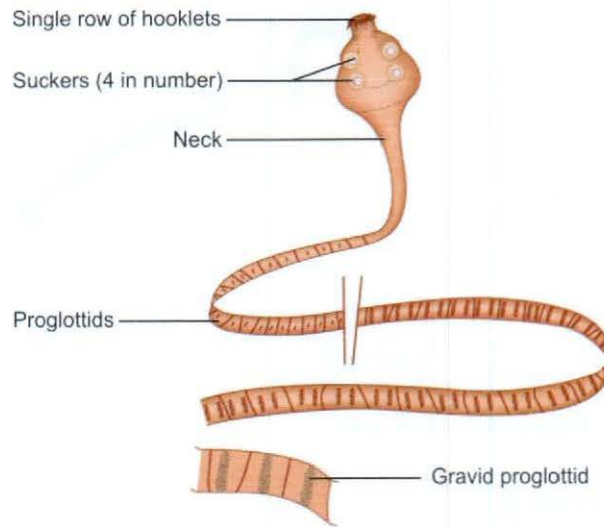
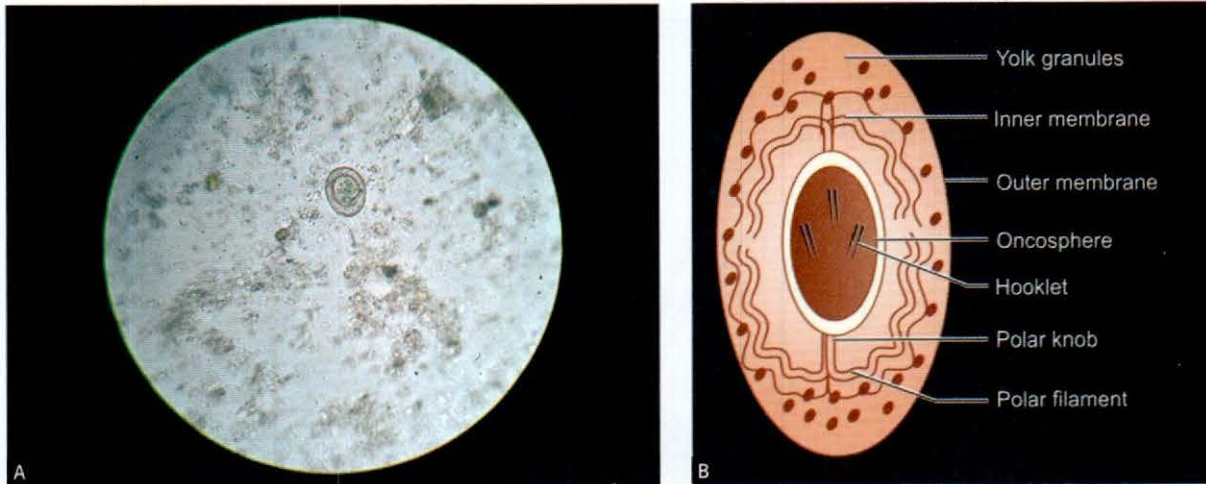


Fig. 24: Adult worm of *Hymenolepis nana*



Figs 25A and B: Egg of *Hymenolepis nana*. (A) As seen under microscope; and (B) Schematic diagram

- The space between two membranes contains **yolk granules** and **4-8 thread like polar filaments** arising from two knobs on the *embryophore*.
- The eggs float in saturated solution of salt and are *nonbile stained*.
- They are *immediately infective* and unable to survive for more than 10 days in external environment.
- **Mode of transmission:** Infection occurs by ingestion of the food and water contaminated with eggs.
 - *Internal autoinfection* may also occur when the eggs released in the intestine hatch there itself (**Fig. 26**).
 - *External autoinfection* occurs when a person ingest own eggs by fecal oral route.
- *H. nana* is unusual in that it undergoes multiplication in the body of the definitive host.
- When the eggs are swallowed, or in internal autoinfection, they hatch in the small intestine.
- The *hexacanth embryo* penetrates the intestinal villus and develops into the cysticercoid larva.

Life Cycle

Host: Man.

- There is no intermediate host.

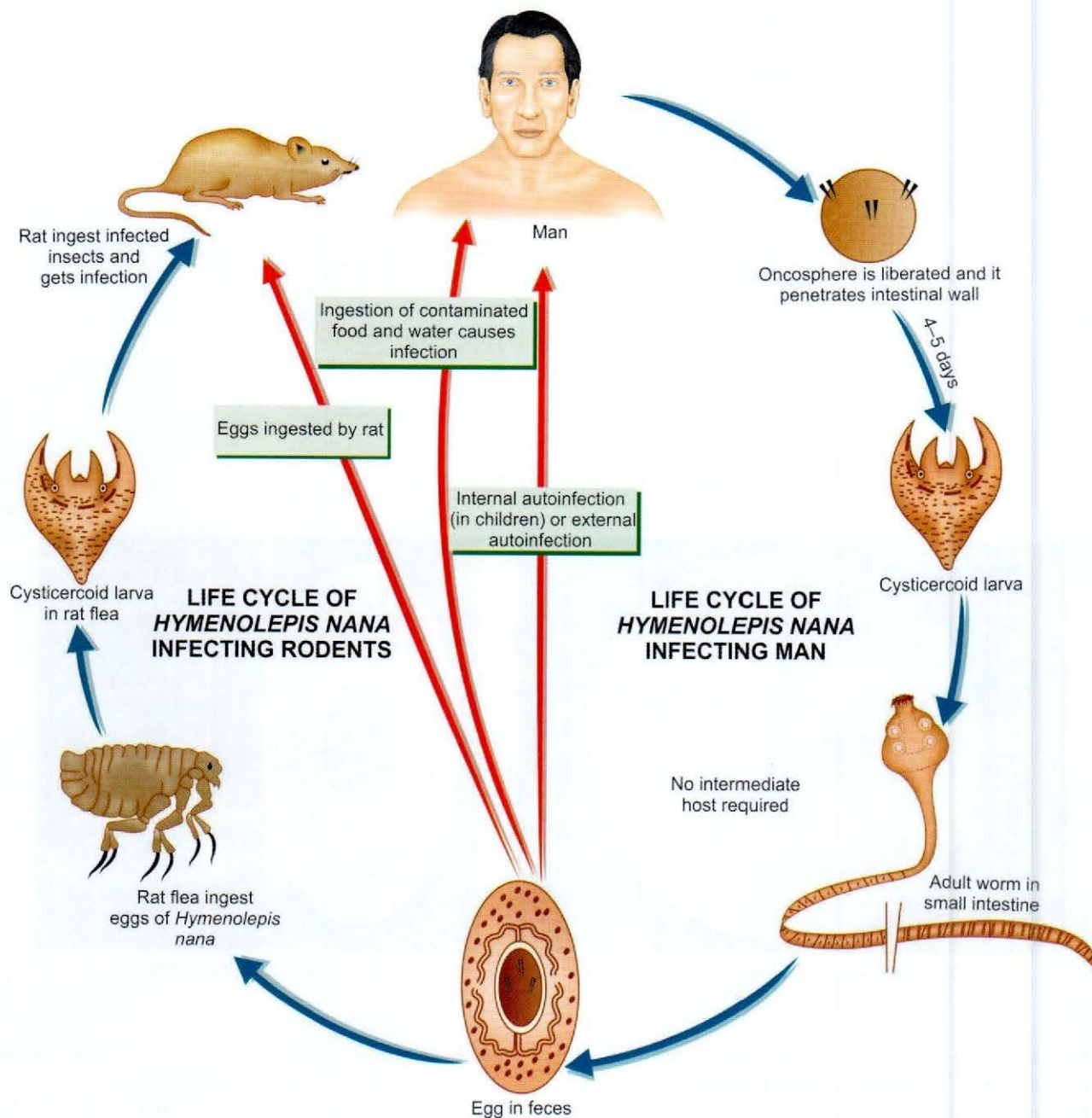


Fig. 26: Life cycle of *Hymenolepis nana*

- This is a solid pyriform structure, with the vesicular anterior end containing the invaginated scolex and a short conical posterior end.
- After about 4 days, the mature larva emerging out of the villus evaginates its scolex and attaches to the mucosae.
- It starts strobilization, to become the mature worm, which begins producing eggs in about 25 days.

A different strain of *H. nana* infects rats and mice. The eggs passed in **rodent feces** are ingested by **rat fleas** (*Xenopsylla cheopis* and others), which acts as the intermediate host. The eggs develop into cysticeroid larvae in the hemocele of these insects. Rodents get infected when they eat these insects. The murine strain does not appear to infect man. However, the human strain may infect rodents, which may, therefore, constitute a subsidiary reservoir of infection for the human parasite.

Clinical Features

Hymenolepis occurs more commonly in **children**.

- There are usually no symptoms but in heavy infections, there is nausea, anorexia, abdominal pain, diarrhea and irritability.
- Sometimes pruritus may occur due to an allergic response.

Laboratory Diagnosis

The diagnosis is made by demonstration of characteristic eggs in feces by direct microscopy. Concentration methods like salt flotation and formalin ether may be readily used. ELISA test has been developed with 80% sensitivity.

Treatment

Praziquantel (single dose of 25 mg/kg) is the drug of choice, since it acts both against the adult worms and the cysticeroids in the intestinal villi.

- Nitazoxanide 500 mg BD for 3 days may be used as alternative.

Prophylaxis

- Maintenance of good personal hygiene and sanitary improvements.
- Avoiding of consumption of contaminated food and water.
- Rodent control.

Hymenolepis Diminuta

This is called the **rat tapeworm** and is a common parasite of rats and mice.

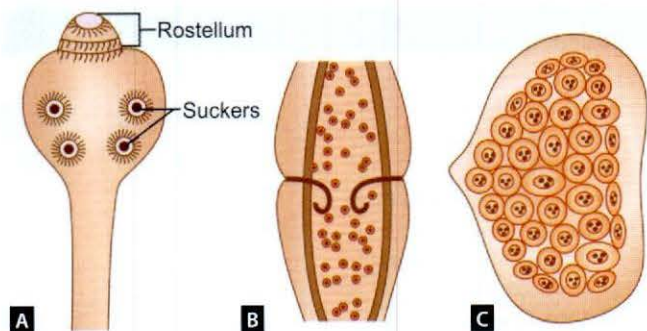
- The name *diminuta* is a misnomer, as it is larger than *H. nana* being 10–60 cm in length.
- Its life cycle is similar to that of the murine strain of *H. nana*.
- Rarely, human infection follows accidental ingestion of infected rat fleas. Human infection is asymptomatic.

Dipylidium Caninum

This common tapeworm of dogs and cats, it may accidentally cause human infection, mainly in children.

Morphology

- The adult worm in the intestine is about 10–70 cm long.
- The scolex has four prominent suckers and a retractile rostellum with up to seven rows of spines (**Figs 27A to C**).
- The mature proglottid has two *genital pores*, one on either side, hence the name *Dipylidium* (*dipyllos*—two entrances).



Figs 27A to C: *Dipylidium caninum*. (A) Scolex showing four suckers and rostellum with multiple rows of hooklets; (B) Mature proglottid showing two genital pores, one on either side; and (C) Eggs found in clusters enclosed in a membrane

Box 6: Parasites requiring as intermediate host

- *Hymenolepis diminuta*
- *Dipylidium caninum*
- *Hymenolepis nana* (murine strain)

- Gravid proglottids are passed out of the anus of the host singly or in groups.

Life Cycle

Definitive host: Dogs, cats and rarely man.

Intermediate host: Fleas (**Box 6**).

- Man acquires infection by ingestion of flea harboring cysticeroid larva.
- The eggs or proglottids passed in feces of dogs and cats are eaten by larval stages of dog and cat fleas, *Ctenocephalides canis* and *C. felis*.
- The embryo develops into a tailed cysticeroid larva.
- When the adult fleas containing the larvae are eaten by dogs, cats, or rarely humans, infection is transmitted.

Clinical Features

Human infection is generally asymptomatic, but the actively motile proglottids passed in stools may raise an alarm.

Diagnosis

The diagnosis is made by detection of proglottids or eggs in stool.

Treatment

The drug of choice is praziquantel.

REVIEW QUESTIONS

- Describe briefly:
 - General characters of cestodes
 - Classification of cestodes
- Short notes on:
 - Echinococcus granulosus*
 - Hymenolepis nana*
 - Diphyllobothrium latum*
 - Hydatid cyst
 - Casoni's test
 - Sparganosis
 - Coenurosis
 - Dipylidium caninum*
 - Cysticercus cellulosae*
 - Neurocysticercosis
- Describe morphology, life cycle and laboratory diagnosis of:
 - Taenia solium*
 - Taenia saginata*
 - Echinococcus granulosus*
- Differentiate between:
 - Taenia solium* and *Taenia saginata*
 - Taenia saginata* and *Taenia saginata asiatica*

MULTIPLE CHOICE QUESTIONS

- Autoinfection is a mode of transmission in
 - Trichinella*
 - Cysticercosis*
 - Ancylostoma*
 - Ascaris*
- Pigs are reservoir for
 - Taenia solium*
 - Diphyllobothrium latum*
 - Trichinella spiralis*
 - Ancylostoma*
- On microscopic examination, eggs are seen, but on saturation with salt solution eggs are not seen. The eggs are likely to be of
 - Trichuris trichiura*
 - Taenia solium*
 - Ascaris lumbricoides*
 - Ancylostoma duodenale*
- Which of the following is not a cestodes
 - Diphyllobothrium latum*
 - Taenia saginata*
 - Schistosoma mansoni*
 - Echinococcus granulosus*
- Consumption of uncooked pork is likely to cause which of the following helminthic disease
 - Taenia saginata*
 - Taenia solium*
 - Hydatid cyst
 - Trichuris trichiura*
- All of the following are true about neurocysticercosis, except
 - Not acquired by eating contaminated vegetables
 - Caused by regurgitation of larva
 - Acquired by orofecal route
 - Acquired by eating pork
- The longest tapeworm found in man
 - Diphyllobothrium latum*
 - Taenia saginata*
 - Taenia solium*
 - Echinococcus granulosus*
- Second intermediate host of *Diphyllobothrium latum* is
 - Cyclops
 - Man
 - Snail
 - Fresh water fish
- Dwarf tapeworm refers to
 - Echinococcus granulosus*
 - Loa loa*
 - Hymenolepis nana*
 - Schistosoma mansoni*
- The egg of which of the following parasites consists of polar filaments arising from either end of the embryophore
 - Taenia saginata*
 - Taenia solium*
 - Echinococcus granulosus*
 - Hymenolepis nana*
- Coenurus is the larval form of
 - Taenia solium*
 - Taenia multiceps*
 - Echinococcus granulosus*
 - Echinococcus multilocularis*
- Larval form of *Echinococcus granulosus* is seen in
 - Dog
 - Man
 - Wolf
 - Fox
- The adult worm of *Echinococcus granulosus* contains
 - 3–4 segments
 - 50–100 segments
 - 100–200 segments
 - 1000–2000 segments
- Which skin test is useful for diagnosis of hydatid disease
 - Casoni's test
 - Schick test
 - Dick's test
 - Tuberculin test

Answer

- | | | | | | | |
|------|------|-------|-------|-------|-------|-------|
| 1. b | 2. a | 3. b | 4. c | 5. b | 6. a | 7. a |
| 8. d | 9. c | 10. d | 11. b | 12. b | 13. a | 14. a |

Trematodes: Flukes

■ INTRODUCTION

Trematodes are leaf-shaped unsegmented, flat and broad helminths (hence the name *flake*, from the *Anglo-Saxon* word *floc* meaning *flatfish*). The name *trematode* comes from their having large prominent suckers with a hole in the middle (Greek *trema*: *hole*, *eidos*: *appearance*).

■ CLASSIFICATION OF TREMATODES

Systemic Classification

Trematodes belong to:

Phylum: Platyhelminthes

Class: Trematoda

The detailed systemic classification has been given in **Table 1**.

Classification Based on Habitat

Based on habitat, trematodes can be classified as (**Table 2**):

- Blood flukes
- Liver flukes
- Intestinal flukes
- Lung flukes.

■ FLUKES: GENERAL CHARACTERISTICS

They vary in size from 1 mm to several centimeters. Males are shorter and stouter than females.

- The unique feature of flukes is the presence of two muscular cup-shaped suckers (hence called *distomata*)—the **oral sucker** surrounding the mouth at the anterior end and the **ventral sucker** or *acetabulum* in the middle, ventrally (**Fig. 1**).

Table 1: Zoological classification of trematodes

Superfamily	Family	Genus	Species
Schistosomatoidea	Schistosomatidae	<i>Schistosoma</i>	<ul style="list-style-type: none"> • <i>S. haematobium</i> • <i>S. mansoni</i> • <i>S. japonicum</i> • <i>S. mekongi</i> • <i>S. intercalatum</i>
Paramphistomatoidea	Zygocotylidae	<ul style="list-style-type: none"> • <i>Gastrodiscoides</i> • <i>Watsonius</i> 	<ul style="list-style-type: none"> • <i>G. hominis</i> • <i>W. watsoni</i>
Echinostomatoidea	Fasciolidae	<ul style="list-style-type: none"> • <i>Fasciola</i> • <i>Fasciolopsis</i> 	<ul style="list-style-type: none"> • <i>F. hepatica</i> • <i>F. buski</i>
Opisthorchioidea	<ul style="list-style-type: none"> • Opisthorchiidae • Heterophyidae 	<ul style="list-style-type: none"> • <i>Opisthorchis</i> • <i>Clonorchis</i> • <i>Heterophyes</i> • <i>Metagonimus</i> 	<ul style="list-style-type: none"> • <i>O. felineus</i> • <i>O. viverrini</i> • <i>C. sinensis</i> • <i>H. heterophyes</i> • <i>M. yokogawai</i>
Plagiorchioidea	Paragonimidae	<i>Paragonimus</i>	<i>P. westermani</i>

- All schistosomes live in **venous plexuses** in the body of the definitive host, the location varying with the species (**urinary bladder** in *S. haematobium*, **sigmoidorectal** region in *S. mansoni* and **ileocecal region** in *S. japonicum*).

Schistosoma Haematobium

History and Distribution

This vesical blood fluke, formerly known as *bilharzia haematobium*, has been endemic in the Nile valley in Egypt for millenia. Its eggs have been found in the renal pelvis of an Egyptian mummy dating from 1,250–1,000 BC. Schistosome antigens have been identified by enzyme-linked immunosorbent assay (ELISA) in Egyptian mummies of the Predynastic period, 3,100 BC.

- The adult worm was described in 1851 by Bilharz in Cairo. Its life cycle, including the larval stage in the snail, was worked out by Leiper in 1915 in Egypt.
- Although maximally entrenched in the Nile valley, *S. haematobium* is also endemic in most parts of Africa and in West Asia.
- An isolated focus of endemicity in India exists in Ratnagiri district of Maharashtra.
- About 200 million persons are at a risk of infection and 90 million are infected by *S. haematobium* globally.

Habitat

The adult worms live in the vesical and pelvic plexuses of veins.

Morphology

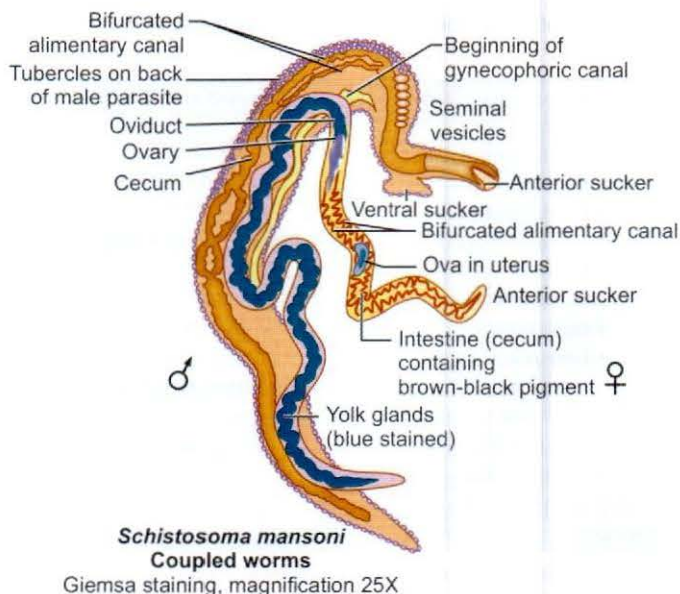
Adult worm:

- The male is 15 mm long by 0.9 mm thick and covered by a thick tuberculate tegument.
- It has **two muscular suckers**: (1) the oral sucker being small and (2) the ventral sucker large and prominent. Beginning immediately behind the ventral sucker and extending to the caudal end is the gynecophoric canal, in which the female worm is held (**Fig. 3**).
- The adult female is **long and slender** (20 mm by 0.25 mm).
- The gravid worm contains 20–30 eggs in its uterus at one time and may pass up to 300 eggs a day.

Egg: The eggs are elongated, brownish yellow (about 150 μm by 50 μm) and nonoperculated. The eggs have characteristic **terminal spine** at one pole (**Fig. 4**).

Mechanism of egg expulsion: The eggs are laid usually in the small venules of the **vesical and pelvic plexuses**, though sometimes they are laid in the mesenteric portal system, pulmonary arterioles and other ectopic sites.

- The eggs are laid one behind the other with the spine pointing posteriorly.



Schistosoma mansoni
Coupled worms
Giemsa staining, magnification 25X

Fig. 3: Structural details of *Schistosoma* (coupled)

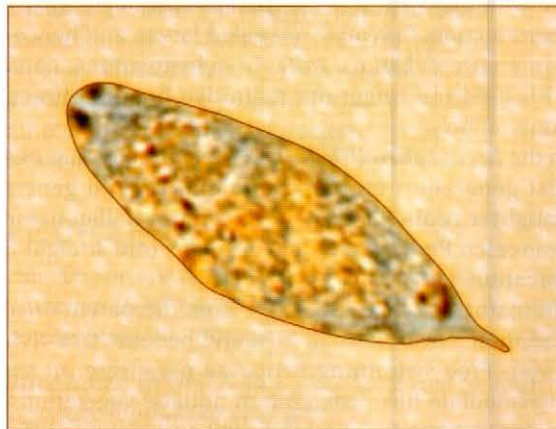


Fig. 4: Egg of *Schistosoma haematobium*

- From the venules, the eggs make their way through the vesical wall by the piercing action of the spine, assisted by the mounting pressure within the venules and a lytic substance released by the eggs.
- The eggs pass into the lumen of the **urinary bladder** together with some extravasated blood.
- They are discharged in the urine, particularly towards the end of micturition.
- For some unknown reasons, the eggs are passed in **urine** more during **midday** than at any other time of the day.
- The eggs laid in **ectopic sites** generally die and evoke local tissue reactions. They may be found, for instance in **rectal biopsies**, but are seldom passed live in feces.

Life Cycle

S. haematobium passes its life cycle in two hosts:

1. **Definitive host:** Humans are the only natural definitive hosts. No animal reservoir is known.
2. **Intermediate host:** Freshwater snails (snail of the genus *Bulinus*).

Infective form: Cercaria larva.

- The eggs that are passed in urine are embryonated and hatch in water under suitable conditions to release the free-living *ciliated miracidia*.
- Miracidia swim about in water and on encountering a suitable intermediate host, penetrate into its tissues and reach its liver (**Fig. 6**). The intermediate hosts are snails of *Bulinus* species in Africa. In India, the intermediate host is the limpet, *Ferrissia tenuis*.

Development in snail: Inside the snail, the miracidia lose their cilia and in about 4–8 weeks, successively pass through the stages of the first and second generation sporocysts (**Fig. 6**).

- Large numbers of *cercariae* are produced by asexual reproduction within the second generation sporocyst. The cercaria has an elongated ovoid body and *forked tail* (*furcocercous cercaria*) (**Fig. 5**).
- The cercariae escape from the snail into water.
- Swarms of cercariae swim about in water for 1–3 days. Persons become infected by contact with water containing cercariae during bathing. **Suckers** and **lytic substances** secreted by cercariae helps them to penetrate intact skin.

Development in man: After penetrating the skin, the cercariae lose their tails and become schistosomulae which travel via peripheral venules to systemic circulation (**Fig. 6**).

- They then start a long migration, through the vena cava into the right heart, the pulmonary circulation, the left heart and the systemic circulation, ultimately reaching the liver.
- In the intrahepatic portal veins, the schistosomulae grow and become sexually differentiated adolescents about 20 days after skin penetration.
- They then start migrating against the bloodstream into the inferior mesenteric veins, ultimately reaching the *vesical*

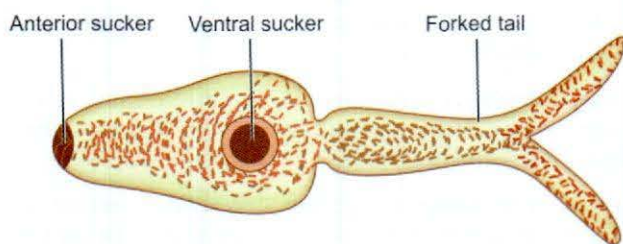


Fig. 5: Cercaria larva of *Schistosoma* spp.

and *pelvic venous plexuses*, where they mature, mate and begin laying eggs.

- Eggs start appearing in urine usually 10–12 weeks after cercarial penetration.
- The adult worms may live for 20–30 years.

Pathogenicity and Clinical Features

Clinical illness caused by schistosomes can be classified as acute and chronic based on the stages in the evolution of the parasite.

Acute schistosomiasis:

- During skin penetration of cercariae, intense irritation and skin rash may develop at the site of cercarial penetration (*swimmer's itch*). It is particularly severe when infection occurs with cercariae of nonhuman schistosomes.
- Anaphylactic or toxic symptoms may develop during incubation period due to liberation of toxic metabolites by schistosomules.
- Migration of schistosomulae into lungs may cause cough and mild fever.

Chronic schistosomiasis:

- Egg deposition in urinary bladder causes mucosal damages leading to painless hematuria, dysuria and proteinuria, particularly in children in endemic areas.
- There is inflammation of the urinary bladder due to release of soluble antigens from the eggs causing pseudoabscesses in the surrounding tissues.
- Initially the trigone is involved but ultimately the whole mucosa is inflamed, ulcerated and thickened. There is heavy infiltration of macrophages, lymphocytes, eosinophils and fibroblasts.
- Many of the eggs die and become calcified eventually producing fibrosis of vesical mucosa and formation of egg granulomas (*sandy patches*).
- Fibrosis may cause obstructive uropathies like hydronephrosis and hydroureter.
- Chronic schistosomiasis has been associated with **urinary bladder carcinoma** (**Box 3**).
- Chronic cystitis may develop due to secondary bacterial infection.
- Chronic infection may result in *calculus formation*.

Involvement of other organs during schistosomiasis:

- Lungs and central nervous system (spinal cord), skin and genital organs may be involved.

Box 3: Parasites associated with malignancy

- *Schistosoma haematobium*: Bladder carcinoma
- *Clonorchis sinensis*: Bile duct carcinoma
- *Opisthorchis viverrini*: Bile duct carcinoma

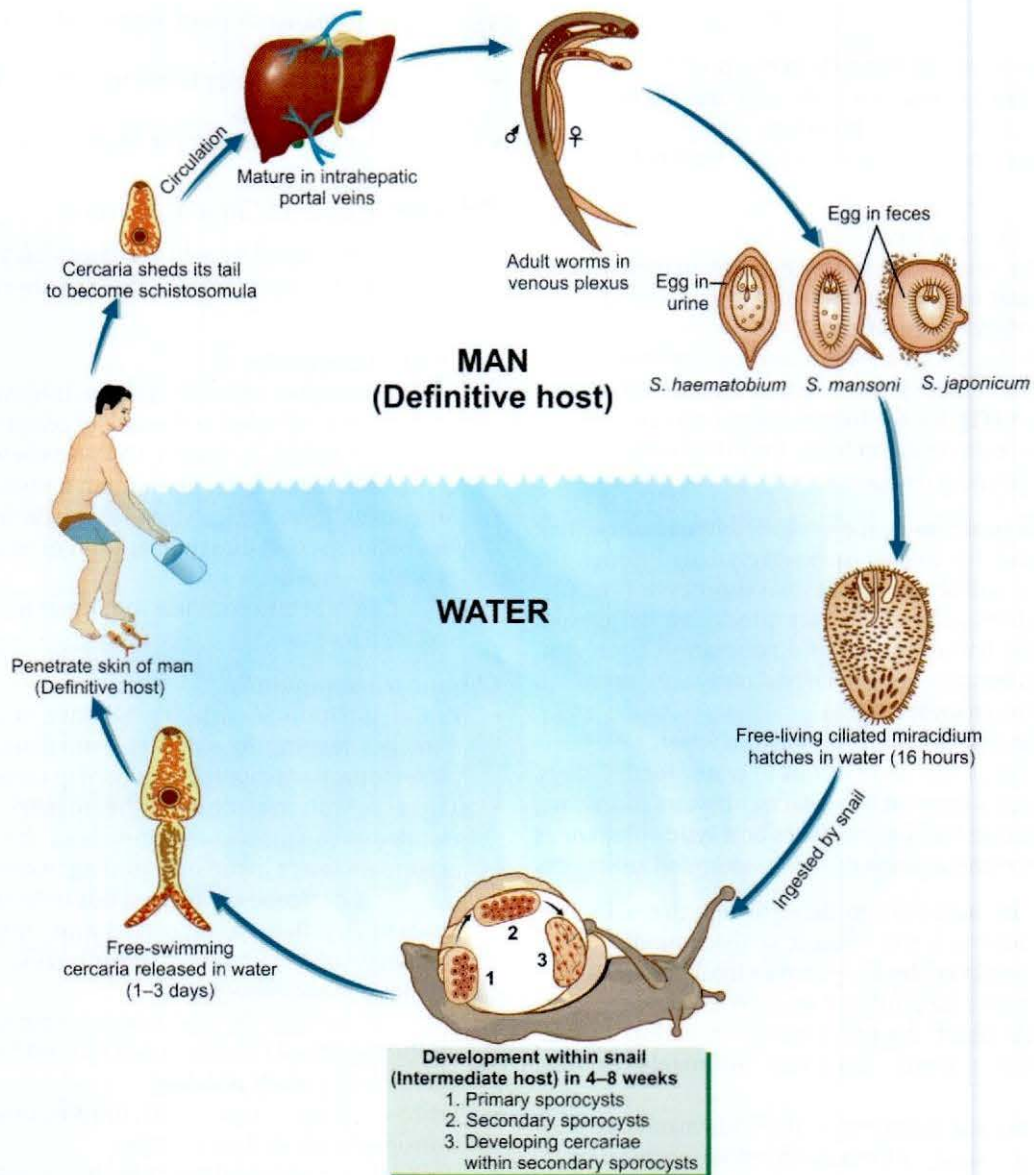


Fig. 6: Life cycle of *Schistosoma* spp.

- Ectopic lesions in the spinal cord produce a transverse myelitis-like syndrome.
- Schistosomiasis favors urinary carriage of typhoid bacilli.

Laboratory Diagnosis

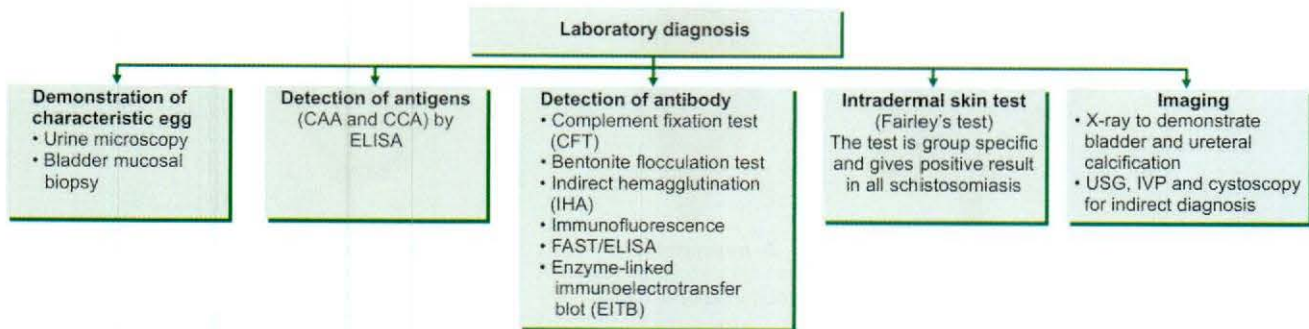
Urine microscopy: The eggs with characteristic terminal spines can be demonstrated by microscopic examination of centrifuged deposits of urine or by filtration of a known volume of urine through nucleopore filters (**Flow chart 1**).

- Eggs are more abundant in the blood and pus passed by patients at the end of micturition.

- Nucleopore filtration method provides quantitative data on the intensity of infection.
- Eggs can also be seen in the seminal fluid in males and occasionally in feces.

Histopathology: Schistosome infection may also be diagnosed by demonstrating its eggs in bladder mucosal biopsy and **rectal biopsy**.

Detection of antigen: Another diagnostic method is by detection of specific schistosome antigens in serum or urine. Two circulating antigens related to gut of adult schistosomes: (1) circulating anodic antigen (CAA) and (2) circulating

Flow chart 1: Laboratory diagnosis of *Schistosoma haematobium*

Abbreviations: CAA, circulating anodic antigen; CCA, circulating cathodic antigen; ELISA, enzyme-linked immunosorbent assay; FAST, falcon assay screening test; IVP, intravenous pyelogram; USG, ultrasonography

cathodic antigens (CCAs) can be demonstrated by dipstick assay and ELISA.

The test is very sensitive and specific, but is available only in specialized laboratories.

Soluble egg antigens (SEAs) can be demonstrated in serum (**Flow chart 1**).

Detection of antibody: Several serological tests have been described for detection of specific antibody, but are not very useful as they cannot differentiate between present and past infection. These include complement fixation test (CFT), bentonite flocculation test, indirect hemagglutination (IHA), immunofluorescence and gel diffusion tests.

Two serological tests for detection of antibodies against *Schistosoma haematobium* adult worm microsomal antigen (HAMA) are: (1) the **falcon assay screening test (HAMAFAST)/ELISA** and (2) HAMA enzyme-linked immunoelectrotransfer blot (**EITB**). Both these tests are highly sensitive and specific (95% sensitive and 99% specific) (**Flow chart 1**).

Intradermal skin test (Fairley's test): These allergic skin tests are group-specific. The test uses antigen from larvae, adult forms and eggs of schistosomes from artificially infected snails and infected laboratory animals.

Imaging:

- X-ray of the abdomen may show bladder and ureteral calcification.
- Ultrasonography (USG) is also useful in diagnosing *S. haematobium* infection. USG may show hydroureter and hydronephrosis.
- Intravenous pyelogram (IVP) and cystoscopy are also useful in indirect diagnosis of the disease.

Treatment

Praziquantel (40–60 mg per kg in divided doses in a single day) is the drug of choice.

Metriphonate is the alternative drug of choice in schistosomiasis due to *S. haematobium* (7.5 mg/kg weekly for 3 weeks).

Prophylaxis

Prophylactic measures include:

- Eradication of the intermediate molluscan hosts by using molluscicides.
- Prevention of environmental pollution with urine and feces.
- Effective treatment of infected persons.
- Avoid swimming, bathing and washing in infected water.

Schistosoma Mansoni

History and Distribution

In 1902, **Manson** discovered eggs with lateral spines in the feces of a West Indian patient that led to the recognition of this second species of human schistosomes. It was, therefore named *S. mansoni*.

- It is widely distributed in Africa, South America and the Caribbean islands.

Habitat

Adult worm lives in the **inferior mesenteric vein**.

Morphology

S. mansoni resembles *S. haematobium* in morphology and life cycle, except:

- The adult worms are smaller and their integuments studded with prominent coarse **tubercles**.
- In the gravid female, the uterus contains very few eggs, usually 1–3 only.

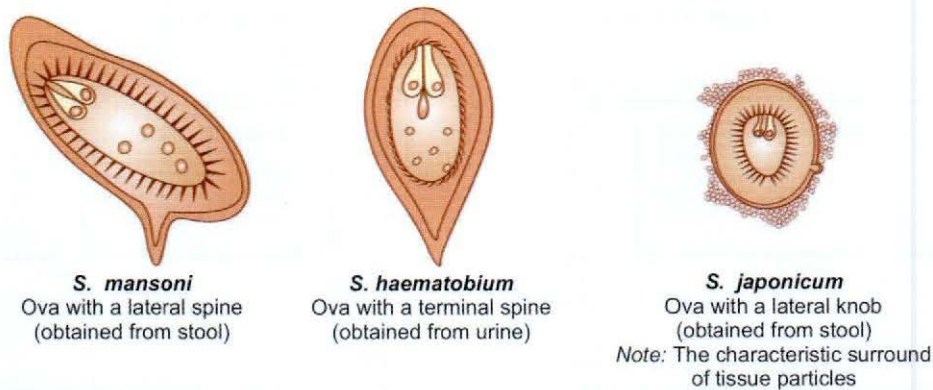


Fig. 7: Schematic diagram to show distinguishing features of eggs of *S. mansoni*, *S. haematobium* and *S. japonicum*

- The **prepatent period** (the interval between cercarial penetration and beginning of egg laying) is 4–5 weeks.
- The egg has a characteristic **lateral spine** (Fig. 7), more near to the rounded posterior end. The eggs are *nonoperculated* and *yellowish brown*.

Life Cycle

Definitive host: Humans are the only natural definitive hosts, though in endemic areas monkeys and baboons have also been found infected.

Intermediate host: Planorbid freshwater *snails* of the genus *Biomphalaria*.

Infective form: *Fork-tailed cercaria*.

In humans, the schistosomulae mature in the liver and the adult worms move against the bloodstream into the venules of the *inferior mesenteric* group in the *sigmoidorectal* area. Eggs penetrate the gut wall, reach the colonic lumen and are shed in feces.

Pathogenicity and Clinical Features

- **Cercarial dermatitis:**
 - *Following skin penetration by cercariae:* A pruritic rash called as cercarial dermatitis or swimmers itch may develop locally. It is a self-limiting disease.
- **Katayama fever:**
 - After 4–8 weeks of cercarial invasion a serum sickness like illness may happen during production of eggs.
 - It results from high worm load and egg antigen stimuli which leads to formation of immune complexes. Sign and symptoms include high fever, rash, arthralgia, hepatosplenomegaly, lymphadenopathy and eosinophilia.
- **Intestinal bilharziasis:**
 - During the stage of egg deposition in small intestine, patients may develop pain in abdomen and bloody

dysentery, which may go on intermittently for many years.

- The eggs deposited in the intestinal wall may cause **microabscesses**, granulomas, hyperplasia and eventual fibrosis. Egg granulomas are found in the distal part of the colon and rectum. Ectopic lesions include hepatosplenomegaly and periportal fibrosis, portal hypertension, as some of the eggs are carried through portal circulation into liver.
- **Portal hypertension** may cause gastrointestinal hemorrhage.

Laboratory Diagnosis

Stool microscopy: Eggs with lateral spines may be demonstrated microscopically in stools. **Kato-Katz thick smear** or other concentration methods may be required when infection is light. Kato-Katz thick smear provides quantitative data on the intensity of infection, which is of value in assessing the degree of tissue damage and monitoring the effect of chemotherapy.

Rectal biopsy: Proctoscopic biopsy of rectal mucosa may reveal eggs when examined as fresh squash preparation between two slides.

Serological diagnosis: Serological diagnosis by detecting schistosomal antigen and antibody is similar to that of *S. haematobium*.

Imaging: Ultrasonography is useful to detect hepatosplenomegaly and periportal fibrosis.

Blood examination: Blood examination may reveal eosinophilia and increased levels of alkaline phosphatase.

Treatment

Praziquantel (single oral dose 40 mg/kg) is the drug of choice. Oxamniquine (single oral dose 15 mg/kg) is also effective. It damages the tegument of male worm and thereby, makes

the worm more susceptible to lethal action of the immune system.

Prophylaxis

Same as *S. haematobium*.

Schistosoma Japonicum

Common Name

Oriental blood fluke.

Distribution

S. japonicum is found in the Far East, Japan, China, Taiwan, Philippines and Sulawesi.

Habitat

The adult worms are seen typically in the venules of the superior mesenteric vein draining the ileocecal region. They are also seen in the intrahepatic portal venules and hemorrhoidal plexus of veins.

Morphology

Morphologically, they are similar to the schistosomes described earlier except:

- The adult male is comparatively slender (0.5 mm thick) and does not have cuticular tuberculations.

- In the gravid female, the uterus contains as many as 100 eggs at one time and up to 3,500 eggs may be passed daily by a single worm.
- The prepatent period is 4–5 weeks.
- The eggs are smaller and more spherical than those of *S. haematobium* and *S. mansoni*. The egg has *no spine*, but shows a lateral small rudimentary knob (**Fig. 7**).

Differentiating features between the three species of *Schistosoma* are illustrated in **Table 3**.

Life Cycle

Life cycle of *S. japonicum* is similar to *S. haematobium* with the following exceptions:

Definitive host: Man is the definitive host but in endemic areas, natural infection occurs widely in several domestic animals and rodents, which act as reservoirs of infection.

Intermediate host: Amphibian snails of the genus *Oncomelania*.

Infective form for humans: Fork-tailed cercaria.

- Eggs deposited in the *superior mesenteric venules* penetrate the gut wall and are passed in feces.
- They hatch in water and the *miracidia* infect the *intermediate hosts*, amphibian *snails* of the genus *Oncomelania*.
- The fork-tailed cercaria, which escapes from the snails is the *infective form* for men and other definitive hosts.

Table 3: Differentiating features of *S. haematobium*, *S. mansoni* and *S. japonicum*

	<i>Schistosoma haematobium</i>	<i>Schistosoma mansoni</i>	<i>Schistosoma japonicum</i>
Habitat	Veins of the vesical and pelvic plexuses, less commonly in portal vein and its mesenteric branches	Inferior mesenteric vein and its branches	Superior mesenteric vein and its branches
Morphology			
Size: Male	• 1.5 cm × 1 mm	• 1 cm × 1 mm	• 1.2–2 cm × 0.5 mm
Female	• 2 cm × 0.22 mm	• 1.4 cm × 0.25 mm	• 2.6 cm × 0.3 mm
Integument	• Finely tuberculated	• Grossly tuberculated	• Nontubercular
Number of testes	• 4–5 in groups	• 8–9 in a zigzag row	• 6–7 in a single file
Ovary	• In the posterior one-third of the body	• In the anterior half of the body	• In the middle of the body
Uterus	• Contains 20–30 eggs	• 1–3 eggs	• 50 or more eggs
Egg	Elongated with terminal spine	Elongated with lateral spine	Round with small lateral knob
Cephalic glands in cercariae	Two pairs oxyphilic and three pairs basophilic	Two pairs oxyphilic and four pairs basophilic	Five pairs oxyphilic, no basophilic
Distribution	Africa, Near East, Middle East and India	Africa and South America	China, Japan and Far East (oriental)
Definitive host	Man	Man	Man (mainly) domestic animals and rodents (which act as reservoir of infection)
Intermediate host	Snail of genus <i>Bulinus</i>	Snail of genus <i>Biomphalaria</i>	Amphibian snail of genus <i>Oncomelania</i>

Pathogenicity and Clinical Features

Disease caused by *S. japonicum* is also known as *oriental schistosomiasis* or *Katayama disease*.

- Pathogenesis is almost similar to that of *S. mansoni*. But the disease is more **severe** due to higher egg production.
- During the acute phase of the disease, *Katayama fever* is similar to that seen in *S. mansoni*.
- **Chronic illness** is characterized by intestinal mucosal hyperplasia, hepatosplenomegaly and portal hypertension. Liver is hard and shows periportal fibrosis (**clay pipestem fibrosis**). Portal hypertension leads to esophageal varices and gastrointestinal bleeding. Intestinal disease manifests as colicky abdominal pain, bloody diarrhea and anemia (**Box 4**).
- **Central nervous system** and **lung** involvement (cor pulmonale) may occur in 2–4% of cases. Parietal lobe of the brain and spine are commonly affected. Severe epileptic seizures may be observed in these patients.

Laboratory Diagnosis

Similar to that of *S. mansoni*.

Treatment

S. japonicum infection is more resistant to treatment than other schistosomiasis. A prolonged course of intravenous tartar emetic gives good results. Praziquantel is the drug of choice.

Prophylaxis

Same as *S. haematobium*.

Schistosoma Intercalatum

S. intercalatum was first noted in 1934 in West-Central Africa.

- The eggs are fully embryonated **without any operculum** having terminal spines, but are passed exclusively in stools. The eggs are **acid-fast**.
- It produces few symptoms involving the mesenteric portal system.

Box 4: Parasites leading to bloody diarrhea

- Intestinal *Schistosoma* species:
 - *S. japonicum*
 - *S. mansoni*
 - *S. intercalatum*
 - *S. mekongi*.
- *Trichuris trichiura*
- *Entamoeba histolytica*
- *Balantidium coli*.

- Diagnosis is established by detection of the egg in feces and rectal biopsy.
- Praziquantel is the drug of choice.

KEY POINTS OF SCHISTOSOMES

- Schistosomes are **dioecious**, sexes are separate.
- **Habitat:** In the mesenteric venous plexus (*S. mansoni* and *S. japonicum*) and vesical, and prostatic venous plexus (*S. haematobium*).
- Leaf-like unsegmented body with two cup-like suckers with delicate spines.
- Intestine is bifurcated (inverted Y-shaped).
- Male is broader than female.
- They produce elongated nonoperculated eggs containing ciliated embryo, miracidium.
- **Definitive host:** Man.
- **Intermediate host:** Freshwater snails.
- **Infective form:** Fork-tailed cercariae.
- **Clinical features:** Swimmer's itch, Katayama fever, hematuria and portal hypertension.
- **Diagnosis:** Detection of eggs in urine or stool, biopsy, imaging, and detection of antigen and antibody.
- **Treatment:** Praziquantel is the drug of choice.
- **Prophylaxis:** Avoidance of bathing in infected water and eradication of snail.

Schistosoma Mekongi

This species first recognized in 1978 is found in Thailand and Cambodia, along the Mekong river.

- It is closely related to *S. japonicum* but is slightly smaller and round.
- Man and dog are the definitive host.
- Man acquires infection in the same way as in *S. japonicum*.
- Hepatosplenomegaly and ascites are the common clinical finding.

HERMAPHRODITIC FLUKES: LIVER FLUKES

The adult forms of all hermaphroditic flukes infecting man reside in the lumen of the biliary, intestinal, or respiratory tracts. This location gives the flukes suitable protection from host defense mechanisms and also facilitates dispersal of eggs to the environment.

- Flukes inhabiting the human biliary tract are *Clonorchis sinensis*, *Fasciola hepatica*, less often *Opisthorchis* species, and rarely, *Dicrocoelium dendriticum*.

Fasciola Hepatica

Common Name

Sheep liver fluke.

History and Distribution

F. hepatica was the first trematode that was discovered more than 600 years ago in 1379 by Jehan de Brie.

- It was named by Linnaeus in 1758.
- It is the **largest** and **most common** liver fluke found in man, however its primary host is the sheep and to a less extent, cattle.
- It causes the economically important disease, “**liver rot**”, in sheep.
- It is worldwide in distribution, being found mainly in sheep-rearing areas.
- In India, few cases reported from North India and North Eastern part of India including Uttar Pradesh (UP), Bihar and Assam.
- *F. gigantica* is more prevalent in India than *F. hepatica*.

Habitat

The parasite resides in the **liver** and **biliary** passages of the definitive host.

Morphology

Adult worm:

- It is large in size, flat leaf-shaped fluke measuring 30 mm long and 15 mm broad, gray or brown in color.
- It has a conical projection anteriorly containing an oral sucker and is rounded posteriorly (**Figs 8A and B**).
- The adult worm lives in the biliary tract of the definitive host for many years—about 5 years in sheep and 10 years in humans.
- Like all other trematodes, it is hermaphrodite.

Egg: The eggs are large, **ovoid**, **operculated**, **bile-stained** and about 140 μm by 80 μm in size (**Box 5 and Fig. 9**).

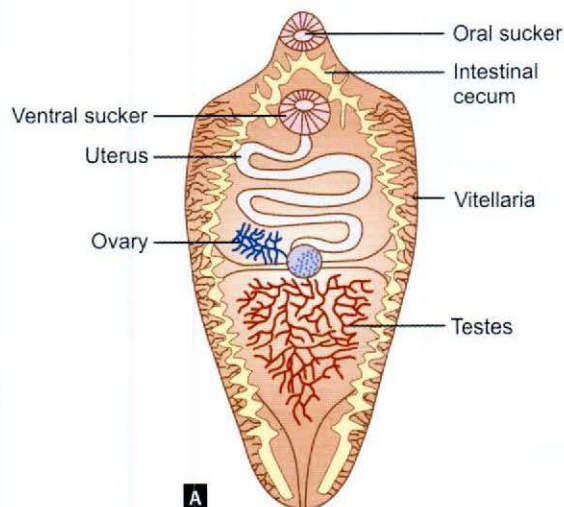
- Eggs contain an immature larva, the miracidium.
- Eggs do not float in saturated solution of common salt.
- Eggs of *F. hepatica* and *Fasciolopsis buski* cannot be differentiated.
- Eggs are unembryonated when freshly passed.

Box 5: Parasites with operculate eggs

- *Fasciola hepatica*
- *Fasciola gigantica*
- *Fasciolopsis buski*
- *Clonorchis sinensis*
- *Paragonimus westermani*
- *Gastrodiscoides hominis*
- *Opisthorchis felineus*
- *Opisthorchis viverrini*
- *Heterophyes heterophyes*
- *Diphyllbothrium latum*.

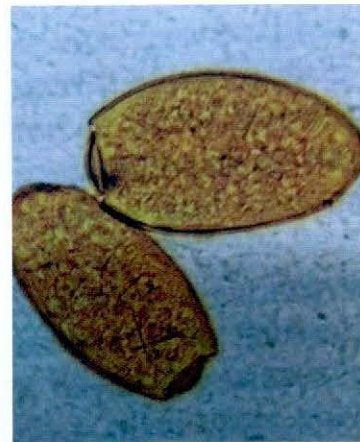

Fig. 9: Egg of *Fasciola hepatica*



Figs 8A and B: (A) *Fasciola hepatica*; and (B) Specimen showing *Fasciola hepatica*

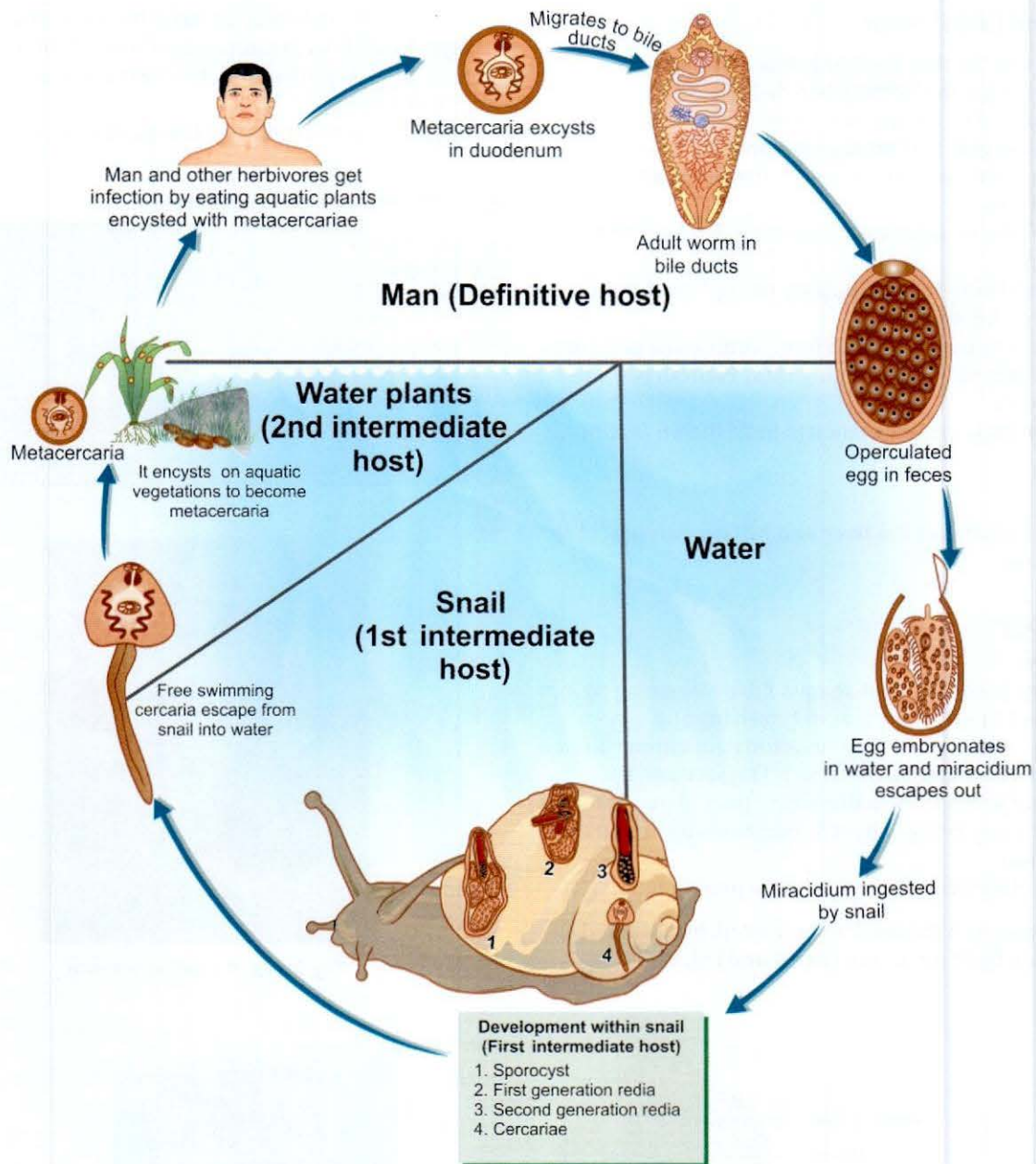


Fig. 10: Life cycle of *Fasciola hepatica*

Life Cycle

F. hepatica passes its life cycle in one definitive host and two intermediate hosts.

Definitive host: Sheep, goat, cattle and man.

Intermediate host: Snails of the genus *Lymnaea* and *Succinea*. Encystment occurs on aquatic plants, which act as *second intermediate host*.

Mode of infection: The definitive host, sheep and man, get infection by ingestion of *metacercariae* encysted on aquatic vegetation.

- Adult worm lives in the *biliary passage* of sheep or man. Eggs are laid in the biliary passages and are shed in feces.
- The embryo matures in water in about 10 days and the *miracidium* escapes. It penetrates the tissues of first intermediate host, snails of the genus *Lymnaea* (Fig. 10).

Box 6: Parasites with aquatic vegetations as the source of infection

- *Fasciola hepatica*
- *Fasciolopsis buski*
- *Gastrodiscoides hominis*
- *Watsonius watsoni*.

- In snail, the miracidium progresses through the **sporocyst** and the **first and second generation redia** stages to become the cercariae in about 1–2 months.
- The **cercariae** escape into the water and encyst on aquatic vegetation or blades of grass to become metacercariae, which can survive for long periods (**Box 6**).
- Sheep, cattle, or humans eating watercress or other water vegetation containing the metacercaria become infected.
- The metacercariae excyst in the duodenum of the definitive host and pierce the gut wall to enter the peritoneal cavity.
- They penetrate the Glisson's capsule, traverse the liver parenchyma, and reach the biliary passages, where they mature into the adult worms in about 3–4 months (**Fig. 10**).

Pathogenicity

- **Fascioliasis** differs from clonorchiasis in that *F. hepatica* is larger and so causes more mechanical damage. In traversing the liver tissue, it causes parenchymal injury. As humans are not its primary host, it causes more severe inflammatory response. Some larvae penetrate right through the liver and diaphragm ending up in the lung.
- **In acute phase** during the migration of the larva, patients present with fever, right upper quadrant pain, eosinophilia and tender hepatomegaly.
- **In chronic phase**, patients may develop biliary obstruction, biliary cirrhosis, obstructive jaundice, cholelithiasis and anemia. No association to hepatic malignancy has been ascribed to *fascioliasis*.
- Occasionally, ingestion of raw liver of infected sheep results in a condition called **halzoun** (meaning **suffocation**). The adult worms in the liver attach to the pharyngeal mucosa, causing **edematous congestion** of the pharynx and surrounding areas, leading to dyspnea, acute dysphagia, deafness and rarely, asphyxiation. However, this condition is more often due to pentastome larvae. Halzoun is particularly common in Lebanon and other parts of the Middle East and North Africa.

Diagnosis

Stool microscopy: Demonstration of eggs in feces or aspirated bile from duodenum is the best method of diagnosis. Eggs of *F. hepatica* and *F. buski* are indistinguishable.

Blood picture: It reveals eosinophilia.

Serodiagnosis: Serological tests such as immunofluorescence, ELISA, immunoelectrophoresis and complement fixation are helpful in lightly infected individuals for detection of specific antibody. ELISA becomes positive within 2 weeks of infection and is negative after treatment. In chronic fascioliasis, *Fasciola* coproantigen may be detected in stool.

Imaging: Ultrasonography, computed tomography (CT) scan, endoscopic retrograde cholangiopancreatography (ERCP) and percutaneous cholangiography may be helpful in diagnosis.

Treatment

Oral **triclabendazole** (10 mg/kg once) is the treatment of choice.

- Alternative drug is **bithionol** (30–50 mg for 10–15 days).
- Prednisolone at a dose of 10–20 mg/kg is used to control toxemia.

Prophylaxis

Fascioliasis can be prevented by:

- Health education.
- Control of snails.
- Proper disposal of human, sheep and cattle feces.
- Proper disinfection of watercresses and other water vegetations before consumption.

KEY POINTS OF FASCIOLA HEPATICA

- Largest and most common liver fluke.
- Large leaf-shaped with a dorsoventrally flattened body.
- Hermaphroditic parasite.
- Eggs are ovoid, operculated and bile-stained.
- **Definitive host:** Primary definitive host is sheep, but it is also found in biliary tract of man.
- **First intermediate host:** Fresh water snails (*Lymnaea*).
- **Second intermediate host:** Aquatic vegetations.
- **Infective form:** Metacercariae encysted on raw aquatic vegetations.
- **Clinical features:** Acute phase—fever, right upper quadrant pain and hepatomegaly. Chronic phase—biliary obstruction, obstructive jaundice, cholelithiasis and anemia.
- **Diagnosis:** Detection of eggs in stool and aspirated bile, USG, ERCP and ELISA.
- **Treatment:** Oral triclabendazole or bithionol.
- **Prophylaxis:** Preventing pollution of water with feces and proper disinfection.

Dicrocoelium Dendriticum

Also known as the “**lancet fluke**” because of its shape, *D. dendriticum* is a very common biliary parasite of sheep and other herbivores in Europe, North Africa, Northern Asia and parts of the Far East.

Definitive Host

Sheep and other herbivores.

First Intermediate Host

Snails.

Second Intermediate Host

Ants of genus *Formica*.

- Eggs passed in feces of sheep are ingested by land snails.
- Cercariae appear in slime balls secreted by the snails and are eaten by ants of the genus *Formica*, in which metacercariae develop.
- Herbivores get infected when they accidentally eat the ants while grazing.
- Reports of human infection have come from Europe, Middle East and China.
- However, spurious infection is more common. In the latter, the eggs can be passed in feces for several days by persons eating infected sheep liver.
- *Eurytrema pancreaticum*, a related fluke is commonly present in the pancreatic duct of cattle, sheep and monkeys. Occasional human infection has been noticed in China and Japan.

Clonorchis Sinensis

Common Name

The **Chinese liver fluke** and oriental liver fluke.

History and Distribution

C. sinensis was first described in 1875 by **McConnell** in the biliary tract of a Chinese carpenter in Calcutta Medical College Hospital.

- Complete life cycle of *Clonorchis* was worked out by Faust and Khaw in 1927.
- Human *clonorchiasis* occurs in Japan, Korea, Taiwan, China and Vietnam, affecting about 10 million persons.

Habitat

Adult worm lives in the **biliary tract** and sometimes in the **pancreatic duct**.

Morphology

Adult worm: It has a flat, transparent, spatulate body; pointed anteriorly and rounded posteriorly (**Fig. 11**).

- It is 10–25 mm long and 3–5 mm broad.
- The adult worm can survive in the biliary tract for 15 years or more.
- The hermaphroditic worm discharges eggs into the bile duct.

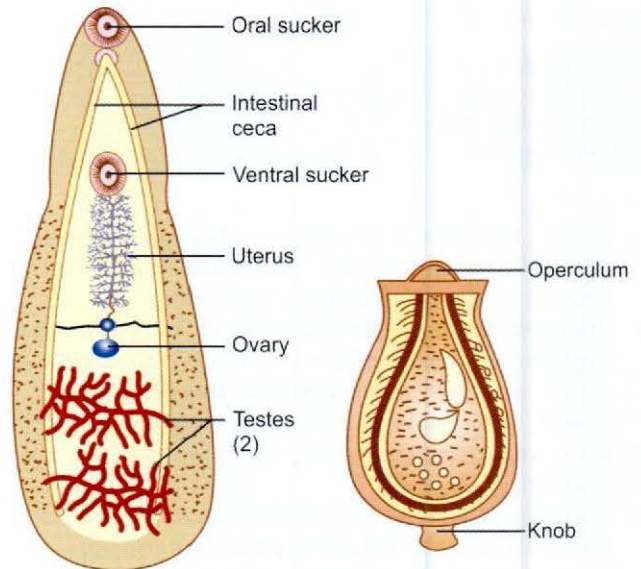


Fig. 11: Adult worm and egg of *Clonorchis sinensis*

Eggs: Eggs are **flask-shaped**, 35 μm by 20 μm with a yellowish-brown (bile-stained) shell.

- It is operculated at one pole and possesses a **tiny knob** at the other pole and a small hook-like spine at the other (**Fig. 11**).
- Eggs do not float in saturated solution of common salt.
- The eggs passed in feces contain the *ciliated miracidia*.

Life Cycle

Definitive host: Humans are the principal definitive host, but dogs and other fish-eating canines act as reservoir hosts.

Intermediate hosts: Two intermediate hosts are required to complete its life cycle, the first being *snail* and the second being *fish*.

Infective form: Metacercaria larva.

Mode of infection: Man acquires infection by eating undercooked freshwater fish carrying metacercariae larvae.

- *Clonorchis* eggs although embryonated do not hatch in water, but only when ingested by suitable species of **operculate snails** (first intermediate host), such as *Parafossarulus*, *Bulimus*, or *Alocinma* species.
- The miracidium develops through the **sporocyst** and **redia** stages to become the lophocercus cercaria with a large fluted tail in about 3 weeks (**Fig. 12**).
- The cercariae escape from the snail and swim about in water, waiting to get attached to the second intermediate host, suitable freshwater fish of the Carp family.
- The cercariae shed their tails and encyst under the scales or in the flesh of the fish to become metacercariae, in about 3 weeks, which are the **infective stage** for humans.

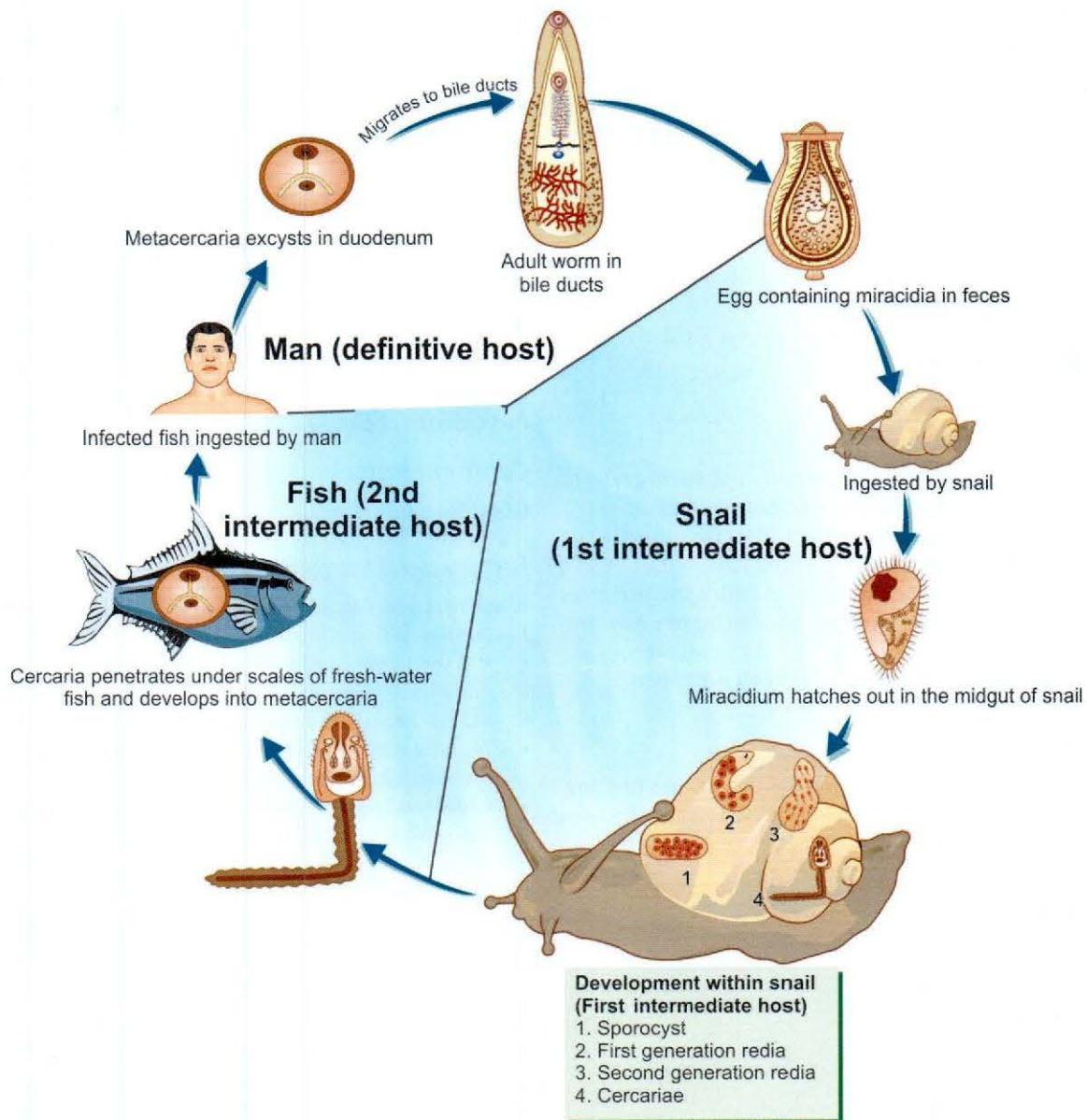


Fig. 12: Life cycle of *Clonorchis sinensis*

- Infection occurs when such fish are eaten raw or inadequately processed by human or other definitive hosts. Frozen, dried, or pickled fish may act as source of infection (Fig. 12).
- Infection may also occur through fingers or cooking utensils contaminated with the metacercariae during preparation of the fish for cooking.
- The metacercariae excyst in the duodenum of the definitive host.
- The *adolescaria* that come out, enter the common bile duct through the *ampulla of Vater* and proceed to the

distal bile capillaries, where they mature in about a month and assume the adult form (Fig. 11).

- Adult worms produce an average of 10,000 eggs per day, which exit the bile ducts and are excreted in the feces.
- The cycle is then repeated.

Pathogenicity

The migration of the larva up the bile duct induces desquamation, followed by hyperplasia, and sometimes, adenomatous changes. The smaller bile ducts undergo cystic dilatation.

- The adult worms may obstruct and block the common bile duct leading to *cholangitis*.
- Patients in the early stage have fever, epigastric pain, diarrhea and tender hepatomegaly. This is followed by biliary colic, jaundice and progressive liver enlargement. Many infections are asymptomatic.
- Chronic infection may result in **calculus formation**.
- A few cases go on to *biliary cirrhosis* and *portal hypertension*.
- Some patients with chronic clonorchiasis tend to become biliary carriers of typhoid bacilli.
- Chronic infection has also been linked with **cholangiocarcinoma**.

Diagnosis

The eggs may be demonstrated in feces (*stool microscopy*) or aspirated bile. They do not float in concentrated saline.

- Several serological tests have been described including complement fixation and gel precipitation but extensive cross-reactions limit their utility. IHA with a saline extract of etherized worms has been reported to be sensitive and specific.
- *Intradermal allergic tests* have also been described.

Treatment

Drug of choice is praziquantel 25 mg/kg, three doses in 1 day.

Surgical intervention may become necessary in cases with obstructive jaundice.

Prophylaxis

Clonorchiasis can be prevented by:

- Proper cooking of fish.
- Proper disposal of feces.
- Control of snails.

Opisthorchis Species

Some species of *Opisthorchis*, which resemble *C. sinensis* can cause human infection.

- *O. felineus*, the **cat liver fluke**, which is common in Europe and the erstwhile Soviet Union, may infect humans.
- Infection is usually asymptomatic but may sometimes cause liver disease resembling *clonorchiasis*.
- *O. viverrini* is common in Thailand, where the civet cat is the reservoir host. Chandler found that 60% of cats in Calcutta, were infected with the parasite and human cases have also been reported from India.
- Most of the infected patients have a low worm burden, so they are asymptomatic.

- *Cholangiocarcinoma* is epidemiologically related to *C. sinensis* infection in China and to *O. viverrini* infection in Northeast Thailand.
- The life cycle and other features of *Opisthorchis* are same as those of *Clonorchis*.

■ INTESTINAL FLUKES

A number of flukes parasitize the human small intestine. These include *Fasciolopsis buski*, *Heterophyes*, *Metagonimus yokogawai*, *Watsonius watsoni* and *Echinostoma*. Only one fluke *Gastrodiscoides hominis*, parasitizes the human large intestine.

Fasciolopsis Buski

Common Name

Giant intestinal fluke.

History and Distribution

It was first described by **Busk** in 1843 in the duodenum of an East Indian sailor, who died in London.

- It is the largest and most common intestinal fluke of man and pigs.
- Mainly found in China and in Southeast Asian countries.
- In India it occurs in Assam, Bengal, Bihar and Odisha.
- Prevalence rate is as high as 22.4% in India.
- **Children** are more prone to infection than adults as they enjoy playing in water.

Habitat

The adult worm lives in the **duodenum** or **jejunum** of pigs and man.

Morphology

Adult worm: The adult is a large fleshy worm, 20–75 mm long and 8–20 mm broad (**Fig. 13**) and 0.5–3 mm in thickness.

- Largest trematode infecting humans: *Fasciolopsis buski*
- Smallest trematode infecting humans: *Heterophyes*

- It is elongated ovoid in shape, with a small oral sucker and a large acetabulum. It has no cephalic cone as in *E. hepatica* (**Fig. 14**).
- The adult worm has a lifespan of about 6 months.
- The two intestinal caeca do not bear any branches (**Fig. 14**).

Eggs:

- The operculated eggs are similar to those of *E. hepatica* (**Fig. 15**).
- Eggs are laid in the lumen of the intestine in large numbers, about 25,000 per day.



Fig. 13: Specimen showing *Fasciolopsis buski*

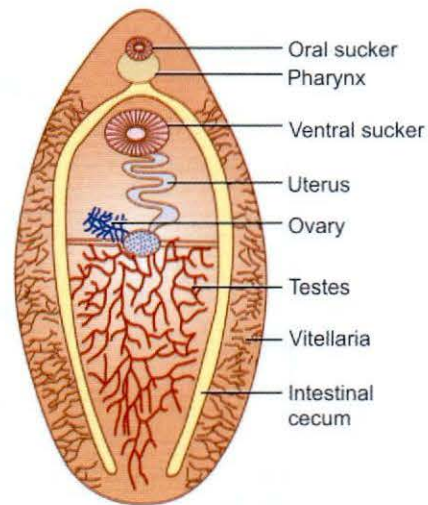


Fig. 14: *Fasciolopsis buski*

Life Cycle

F. buski passes its life cycle in **one definitive host** and **two intermediate host**.

Definitive host: Man and pigs. Pigs serve as a reservoir of infection for man.

First intermediate host: Snails of the genus *Segmentina*.

Second intermediate host: Encystment occurs on *aquatic plants*, roots of the lotus, bulb of the water chestnut which act as *second intermediate host*.

Infective form: Encysted metacercariae on aquatic vegetation.

- The eggs passed in feces of definitive host hatch in water in about 6 weeks, releasing the miracidia which swim about.
- On coming in contact with a suitable molluscan intermediate host, snails of the genus *Segmentina*, miracidia penetrates its tissues to undergo development in the next few weeks as sporocyst, first and second generation rediae and cercariae (Fig. 16).
- The cercariae, which escape from the snail, encyst on the roots of the lotus, bulb of the water chestnut, water hyacinth and on other aquatic vegetations.
- When they are eaten by man, the metacercariae excysts in the duodenum, become attached to the mucosa and develop into adults in about 3 months (Fig. 16).

Pathogenesis

The pathogenesis of fasciolopsiasis is due to traumatic, mechanical and toxic effects.

- Larvae that attach to the duodenal and jejunal mucosa cause inflammation and local ulceration. Intoxication and sensitization also account for clinical illness.

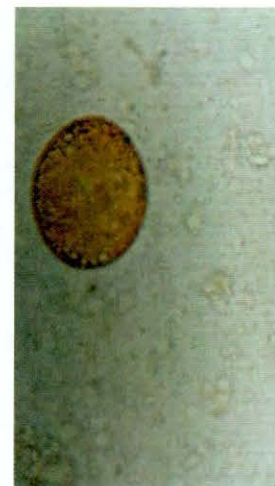

Fig. 15: Egg of *Fasciolopsis buski*

- In heavy infections, the adult worms cause partial obstruction of the bowel, malabsorption, protein-losing enteropathy and impaired vitamin B₁₂ absorption.
- The initial symptoms are diarrhea and abdominal pain.
- Toxic and allergic symptoms appear usually as edema, ascites, anemia, prostration and persistent diarrhea.
- Paralytic ileus is a rare complication.

Laboratory Diagnosis

History of residence in endemic areas suggests the diagnosis, which is confirmed by demonstration of the **egg in feces** or of the worms after administration of a purgative or anthelmintic drug.

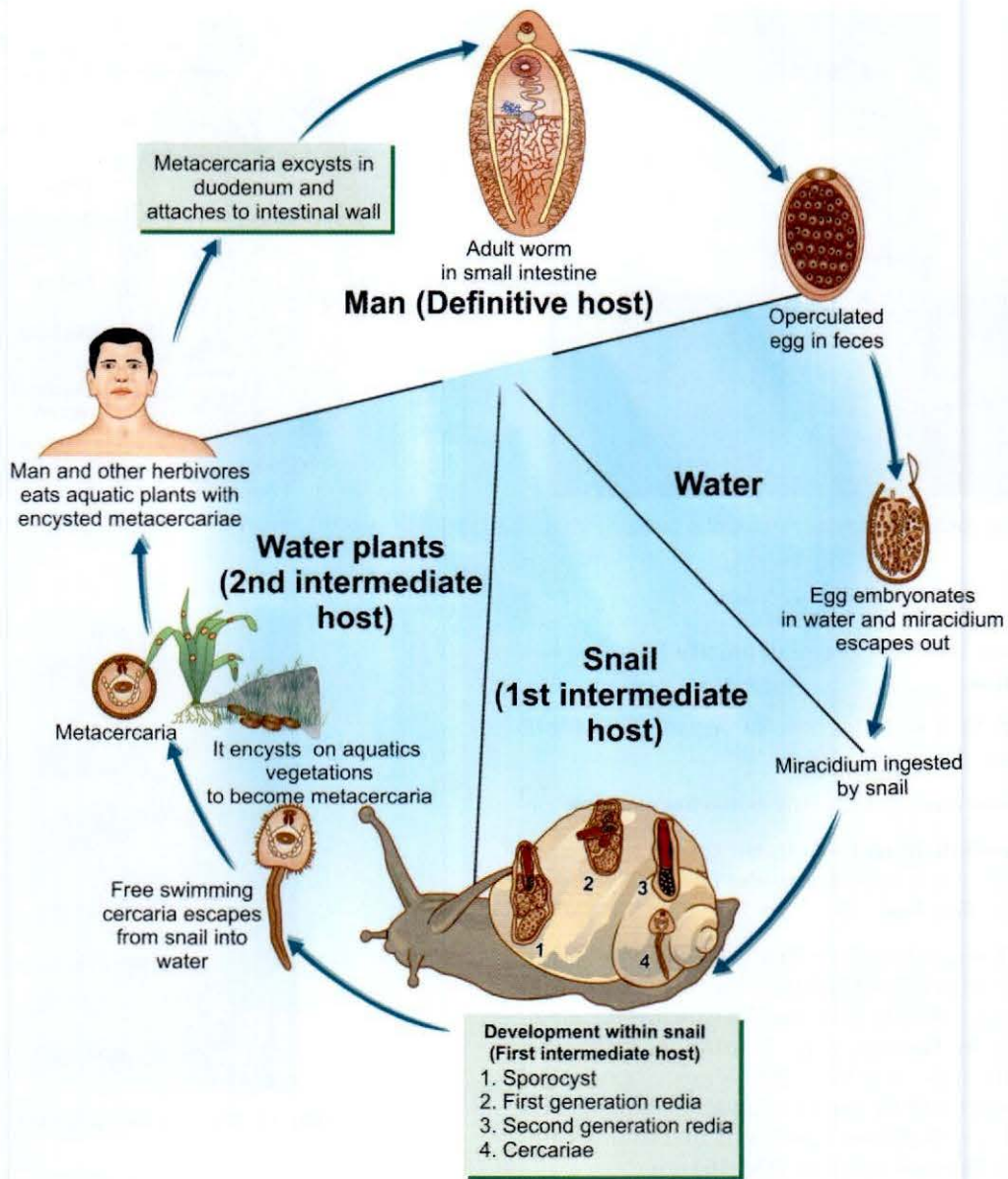


Fig. 16: Life cycle of *Fasciolopsis buski*

Treatment

Drug of choice is **praziquantel**.

- Hexylresorcinol and tetrachloroethylene have also been found useful.

Prophylaxis

- Treatment of infected persons.
- Proper disinfection of water vegetables, by hot water.
- Prevention of pollution of water resources from human and pig feces.

- Community-based praziquantel treatment can be used to control infection.
- Control of snails.

Heterophyes heterophyes

This is the **smallest trematode** parasite of man.

- The infection is prevalent in the Nile delta, Turkey and in the Far East.
- The worm has been reported in a dog in India.
- The adult worm lives in the small intestine and has a lifespan of about 2 months.

Definitive Hosts

Humans, cats, dogs, foxes and other fish-eating mammals.

First Intermediate Host

Snails of the genera *Pironella* and *Cerithidea*.

Second Intermediate Host

Fishes, such as the mullet and tilapia; encystment occurs in fishes.

- Man acquires infection by eating raw or undercooked fishes containing metacercaria.
- In the small intestine, it can induce mucous diarrhea and colicky pains.
- Ectopic lesions may occur as granulomas in myocardium, brain and spinal cord.
- Diagnosis is based on the finding of a minute operculated egg in the stool.

Drug of Choice

Praziquantel.

Metagonimus Yokogawai

It is found in the Far East, Northern Siberia, Balkan states and Spain.

Definitive Hosts

Humans, pigs, dogs, cats and pelicans.

First Intermediate Host

Freshwater snail.

Second Intermediate Host

Fish.

- Definitive hosts are infected by eating raw fish containing the metacercariae.
- Pathogenic effects consist of mucous diarrhea and ectopic lesions in myocardium and central nervous system as in heterophyiasis.

Drug of Choice

Praziquantel.

Watsonius Watsoni

- This trematode infects various primates in Asia and Africa. Normal host is the monkey.
- Eggs are operculated.

- Infection occurs by **ingestion of water plants** containing metacercariae.
- Diagnosis, clinical features, treatment and prophylaxis is same as that of *Heterophyes*.

Echinostoma

Echinostomes are medium-sized flukes causing small intestinal infection of rats and dogs.

- Seen in Japan, Philippines and all along the Far East.
- The characteristic feature is a crown of spines on a disc surrounding the oral sucker, justifying its name *Echinostoma* which means "spiny mouth".
- Its eggs resemble those of *Fasciolopsis*. Mild infections are asymptomatic, but diarrhea and abdominal pain follow heavy infection.
- *E. ilocanum* is the species usually seen in human infections.

Gastrodiscoides Hominis

G. hominis is the only fluke inhabiting the **human large intestine (Fig. 17)**.

- It was discovered by Lewis and McConnell in 1876 in the cecum of an Indian patient.
- It is a common human parasite in **Assam**. Cases have also been reported from Bengal, Bihar and Odisha.
- It also occurs in Vietnam, Philippines and some parts of erstwhile Union of Soviet Socialist Republics (USSR).
- The adult worm is **pyriform**, with a conical anterior end and a discoidal posterior part. It is about 5–14 mm long and 4–6 mm broad.
- The eggs are operculated and measure 150 µm by 70 µm.




Fig. 17: Specimen showing *Gastrodiscoides hominis*

Definitive Host

Man, pigs and monkey. **Pigs** are the reservoir hosts.

First Intermediate Host

Snails.

Second Intermediate Host

Aquatic plants.

- The miracidia invade the tissues of the *intermediate molluscan host*.
- The cercariae encyst on water plants. Infected persons develop muroid diarrhea.
- Man and animals become infected by feeding upon vegetations harboring the metacercaria.

Drug of Choice

Praziquantel. Tetrachloroethylene is also useful in treatment.

■ LUNG FLUKES

Paragonimus westermani

Common Name

Oriental lung fluke.

History and Distribution

P. westermani was discovered in 1878 by Kerbert in the lungs of a Bengal tiger captured in India that died in the zoological gardens at Amsterdam.

- The parasite is endemic in the Far East—Japan, Korea, Taiwan, China and South East Asia—Sri Lanka and India.
- There are about 40 species of *Paragonimus* that infect mammals.
- In India, cases have been reported from Assam, Bengal, Tamil Nadu, Kerala, Manipur, Sikkim, Arunachal Pradesh and Nagaland.
- *P. westermani* is the most common species infecting human.
- **Endemic foci** of *P. westermani* and *P. heterotremus* are present in **Manipur**.
- It is an important human pathogen in Central and South America.

Morphology

Adult worm: The adult worm is **egg-shaped** about 10 mm long, 5 mm broad and 4 mm thick and reddish-brown in color (**Fig. 18**).

- The integument is covered with scale-like spines.

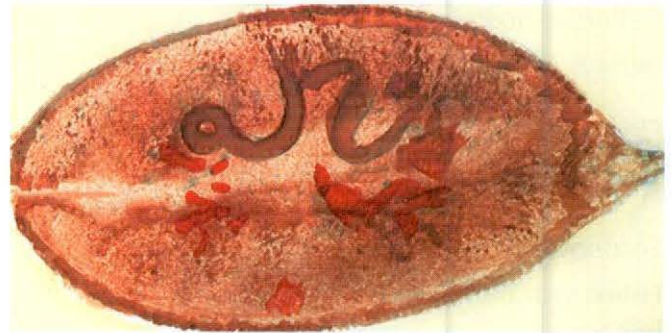

Fig. 18: *Paragonimus westermani* morphology

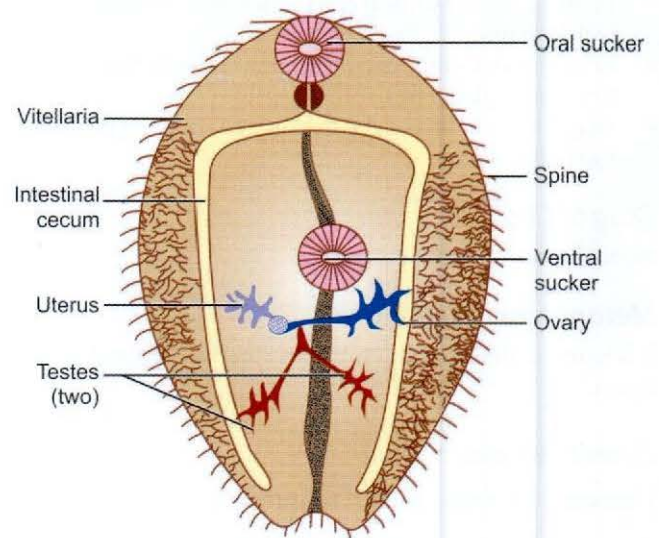


Fig. 19: *Paragonimus westermani*

- It has an oral sucker placed anteriorly and a ventral sucker located towards the middle of the body (**Fig. 19**).
- It has two unbranched intestinal caeca which end blindly in the caudal area.
- They have a lifespan of up to 20 years in humans.

Egg: The eggs are operculated, golden-brown in color and about 100 μm by 50 μm in size (**Fig. 20**).

- They are unembryonated when freshly laid.

Habitat

Adult worms live in the **lungs**, usually in pairs in cystic spaces that communicate with bronchi (**Table 4**).

Life Cycle

Definitive host: Man. Besides humans, other definitive hosts include cats, tigers, leopards, foxes, dogs, pigs, beavers, mongoose, and many other crab-eating mammals and domestic animals.

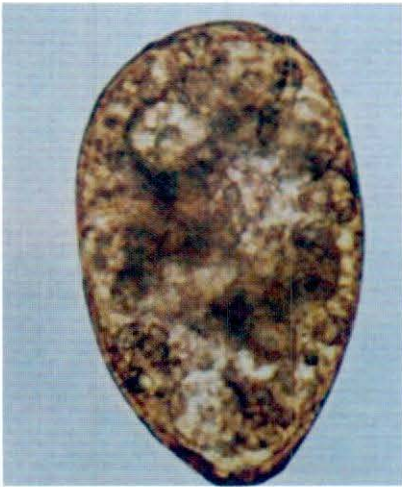

Fig. 20: Egg of *Paragonimus westermani*

Table 4: Helminths present in lung

Trematode	Cestode	Nematode
<i>Paragonimus westermani</i>	<i>Echinococcus granulosus</i>	<i>Capillaria aerophila</i>
	<i>Dirofilaria immitis</i>	

First intermediate host: Freshwater snail, belonging to the genera *Semisulcospira* and *Brotia*.

Second intermediate host: Freshwater crab or crayfish.

Infective form: Metacercariae encysted in **crab** or **crayfish**.

Mode of infection: Man acquires infection by eating undercooked crab or crayfish containing **metacercariae**.

- The adult worms live in the respiratory tract of the definitive host.
- Unembryonated eggs escape into the bronchi and are coughed up and voided in sputum or swallowed and passed in feces (Fig. 21).
- The eggs mature in about 2 weeks and hatch to release free-swimming miracidia.
- These infect the **first intermediate** molluscan host, snails belonging to the genera *Semisulcospira* and *Brotia*.
- Cercariae that are released from the snails after several weeks are microcercus, having a short stumpy tail.
- The cercariae that swim about in streams are drawn into the gill chambers of the **second intermediate crustacean host**, crabs or crayfish (Fig. 21).
- They encyst in the gills or muscles as *metacercariae*.
- Definitive hosts are infected when they eat such crabs or crayfish raw or inadequately cooked.
- The metacercariae excyst in the duodenum and the adolescaria penetrate the gut wall, reaching the abdominal cavity in a few hours.

- They then migrate up through the diaphragm into the pleural cavity and lungs finally reaching in the vicinity of the **bronchi**, where they develop into adult worms in 2-3 months (Fig. 21).
- The worm is hermaphroditic but usually it takes 2 for fertilization.
- Sometimes, the migrating larvae lose their way and reach ectopic sites such as the mesentery, groin and brain.

Pathogenicity and Clinical Features

Pulmonary features: In the lungs, the worms lie in cystic spaces surrounded by a fibrous capsule formed by the host tissues.

- The cysts, about a centimeter in diameter are usually in communication with a bronchus.
- Inflammatory reaction to the worms and their eggs lead to **peribronchial granulomatous** lesions, cystic dilatation of the bronchi, abscesses, pneumonitis and eosinophilia.
- Patients present with cough, chest pain and **hemoptysis**.
- The viscous sputum is speckled with the golden-brown eggs. Occasionally, the hemoptysis may be profuse.
- Chronic cases may resemble pulmonary tuberculosis.

Extrapulmonary features: The clinical features depend on the site of involvement.

- Extrapulmonary infections are more common in *P. mexicanus*, *P. heterotremus* and rare in *P. westermani*.
- **Abdominal paragonimiasis:** Occasionally the fluke migrates to liver and intestinal wall resulting in enlarge liver, abdominal tenderness and bloody diarrhea.
- **Cerebral paragonimiasis:** Encapsulated cyst of *Paragonimus* is found in brain and spinal cord.
- Symptoms include headache, fever, paralysis, visual disturbances and convulsions seizures.

Laboratory Diagnosis

Microscopy: Demonstration of the eggs in sputum or feces provides definitive evidence. Sputum examination should be repeated for 7 consecutive days.

Serology: Complement fixation test is positive only during and shortly after active infection, while the intradermal test remains positive for much longer periods.

- Parasite-specific immunoglobulin E (IgE) and antiparagonimus antibodies can be detected in serum.
- Indirect hemagglutination and ELISA tests are highly sensitive. They become negative within 3-4 months after successful treatment.
- Serology is of particular importance in egg-negative cases and in cerebral paragonimiasis.

Imaging: Chest X-ray reveals abnormal shadows (nodular, cystic, ring, infiltrative) in the middle and lower lung field.

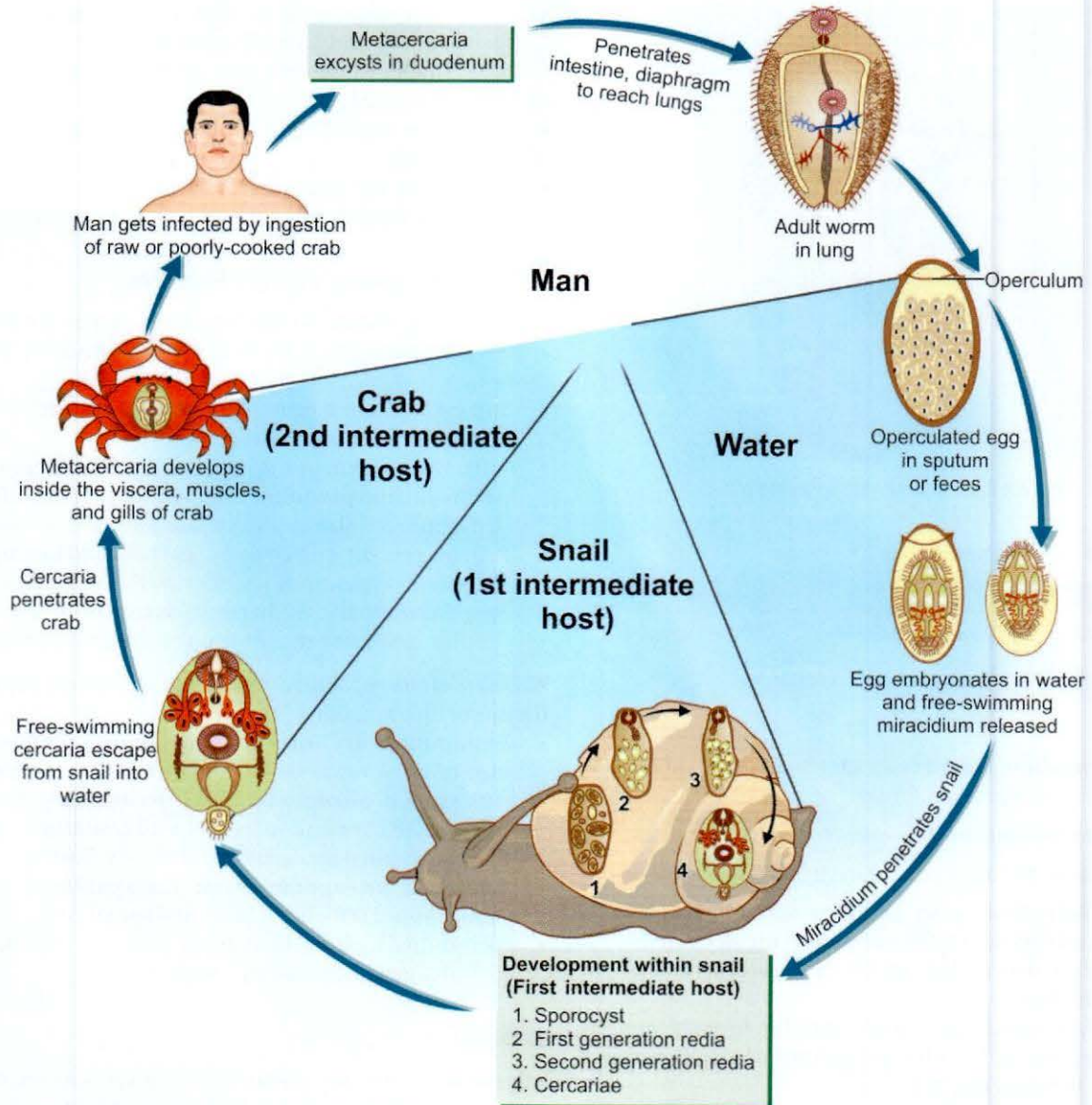


Fig. 21: Life cycle of *Paragonimus westermani*

- Computed tomography scan of chest also helps in diagnosis of pulmonary lesions and cerebral lesions. "Soap-bubble" like appearance may be seen in cerebral cysts.

Treatment

- Praziquantel (25 mg/kg TDS for 1-2 days) is the drug of choice.
- Bithionol and niclofolan are also effective in treatment.

Prophylaxis

- Adequate cooking of crabs and crayfish and washing the hands after preparing them for food.
- Treatment of infected persons.
- Disinfection of sputum and feces.
- Eradication of molluscan hosts.

KEY POINTS OF *PARAGONIMUS WESTERMANI*

- Adult worm is egg-shaped, reddish, brown and covered with scale-like spine.
- **Habitat:** Cystic spaces in the lung.
- Eggs are oval, operculated and golden brown.
- **Definitive hosts:** Man and domestic animals.
- **First intermediate host:** Snails of genera *Semisulcospira* (*Melania* species).
- **Second intermediate host:** Crab or crayfish.
- **Infective form:** Encysted metacercaria in crab or crayfish.
- **Clinical features:** Peribronchial granuloma and cystic dilation of bronchi. Dyspnea, hemoptysis, pneumonitis, bronchiectasis, abscess and pneumothorax. Extrapulmonary lesions in brain and intestine.
- **Diagnosis:** Ova in sputum, X-ray and CT scan of chest, CFT, IHA and ELISA.
- **Treatment:** Praziquantel is the drug of choice.
- **Prophylaxis:** Adequate cooking of crabs and crayfish, eradication of molluscan hosts and treatment of infected persons.

REVIEW QUESTIONS

1. Describe briefly:
 - a. General characters of trematodes
 - b. Classification of trematodes
 - c. General characters of schistosomes
2. Short notes on:
 - a. *Clonorchis sinensis*
 - b. *Fasciolopsis buski*
 - c. *Paragonimus*
 - d. *Opisthorchis species*
3. Describe morphology, life cycle and laboratory diagnosis of
 - a. *Fasciola hepatica*
 - b. *Schistosoma haematobium*
4. Differentiate between *Schistosoma haematobium*, *S. mansoni* and *S. japonicum*.

MULTIPLE CHOICE QUESTIONS

1. Which of the following flukes is carcinogenic
 - a. *Fasciola*
 - b. *Clonorchis*
 - c. *Paragonimus*
 - d. *Gastrodiscoides*

2. Organism causing biliary tract obstruction
 - a. *Ancylostoma duodenale*
 - b. *Clonorchis sinensis*
 - c. *Strongyloides stercoralis*
 - d. *Enterobius vermicularis*
3. All float in a saturated salt solution except
 - a. *Clonorchis sinensis*
 - b. Fertilized eggs of *Ascaris*
 - c. Larva of *Strongyloides*
 - d. *Trichuris trichiura*
4. Terminal spined eggs are seen in
 - a. *Schistosoma haematobium*
 - b. *Schistosoma mansoni*
 - c. *Schistosoma japonicum*
 - d. *Clonorchis sinensis*
5. Largest trematode infecting humans
 - a. *Fasciola hepatica*
 - b. *Fasciolopsis buski*
 - c. *Schistosoma haematobium*
 - d. *Paragonimus westermani*
6. The second intermediate host of *Fasciola hepatica* is
 - a. Snail
 - b. Fresh water fish
 - c. Crab
 - d. Aquatic plants
7. *Schistosoma japonicum* resides in
 - a. Superior mesenteric vein
 - b. Inferior mesenteric vein
 - c. Small intestine
 - d. Gallbladder
8. All of the following lead to bloody diarrhea except
 - a. *Schistosoma japonicum*
 - b. *Entamoeba histolytica*
 - c. *Schistosoma mansoni*
 - d. *Schistosoma haematobium*

Answer

- | | | | |
|------|------|------|------|
| 1. b | 2. b | 3. a | 4. a |
| 5. b | 6. d | 7. a | 8. d |

Nematodes: General Features

■ INTRODUCTION

Nematodes are said to be the most worm-like of all helminths. This is because they generally resemble the common earthworm in appearance, which is considered to be the prototype of “worms”. However, taxonomically earthworms are not nematodes as they are segmented worms of the Phylum *Annelida*.

- Nematodes are elongated, cylindrical, unsegmented worms with tapering ends. The name “nematode” means “thread-like”, from “nema” meaning “**thread**”.
- Unlike trematodes and cestodes, all of which are parasitic, most nematodes are **free-living** forms found in soil and water.
- Several species are parasites of plants and are of great economic importance. Many nematodes parasitize invertebrate and vertebrate animals.
- The largest number of helminthic parasites of humans belong to the class of nematodes. There are an estimated 500,000 species of nematodes.

■ GENERAL CHARACTERISTICS

They are **cylindrical**, or filariform in shape, bilaterally symmetrical with a secondary *triradial symmetry at the anterior end*.

- The adults vary greatly in size, from about a millimeter (*Strongyloides stercoralis*) to a meter (*Dracunculus medinensis*) in length. Male is generally smaller than female and its posterior end is curved or coiled ventrally.
- Their body is covered with a **tough outer cuticle**, which may be smooth, striated, bossed, or spiny. The *middle layer* is hypodermis and the *inner layer* is the somatic muscular layer. They move by *sinuous flexion* of the body.
- The body cavity is a **pseudocoel**, in which all the viscera are suspended.
- The digestive system is complete, consisting of an anteriorly placed mouth leading to the esophagus, which characteristically varies in shape and structure in different groups. The intestine is lined with a single layer of

Box 1: Types of female nematodes

- **Oviparous (laying eggs):**
 - Unsegmented eggs: *Ascaris*, *Trichuris*
 - Segmented eggs: *Ancylostoma*, *Necator*
 - Eggs containing larvae: *Enterobius*
- **Viviparous (producing larvae):** *Trichinella*, *Wuchereria*, *Brugia*, *Dracunculus*.
- **Ovoviviparous (laying eggs containing fully formed larvae, which hatch out immediately):** *Strongyloides*.

columnar cells and leads to the rectum, opening through the anus. In the male, the rectum and the ejaculatory duct open into the **cloaca**.

- Nematodes have simple excretory and nervous systems.
- The nematodes are **diecious**, i.e. the sexes are separate.
- The male reproductive system consists of a single delicate tubule differentiated into testis, vas deferens, seminal vesicle and ejaculatory duct, which opens into the cloaca. It also includes copulatory structures such as spicules or bursa or both.
- The female reproductive system consists of the ovary, oviduct, seminal receptacle, uterus and vagina.
- Female nematodes may produce eggs (**oviparous**) or larvae (**viviparous**). Some lay eggs containing larvae, which immediately hatch out (**ovoviviparous**) (**Box 1**).

■ LIFE CYCLE

The life cycle of nematodes consists typically of **four larval stages** and the **adult form**. The cuticle is shed while passing from one stage to the other.

- Man is the **optimum host** for all the nematodes. They pass their life cycle in one host, except the *superfamilies Filarioidea* and *Dracunculoidea*, where two hosts are required. **Insect vectors** and *Cyclops* constitute the second hosts in these superfamilies, respectively.
- Nematodes localize in the intestinal tract and their eggs pass out with the feces of the host. They undergo few developmental changes before they enter new host.

■ MODES OF INFECTION

- *By ingestion of:*
 - Eggs: *Ascaris*, *Enterobius*, *Trichuris*
 - Larvae within intermediate host: *Dracunculus*
 - Encysted larvae in muscle: *Trichinella*
- *By penetration of skin:* *Ancylostoma*, *Necator*, *Strongyloides*
- *By blood-sucking insects:* *Filariae*
- *By inhalation of dust containing eggs:* *Ascaris*, *Enterobius*.

■ CLASSIFICATION

Nematodes can be classified on the basis of the habitat of the adult worm (Table 1) and zoologically (Table 2).

Zoological Classification

- **Phylum:** Nematelminthes (Nematoda)
- **Class:** Nematoda which is divided into two subclasses based on the absence or presence of “phasmids”, which are caudal chemoreceptors. The two subclasses were earlier called *Aphasmidia* and *Phasmidia*, but now have been renamed as *Adenophorea* and *Secernentea*, respectively (Table 3).

Detailed zoological classification of nematodes is given in Table 2.

Table 1: Classification of nematodes on the basis of the habitat of adult worms

Intestinal human nematodes	Somatic human nematodes
Small intestine <ul style="list-style-type: none"> • <i>Ascaris lumbricoides</i> (common roundworm) • <i>Ancylostoma duodenale</i> (Old World hookworm) • <i>Necator americanus</i> (American or New World hookworm) • <i>Strongyloides stercoralis</i> • <i>Trichinella spiralis</i> • <i>Capillaria philippinensis</i> 	Lymphatics <ul style="list-style-type: none"> • <i>Wuchereria bancrofti</i> • <i>Brugia malayi</i> • <i>Brugia timori</i>
	Skin/subcutaneous tissue <ul style="list-style-type: none"> • <i>Loa loa</i> • <i>Onchocerca volvulus</i> • <i>Dracunculus medinensis</i> (guinea worm)
	Mysentery <ul style="list-style-type: none"> • <i>Mansonella ozzardi</i> • <i>Mansonella perstans</i>
Large intestine <ul style="list-style-type: none"> • <i>Trichuris trichiura</i> (whipworm) • <i>Enterobius vermicularis</i> (thread or pinworm) 	Conjunctiva <ul style="list-style-type: none"> • <i>Loa loa</i>

■ LARVA MIGRANS

The life cycles of most nematodes parasitizing humans include larval migration through various tissues and organs of the body. Sometimes the larvae appear to lose their way and wander around aimlessly. This condition is known as *larva migrans*.

- This is generally seen when human infection occurs with **nonhuman species** of nematodes. In such infections, the worm is unable to undergo normal development and complete its life cycle.
- Abnormal or arrested larval migration may also sometimes occur when human parasitic nematodes infect immune persons. The immunity is sufficient to prevent the normal progression of infection.
- Larva migrans can be classified into cutaneous or visceral types, depending on whether the larval migration takes place in the skin or in deeper tissues (Table 4).

Cutaneous Larva Migrans

This condition also known as **creeping eruption** (also called **ground itch**) is caused by nematode larvae that infect by skin penetration.

Etiology

The most common cause is *nonhuman* species of *hookworm* (*Ancylostoma braziliense* and *A. caninum*) (Table 5).

Pathogenesis

Parasite eggs are passed in the feces of infected animals into the soil, where the larvae hatch out.

- Infection with these hookworms of *dogs* and *cats* is acquired from soil contaminated with excreta of these animals.
- On coming in contact with human skin, the larvae penetrate the skin to cause infection.
- Between a few days and a few months after the initial infection, the larvae migrate beneath the skin.
- In normal animal host, the larvae are able to penetrate the deeper layers of the skin by reaching there via circulation.
- Once they enter intestine, they mature sexually and lay more eggs that are then excreted to repeat the cycle.
- However, in a human host, which is an accidental host for the parasite, the larvae are unable to penetrate the basement membrane to invade the dermis, so that the disease remains confined to the outer layers of the skin.

Clinical Features

- The larvae produce **itching papules**, which develop into **serpiginous tunnels** in the epidermis. With the

Table 2: Zoological classification of nematodes

Subclass	Order	Superfamily	Family	Genus	Species
Adenophorea/ Aphasmidia (no phasmids, no caudal papillae in male, eggs usually unsegmented with polar plugs or hatching in uterus)	Enoplida	Trichinelloidea (anterior part of body narrower than posterior)	Trichinellidae Trichuridae	• <i>Trichinella</i> • <i>Trichuris</i> • <i>Capillaria</i>	• <i>T. spiralis</i> • <i>T. trichiura</i> • <i>C. philippinensis</i> • <i>C. aerophila</i> • <i>C. hepatica</i>
Secernentea/ Phasmidia (phasmids present, numerous caudal papillae)	Rhabditida	Rhabditoidea (alternation of free-living and parasitic generations, parasitic females parthenogenetic)	Strongyloididae	Strongyloides	<i>S. stercoralis</i>
	Strongylida	• Ancylostomatoidea (prominent buccal capsule with teeth or cutting plates) • Metastrongyloidea (tissue parasites, inconspicuous buccal capsule, have intermediate hosts)	• Ancylostomatidae • Metastrongylidae	• <i>Ancylostoma</i> • <i>Necator</i> • <i>Angiostrongylus</i>	• <i>A. duodenale</i> • <i>N. americanus</i> • <i>A. cantonensis</i>
	Ascaridida	Ascaridoidea (large worms of gut lumen, mouth has three lips)	• Ascarididae • Anisakidae	• <i>Ascaris</i> • <i>Anisakis</i>	• <i>A. lumbricoides</i> • <i>A. simplex</i>
	Oxyurida	Oxyuroidea (male has no caudal bursa, short stout body, esophagus has prominent bulb, eggs planoconvex, embryonate in uterus)	Oxyuridae	<i>Enterobius</i>	<i>E. vermicularis</i>
	Spirurida	• Filarioidea (tissue parasites, viviparous, insect vector) • Dracunculoidea (very long female and small male, viviparous, larvae escape from ruptured uterus) • Gnathostomatoidea (spiny body with bulbous head)	• Onchocercidae • Dracunculidae • Gnathostomatidae	• <i>Wuchereria</i> • <i>Brugia</i> • <i>Dirofilaria</i> • <i>Loa</i> • <i>Mansonella</i> • <i>Onchocerca</i> • <i>Dracunculus</i> • <i>Gnathostoma</i>	• <i>W. bancrofti</i> • <i>B. malayi</i> • <i>D. conjunctivae</i> • <i>D. immitis</i> • <i>L. loa</i> • <i>M. perstans</i> • <i>M. ozzardi</i> • <i>M. streptocerca</i> • <i>O. volvulus</i> • <i>D. medinensis</i> • <i>G. spinigerum</i>

Table 3: Differences in subclass adenophorea and secernentea

	Adenophorea	Secernentea
Phasmid (sensory structure)	Absent	Present
Excretory system	Without lateral canals	With lateral canals
Caudal papillae	Absent or few	Numerous
Infective stage of larva	First larval stage	Third larval stage

movements of the larva in the skin, the lesion also shifts, hence the name “**creeping eruption**”. Scratching may lead to secondary bacterial infection.

- Transient *creeping eruptions* may be produced sometimes by the *human hookworm*, *Necator americanus*. *Gnathostomiasis* and *sparganosis* may produce larva

migrans, where the lesions are deeper, subcutaneous or in the muscles. **Loeffler's syndrome** may occur in one-fourth to one-half of the cases.

- A rapidly moving lesion is produced by *Strongyloides stercoralis* particularly in immune persons. This is known as **larva currens**.

Table 4: Animal nematodes infecting man

Visceral larva migrans	Cutaneous larva migrans
<ul style="list-style-type: none"> It is a syndrome caused by nematodes that are normally parasitic for nonhuman host species In human, these nematode larvae do not develop into adult worms, but, instead, migrate through host tissues and elicit eosinophilic inflammation 	<ul style="list-style-type: none"> It is a serpiginous skin eruption caused by burrowing larvae of animal hookworms (usually the cat and the cat hookworm) The larvae hatch from eggs passed in dog and cat feces and mature in the soil. Humans become infected after skin contact with contaminated soil. After larvae penetrate the skin, erythematous lesions form along the tortuous tracks of their migration. It is also known as creeping eruption
Common causes: <ul style="list-style-type: none"> <i>Toxocara canis</i> (dog roundworm)—most common <i>Toxocara cati</i> (cat roundworm) <i>Ascaris suum</i> (pig ascaris) <i>Angiostrongylus cantonensis</i> <i>Gnathostoma spinigerum</i> <i>Anisakis simplex</i> <i>Baylisascaris procyonis</i> 	Common causes: <ul style="list-style-type: none"> <i>Ancylostoma braziliense</i> (hookworm of wild and domestic dogs and cats) <i>Ancylostoma caninum</i> (dog hookworm found in Australia) <i>Uncinaria stenocephala</i> (dog hookworm found in Europe) <i>Bunostomum phlebotomum</i> (cattle hookworm)

Table 5: Etiological agents (cutaneous larva migrans)

Zoophilic nematode <ul style="list-style-type: none"> <i>Ancylostoma braziliense</i> <i>Ancylostoma caninum</i> <i>Gnathostoma spinigerum</i> <i>Dirofilaria</i> <i>Spirometra</i> <i>Uncinaria stenocephala</i> <i>Bunostomum phlebotomum</i> 	Human nematode <ul style="list-style-type: none"> <i>Strongyloides stercoralis</i> <i>Necator americanus</i> <i>Loa loa</i>
	Human trematode <ul style="list-style-type: none"> Ectopic infection with <i>Fasciola</i> and <i>Paragonimus</i>
	Nonhelmenthic agents <ul style="list-style-type: none"> Flies of genus <i>Hypoderma</i> and <i>Gastrophilus</i>

- Creeping myiasis** is caused by flies of the genus *Hypoderma* and *Eastrophilus*.
- Ectopic infections** with *Fasciola* and *Paragonimus* may produce creeping lesions on abdominal wall.

Diagnosis

Eosinophilia is rare and occurs only when Loeffler's syndrome develop.

- Serological tests are not developed.
- On biopsy, larvae are rarely found in the skin lesion.
- Diagnosis is based mainly on clinical features.

Treatment

Thiabendazole is useful in treatment. When the lesions are few, freezing the advancing part of the eruption with ethyl chloride is effective.

Table 6: Etiological agents (visceral larva migrans)

Zoophilic nematode <ul style="list-style-type: none"> <i>Toxocara canis</i> <i>Toxocara cati</i> <i>Angiostrongylus cantonensis</i> <i>Brugia patei</i> <i>Angiostrongylus costaricensis</i> <i>Anisakis</i> <i>Gnathostoma spinigerum</i> 	Nonhuman nematode <ul style="list-style-type: none"> <i>Filaria spp.</i> <i>Dirofilaria immitis</i> <i>Brugia pahangi</i>
	Human nematode <ul style="list-style-type: none"> <i>Ascaris lumbricoides</i> <i>Strongyloides stercoralis</i>

Visceral Larva Migrans

This condition is caused by the migration of larvae of **nonhuman species** of nematodes that infect by the oral route.

Etiology

The most common cause is the **dog ascarid**, *Toxocara canis* and less often the cat ascarid, *T. cati*. Visceral larva migrans may also be caused by *Anisakis*, which are large ascarid parasites of marine animals and also by *Gnathostoma spinigerum*, *Angiostrongylus cantonensis*. **Human nematodes** like *A. lumbricoides* and *S. stercoralis* may produce visceral larva migrans, when they get lost in **ectopic sites** (Table 6).

Pathogenesis

When the infective eggs present in the soil contaminated by dog and cat feces are ingested, the larvae hatch in the small intestine, penetrate the gut wall, and migrate to the liver.

- They may remain there or migrate to other organs such as lungs, brain, or eyes.
- In humans they do not develop into adults, but induce **granulomatous** lesions, which cause local damage.

Table 7: Difference between cutaneous and visceral larva migrans

	<i>Cutaneous larva migrans</i>	<i>Visceral larva migrans</i>
Tissue involved	Skin	Various organs of body like liver, lungs and eyes
Infecting organism	Mostly by nonhuman nematodes	Mainly by dog and cat (<i>Toxocara</i> spp.)
Portal of entry	Penetration of skin	Ingestion of infected eggs
Eosinophilia	Mild	Persistent high
Serodiagnosis	Not developed	Well developed
Treatment	Thiabendazole	Diethylcarbamazine and prednisolone

Clinical Features

Clinical manifestations depend on the sites affected and the degree and duration of infection.

- As *children* are more likely to swallow dirt, this condition is much more frequent in them.
- Fever, hepatomegaly, pneumonitis, hyperglobulinemia and pica are the common findings.
- Patients may develop neurological disturbances (**neural larva migrans**) and endophthalmitis (*ophthalmic larva migrans*).
- Marked leukocytosis occurs with persistently high eosinophilia.

Diagnosis

Serological tests, such as passive hemagglutination, bentonite flocculation, microprecipitation, and more specifically, enzyme-linked immunosorbent assay (ELISA) have been developed for the diagnosis of toxocariasis (visceral larva migrans).

Treatment

Diethylcarbamazine (**DEC**), 100 mg TDS for 3 weeks in an adult, kills the larva and arrest the disease. Thiabendazole may be useful in treatment. Prednisolone should be administered concurrently either topically or systemically.

Prophylaxis

Deworming of household pets helps in prevention by limiting the contamination of soil.

Differences between cutaneous and visceral larva migrans are given in **Table 7**.

KEY POINTS OF CUTANEOUS AND VISCERAL LARVA MIGRANS

- Sometimes larvae lose their way and wander around aimlessly in human body, this condition is known as larva migrans (cutaneous or visceral).
- Mainly caused by nonhuman species of nematodes (zoophilic helminths), but occasionally by nonhelminthic agents like mite and larvae of fly (myiasis).
- Man acquires the infection as an accidental host.
- Abnormal migrations also occur sometimes in human nematodes.
- The helminths are unable to complete their development and life cycle in man and are arrested at some level in skin or other organs like lung, liver, etc.
- **Pathogenesis:** Due to mechanical damage and host's inflammatory response against parasitic antigen.
- **Clinical manifestations:** Depend on route of entrance, sites affected, and degree and duration of infection.
- **Diagnosis:** Based mainly on clinical features, skin biopsy and serology.
- **Treatment:** Symptomatic and specific therapy with antihelminthics.

REVIEW QUESTIONS

1. Describe briefly:
 - a. General characters of Phylum Nematoda
 - b. Systematic classification of nematodes
2. Short notes on:
 - a. Classification of nematodes based on habitat
 - b. Cutaneous larva migrans
 - c. Visceral larva migrans
 - d. Viviparous nematodes
 - e. Larva currens
3. Differentiate between class Adenophorea and Secernentea.
4. Enumerate the etiological agents of cutaneous and visceral larva migrans.

MULTIPLE CHOICE QUESTIONS

1. All of the following nematodes are oviparous except

- a. *Ascaris*
- b. *Ancylostoma*
- c. *Trichinella*
- d. *Enterobius*

2. Nematoda residing in large intestine

- a. *Necator*
- b. *Trichinella*
- c. *Strongyloides*
- d. *Trichuris*

3. All of the following are somatic nematodes except

- a. *Loa loa*
- b. *Capillaria philippinensis*
- c. *Onchocerca volvulus*
- d. *Brugia malayi*

4. Most common cause of visceral larva migrans

- a. *Ancylostoma braziliensis*
- b. *Anisakis simplex*
- c. *Strongyloides stercoralis*
- d. *Toxocara canis*

5. Cutaneous larva migrans is due to

- a. *Ancylostoma braziliensis*
- b. *Wuchereria bancrofti*
- c. *Brugia malayi*
- d. *Dracunculus medinensis*

6. A teenager who plays with dogs developed skin rash, eosinophilia, and an enlarged liver and spleen for 1 year. The most likely cause of this infection is

- a. Trichinosis
- b. Schistosomiasis
- c. Toxoplasmosis
- d. Visceral larva migrans

Answer

1. c 2. d 3. b 4. d 5. a 6. d

Trichinella Spiralis

■ INTRODUCTION

- *Trichinella spiralis*, tissue nematode, is the causative agent of *trichinosis*.
- The name *Trichinella* is derived from the minute size of the adult (Greek *trichos*—hair, *ella* suffix for diminutive, *spiralis* refers to the **spirally coiled** appearance of larvae in muscles).

■ COMMON NAME

Trichina worm.

■ HISTORY AND DISTRIBUTION

- It was first observed in 1821 in the muscles of a patient at autopsy by **James Paget**, who was then a first year medical student at St Bartholomew's Hospital, London.
- **Owen**, in 1835, described the encysted larval form in muscles and named it *Trichinella spiralis*.
- **Virchow** discovered its life cycle in 1859.
- The major source of human infection was shown to be the **consumption of inadequately cooked pork**.
- Trichinosis is recognized as an important public health problem in Europe and America, but is much less common in the tropics and oriental countries.
- Human trichinosis had not been recorded in India till 1996, when the first case was reported from Punjab.

■ HABITAT

Adult worms live deeply buried in the *mucosa of small intestine (duodenum or jejunum)* of pig, bear, rat, or man. The encysted larvae are present in the **striated muscles** of these hosts. There are no free-living stages.

■ MORPHOLOGY

Adult Worm

The adult *T. spiralis*, a small white worm just visible to the naked eye, is one of the **smallest nematodes** infecting humans.

- The **male** measures about 1.5 mm by 0.04 mm and the **female** about 3 mm by 0.06 mm (twice the length of male).
- The **anterior half** of the body is *thin and pointed*, well-adapted for *burrowing* into the mucosal epithelium (**Fig. 1**).
- The **posterior end** of the male has a pair of pear-shaped *clasping papillae* (termed as **claspers**), one on each side of the *cloacal orifice* that it uses to hold the female worm during mating (**Fig. 1**).

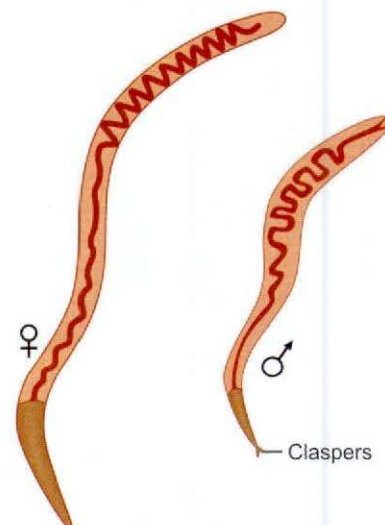


Fig. 1: Adult worms of *Trichinella spiralis* (male and female)

- The female worm is **viviparous** and discharges larva instead of eggs.
- The lifespan of the adult worm is very short. The male worm dies soon after fertilizing the female and the female dies after 4 weeks to 4 months (16 weeks), the time required for discharging the larvae.

Larvae

The larva becomes encysted in the striated muscle fiber (Fig. 2) and at the time of encystment measures 1 mm in length by 36 μm in diameter.

The larva in the cyst is *coiled* and hence, the name *spiralis*.

Trichinella Cyst

- Cysts are ovoid 400 μm by 250 μm in size.
- The cyst is formed by the tissue reaction around the encapsulated larvae.
- Cysts develop preferentially in muscles relatively poor in glycogen and in hypoxic environment. Therefore, the diaphragm, biceps, muscles of jaw, extraocular muscles, neck, and lower back, which are constantly active, are the ones mostly affected.
- Cysts are more abundant near the sites of attachment of muscles to tendons and bones than in other parts. They lie longitudinally along the muscle fibers.
- The deltoid being easily accessible, is chosen for taking diagnostic muscle biopsies.
- The larva remains infective inside the cyst for years and eventually, most become calcified and die.

■ LIFE CYCLE

Trichinella is a parasite that has a direct life cycle, which means it completes all stages of development in one host.

But only a *single cycle* occurs in one host and for continuation of the cycle and maintenance of the species, it is necessary for the infection to be transmitted to another host of the same species or of different species (Fig. 3).

- **Optimum host:** Pig.
- **Alternate host:** Man.
- Infection can pass from—pig-to-pig (facilitated by the custom of feeding pigs with untreated household garbage, which may contain bits of pork with infective cysts), rat-to-rat and pig-to-rat (Table 1).
- Man is the *dead-end* of the parasite, as the cysts in human muscles are unlikely to be eaten by another host.
- **Infective form:** Encysted larva found in the muscles of pigs and other animals (Fig. 2).
- **Mode of infection:** Man acquires infection mainly by eating raw or undercooked pork or inadequately

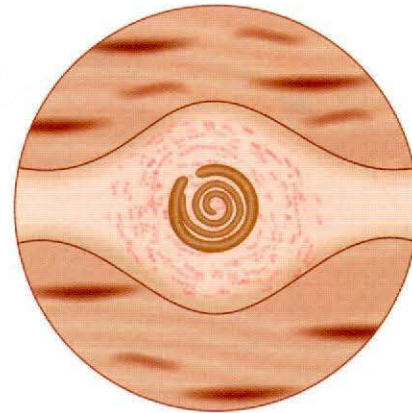


Fig. 2: Encysted larva in muscles; infective stage

processed sausages or other meat products containing the viable larvae.

- When such meat is eaten without adequate cooking, the cysts are digested by the gastric juice and viable larvae are released (excystation) in the stomach, duodenum and jejunum.
- The larvae immediately penetrate the mucosal epithelium.
- They moult **four times** and rapidly develop into adults, either male or female, by the 2nd day of infection. Within 5 days, they become sexually mature.
- The male dies after fertilizing the female. The fertilized females start *releasing motile larvae* by the 6th day of infection.
- Larvae continue to be discharged during the remaining part of the lifespan of the female worm, which ranges from 4 weeks to 4 months.
- Each female gives birth to approximately 1,000 larvae.
- These larvae *enter the intestinal lymphatics or mesenteric venules* and are transported in circulation to different parts of the body.
- They get *deposited in the muscles, central nervous system and other sites*. The larva dies in most other situations, except the *skeletal muscles*, where it grows.
- *Deposition in the muscles* occurs mostly during the 2nd week of infection. Larval development in muscles takes place during the next 3 or 4 weeks.
- Within 20 days after entering the muscle cells, the larvae become encysted. A muscle cell carrying larva of *T. spiralis* is called as a **nurse cell**.
- Encysted larvae lie parallel to the muscles of host.
- Encysted larva can survive for months to years. In man, the life cycle ends here (Fig. 3).
- Smoking, salting or drying the meat does not destroy the infective larvae. Prolonged freezing (20 days in a normal freezer or at -20°C for 3 days) decontaminates the meat.

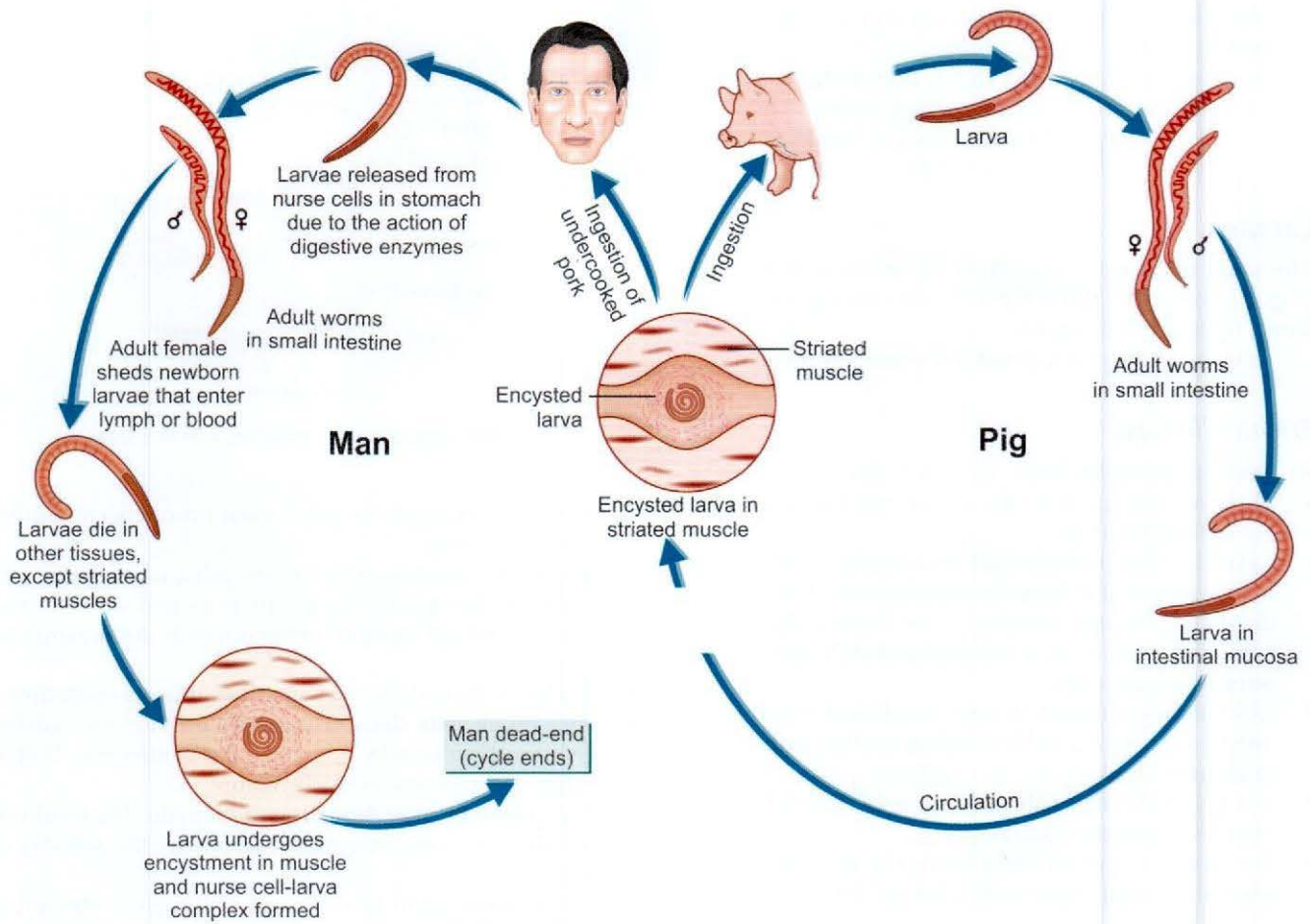


Fig. 3: Life cycle of *Trichinella spiralis*

Table 1: Parasites with source of infection

Pork	Fish
• <i>Taenia solium</i>	• <i>Diphyllobothrium latum</i>
• <i>Trichinella spiralis</i>	• <i>Clonorchis sinensis</i>
• <i>Sarcocystis suihominis</i>	• <i>Metagonimus yokogawai</i>
	• <i>Heterophyes</i> spp.
	• <i>Gnathostoma</i> spp.
Beef	
• <i>Taenia saginata</i>	
• <i>Sarcocystis hominis</i>	
• <i>Toxoplasma gondii</i>	

■ PATHOGENICITY AND CLINICAL FEATURES

The disease caused by *T. spiralis* is called *trichinosis*.

- The manifestations vary from asymptomatic infection, which is very common, to an acute fatal illness, which is extremely rare.

- The pathology and clinical features vary according to the stage in the life cycle of the worm (Table 2).

■ DIAGNOSIS

Diagnosis of trichinosis can be made by direct and indirect methods.

Direct Methods

- Detection of spiral larvae in muscle tissue by performing **muscle biopsy**. Deltoid, biceps, gastrocnemius, or pectoralis muscles are usually selected for biopsy (Box 1).
- Detection of adult worms and larvae in the stool during the diarrheic stage.
- **Xenodiagnosis:** For xenodiagnosis, biopsy bits are fed to laboratory rats, which are killed in a month or so, later. The larvae can be demonstrated more easily in the muscles of such infected rats (Flow chart 1).

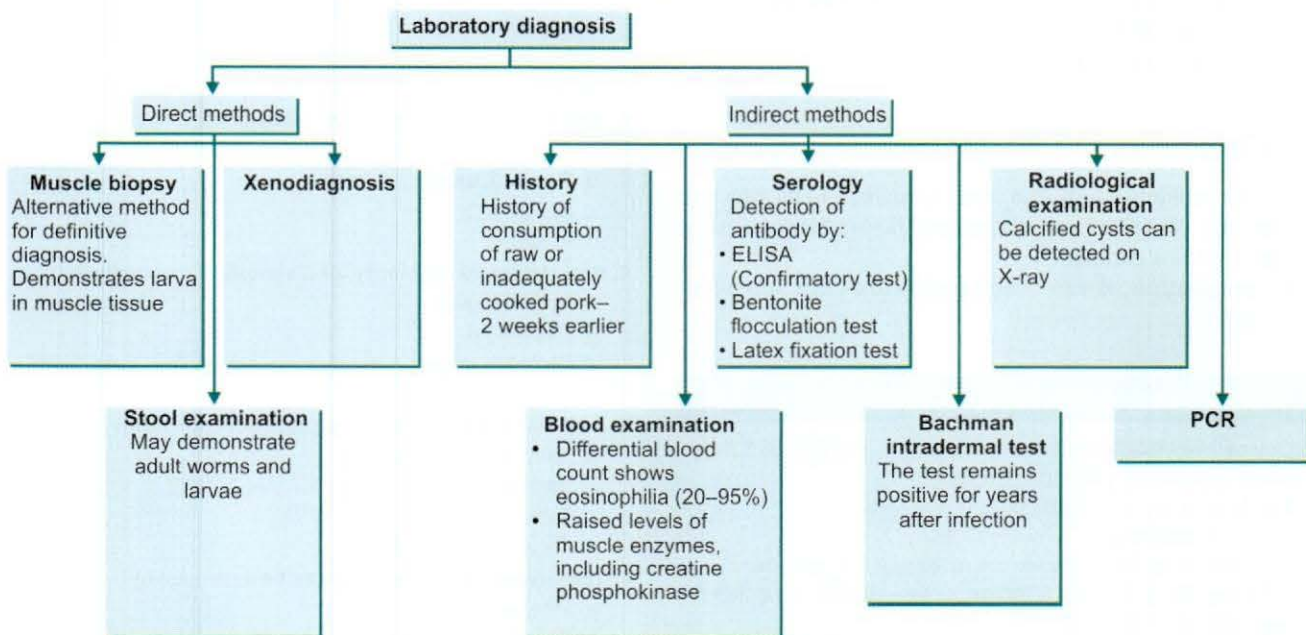
Table 2: Stages in the life cycle of *Trichinella spiralis* (in man)

	Stage of intestinal invasion: First stage	Stage of muscle invasion: Second stage	Stage of encystation: Final stage
Pathology	The stage begins with the ingestion of raw pork containing infective larvae and ends with the larvae invading the intestinal epithelium and developing into adult	The stage begins when new infective larvae are released from the adult female and ends with the deposition of the larvae in the muscles. Myositis and basophilic granular degeneration of muscles occurs in this stage	This stage occurs only in striated muscle. The infective larvae become encysted in this stage
Clinical features	Malaise, nausea, vomiting, diarrhea, abdominal cramps. Onset within 2–30 hours of ingestion of infective food	Fever, myalgia, periorbital edema, weakness of affected muscle, hemorrhage in subconjunctiva and new beds (splinter hemorrhages), myocarditis (if heart muscles are involved) and encephalitis (if central nervous tissue is involved). Eosinophilia is a constant feature of this stage. The stage is seen 1–4 weeks after infection	All symptoms subside

Box 1: Muscle biopsy

- Muscle biopsy specimen is collected for demonstration of spiral larvae.
- *Specimen:* Deltoid, biceps, gastrocnemius, or pectoralis.
- At least 1 gram of muscle should be taken for biopsy, preferably near tendon insertion.
- *Examination technique:* Muscle fibers are digested with trypsin and mounted on a glass slide and examined under microscope. Young larvae may be digested and missed during such examination.
 - A teased preparation of muscle tissue is prepared in a drop of saline solution and it is squeezed between two glass slides.
 - Muscle tissue is stained with safranin.

Flow chart 1: Laboratory diagnosis of *Trichinella spiralis*



Indirect Methods

- History of consumption of raw or inadequately cooked or processed pork, about 2 weeks earlier along with a recent episode of *gastroenteritis*.
- **Blood examination:** It shows eosinophilia (20–95%).

• **Serology:**

- There is massive hypergammaglobulinemia with elevated serum immunoglobulin E (IgE).
- *T. spiralis* antibody can be detected by enzyme-linked immunosorbent assay (ELISA) test using TSL-1 secreting antigens obtained from the infective

stage larvae. Bentonite flocculation test and latex fixation test for demonstration of antibodies have also been widely used. A positive test indicates recent infection.

- **Bachman intradermal test:** It uses a 1:5,000 or 1:10,000 dilution of the larval antigen. An erythematous wheal appears in positive cases within 15–20 minutes. The test remains positive for years after infection.
- **Radiological examination:** Calcified cysts may be demonstrated on X-ray examination.
- **Molecular methods** like multiplex polymerase chain reaction (PCR) are now being used for species identification of *Trichinella* (Flow chart 1).

TREATMENT

- **Mild cases:** Supportive treatment consisting of bedrest, analgesics and antipyretics.
- **Moderate cases:** Albendazole 400 mg BID for 8 days or mebendazole 200–400 mg TID for 3 days, then 400 mg TID for 8 days.
- **Severe cases:** Add glucocorticoids like prednisolone to albendazole or mebendazole.

Note: Mebendazole and albendazole are active against enteric stage of the parasite, but their efficacy against encysted larva has not yet been completely demonstrated.

PROPHYLAXIS

- Proper cooking of pork and other meat likely to be infected.
- The most effective method is to stop the practice of feeding pigs with raw garbage.
- Extermination of rats from pig farms—the spread of infection.

KEY POINTS OF TRICHINELLA SPIRALIS

- One of the smallest nematodes infecting humans (1.5–3 mm).
- Entire life cycle is passed in one host.
- The female worm is viviparous.
- **Optimum host:** Pig.
- **Alternate host:** Man. Man is the dead-end for parasite.
- **Infective form:** Encysted larvae in the striated muscles of pigs and other animals.
- Larvae remain encysted tightly coiled in striated muscles in human body.
- **Muscles commonly involved:** Diaphragm, pectoralis, deltoid, biceps and gastrocnemius.
- **Pathogenesis:** Myositis and basophilic degeneration of the muscles.

- **Clinical features:** Malaise, diarrhea, periorbital edema, muscle weakness, myocarditis, encephalitis.
- **Diagnosis:** Muscle biopsy for larvae, stool examination for adult worm or larvae, xenodiagnosis, Bachman intradermal test, ELISA, X-ray for calcified cyst, PCR.
- **Treatment:** Albendazole and mebendazole along with corticosteroids (in case of severe infection).

REVIEW QUESTIONS

1. Name the various intestinal nematodes and describe briefly the life cycle of *Trichinella*.
2. Write short notes on:
 - a. *Trichinella* cysts
 - b. Laboratory diagnosis of *Trichinella spiralis*

MULTIPLE CHOICE QUESTIONS

1. Larva found in muscle is
 - a. *Trichinella spiralis*
 - b. *Ancylostoma duodenale*
 - c. *Trichuris trichiura*
 - d. *Enterobius vermicularis*
2. Which of the following is not a neuroparasite
 - a. *Taenia solium*
 - b. *Acanthamoeba*
 - c. *Naegleria*
 - d. *Trichinella spiralis*
3. Which of the following is viviparous
 - a. *Strongyloides stercoralis*
 - b. *Trichinella spiralis*
 - c. *Enterobius*
 - d. *Ascaris*
4. Best site for taking biopsy for diagnosis of trichinellosis is
 - a. Deltoid muscle
 - b. Diaphragm
 - c. Pectoralis major
 - d. Liver
5. Bachman's test is done to diagnose infections with
 - a. *Schistosoma japonicum*
 - b. *Trichinella spiralis*
 - c. *Trichuris trichiura*
 - d. *Ancylostoma duodenale*
6. The larval form of *Trichinella* can be destroyed by
 - a. Smoking of meat
 - b. Deep freezing of meat
 - c. Drying of meat
 - d. Salting of meat

Answer

1. a 2. d 3. b 4. a 5. b 6. b

Trichuris Trichiura

■ INTRODUCTION

- The name *Trichuris* means a “hair-like tail” (*Greek trichos—hair, oura—tail*). This name is not quite correct because it is the anterior end of the worm that is hair-like and not the tail. The name **whipworm** is more apt as the thick posterior part resembles the stock and thin anterior end resembles the lash of a whip.
- The helminth causes trichiuriasis in humans, an intestinal infection caused by invasion of colonic mucosa.

■ COMMON NAME

Whipworm.

■ HISTORY AND DISTRIBUTION

- *Trichuris trichiura*, the human whipworm, was first described by **Linnaeus** in 1771.
- The antiquity of the whipworm as a human parasite is indicated by the demonstration of its eggs in colonic contents of a young man, who died on the Alps some 5,300 years ago and whose well-preserved body was discovered in 1990.
- It is worldwide in distribution, but is much more common in the tropics. The infection is widespread in tropical Africa, South America and South-east Asia. *Trichuris* infection is found throughout India.
- Some 800 million people are estimated to be infected with this worm.
- While whipworm infection is extremely frequent, whipworm disease is relatively rare.

■ HABITAT

T. trichiura lives in the **large intestine (Box 1)**. The adult worms are found attached to the wall of the *cecum* and less commonly to the vermiform appendix, colon and anal canal.

■ MORPHOLOGY

Adult Worm

The male worm is 30–45 mm long, while the female is slightly larger, about 40–50 mm.

- The worm is flesh-colored. In shape, it resembles a whip, with the *anterior three-fifth (3/5)* thin and thread-like and the *posterior two-fifth (2/5)* thick and fleshy, appearing like the handle of a **whip (Figs 1A and B)**.
- The attenuated anterior portion, which contains the capillary esophagus, is embedded in the mucosa. The posterior part contains the intestines and reproductive organs.
- The posterior end of the male is coiled ventrally, while the hind end of the female is straight, blunt and rounded (**Figs 1A and B**).
- The worm has a lifespan of 5–10 years.

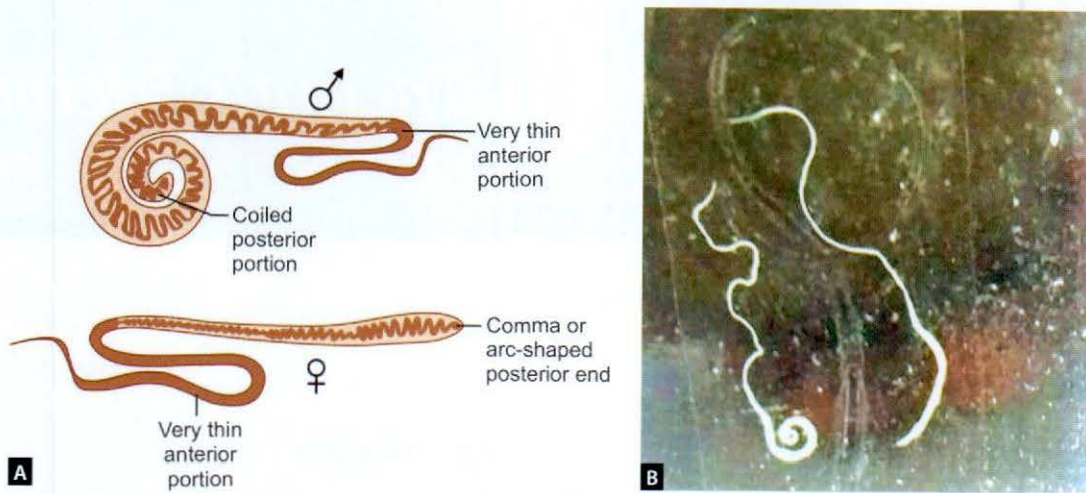
Egg

The egg has a characteristic appearance.

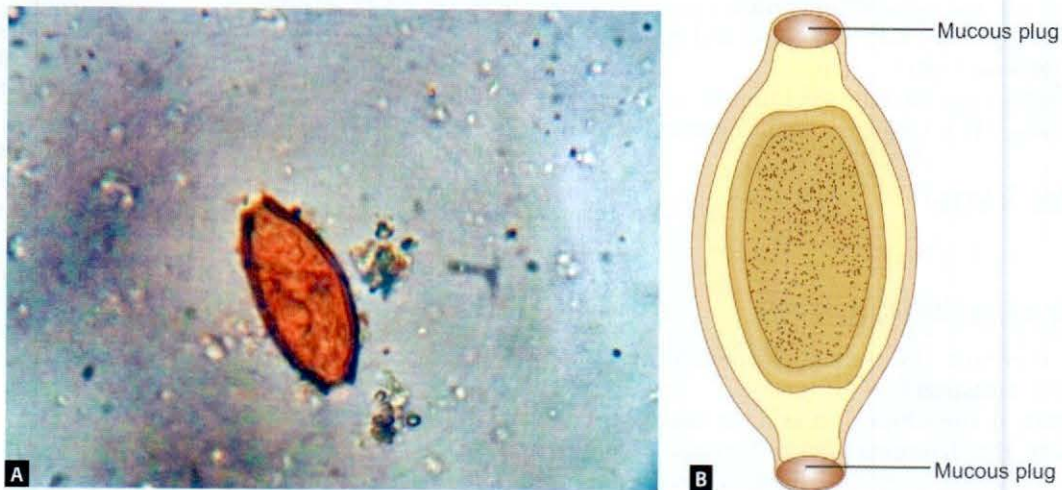
- It is brown in color being **bile-stained**.
- It has a **triple shell**, the outermost layer of which is stained brown.
- It is **barrel-shaped** and about 50 µm long and 25 µm wide in the middle, with a projecting **mucus plug** at each pole containing an unsegmented ovum (**Figs 2A and B**). The plugs are colorless.
- The egg floats in saturated salt solution (**Boxes 2 and 3**).

Box 1: Nematodes present in large intestine

- *Enterobius vermicularis*
- *Trichuris trichiura*
- *Oesophagostomum* spp.



Figs 1A and B: (A) Adult *Trichuris trichiura* worms (male and female); and (B) Specimens of male and female whipworm



Figs 2A and B: Egg of *Trichuris trichiura*. (A) As seen under microscope; and (B) Schematic diagram

Box 2: Helminths whose eggs float in saturated salt solution

- *Enterobius vermicularis*
- *Ancylostoma duodenale*
- *Necator americanus*
- *Ascaris lumbricoides*
- *Trichuris trichiura*

- When freshly passed, the egg contains an unsegmented ovum. At this stage, it is not infective for humans.
- The fertilized female lays about 5,000 eggs per day.

■ **LIFE CYCLE**

Natural host: Man. No intermediate host is required.

Box 3: Helminths whose eggs do not float in the saturated solution

- Eggs of *Taenia solium* and *Taenia saginata*
- Eggs of all intestinal flukes
- Unfertilized eggs of *Ascaris lumbricoides*

Infective form: Embryonated eggs containing rhabditiform larva.

- Adult female worm lives in large intestine, worm lays eggs which are discharged in feces.
- The egg undergoes development in soil, optimally under warm, moist, shady conditions, when the *infective rhabditiform larva* develops within the egg in 3–4 weeks. At lower temperatures, this may be delayed for 3 months

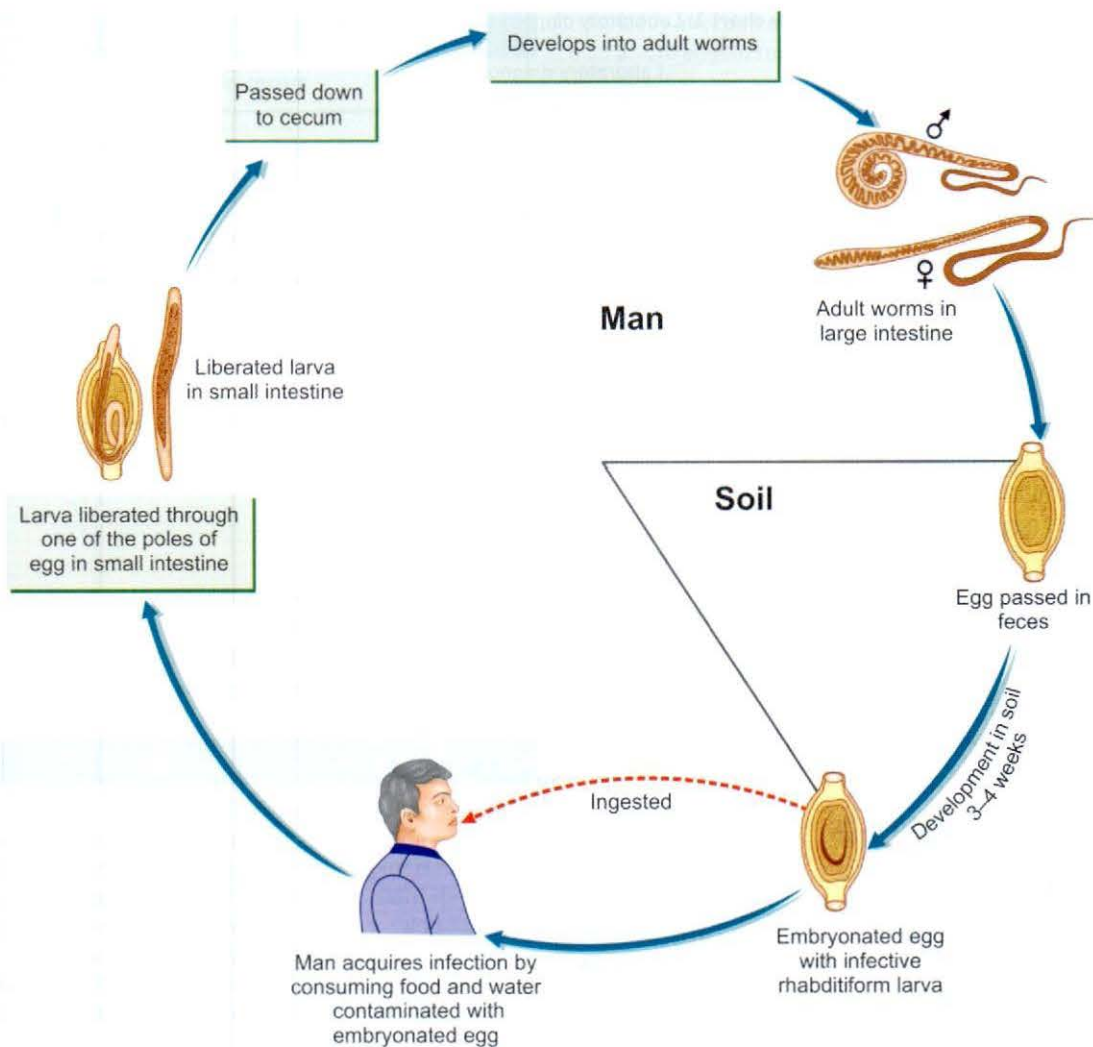


Fig. 3: Life cycle of *Trichuris trichiura*

or more (Fig. 3). These embryonated eggs are infective to man.

- **Mode of transmission:** Infection occurs in humans when the mature **embryonated eggs** containing the infective larvae are swallowed in *contaminated food or water*.
- The eggs hatch in the *small intestine* and the larva, which emerges through the pole of the egg, passes down into the cecum.
- In about 2–3 months, they become mature adults and lie embedded in the cecal wall, with the thread-like anterior portion piercing the mucosa and the thick posterior end projecting out.
- The gravid adult female lays eggs, which are discharged in feces and the cycle is repeated (Fig. 3).
- The entire life cycle can be passed in **one host**, from the ingested infective egg to the development of the adults

and the release of their eggs in feces. But for transmission of infection to other hosts and perpetuation of the species, the egg has to undergo development in the soil and then infect another person.

- Humans are the *only natural host* for *T. trichiura*, but morphologically similar worms are found to infect pigs and some monkeys.
- Eggs start appearing in feces usually about 3 months after infection.

■ PATHOGENICITY AND CLINICAL FEATURES

Infection with *T. trichiura* (*trichuriasis*, *whipworm infection*, or *trichocephaliasis*) is **asymptomatic**, except when the worm load is heavy. Disease may result either due to mechanical effects or allergic reaction.

Strongyloides Stercoralis

INTRODUCTION

Normand (1876) observed minute cylindrical worms in the diarrheic feces and intestinal walls of some French soldiers in Cochinchina. These were named *Strongyloides stercoralis* (strongylus—round, eidos—resembling, stercoralis—fecal).

HISTORY AND DISTRIBUTION

- It is found mainly in the warm moist tropics, but may also occur in the temperate regions. It is common in Brazil, Columbia, and in the Far East—Myanmar, Thailand, Vietnam, Malaysia and Philippines.
- Another species *S. fullerborni* is widely prevalent in African monkeys. It infects pygmies in the forests of Zaire and Zambia. It also causes human infection in Papua New Guinea. *Trichostrongylus*, a parasite of sheep and goats, seen in Africa and Asia (including India), may cause human infection, which is usually asymptomatic (**Table 1**).

HABITAT

The adult worm is found in the **small intestine** (duodenum and jejunum) of man (**Box 1**).

- **Largest nematode** known to cause human infection: *Ascaris lumbricoides*.
- **Smallest nematode** known to cause human infection: *Strongyloides stercoralis*.

MORPHOLOGY

Adult Worms

Female Worm

The female worm is thin, transparent, about 2.5 mm long and 0.05 mm wide (**Fig. 1**).

- It has a cylindrical esophagus occupying the anterior one-third of the body and the intestines in the posterior

Table 1: Difference between filariform larva of hookworm and *Strongyloides*

Hookworm	<i>Strongyloides</i>
• Esophagus extended up to 25% of the total body length	• Esophagus extended up to 40% of the total body
• Sheathed	• Nonsheathed
• Tail: Pointed	• Tail: Forked

Box 1: Nematodes present in small intestine

- *Strongyloides stercoralis*
- *Ascaris lumbricoides*
- *Ancylostoma duodenale*
- *Necator americanus*
- *Trichinella spiralis*
- *Trichostrongylus* spp.
- *Capillaria philippinensis*.

two-thirds, opening through the anus situated ventrally, a little in front of the pointed tail tip.

- The **reproductive system** contains paired uteri, vagina and vulva. The paired uteri lead to the vulva situated at the junction of the middle and posterior thirds of the body. In the gravid female, the uteri contain thin-walled transparent ovoid eggs, 50 µm by 30 µm in size.
- The worm is **ovoviviparous.**
- The individual worm has a **lifespan of 3 or 4 months**, but because it can cause **autoinfection**, the infection may persist for years.

Male Worm

The male worm is shorter and broader than female measuring 0.6–1 mm in length and 40–50 µm in width.

- The **copulatory spicules**, which penetrate the female during copulation, are located on each side of the gubernaculum (**Fig. 1**).

- They are **not seen in human infection** because they do not have **penetrating power**, therefore do not **invade** the intestinal wall.

Eggs

Eggs are **conspicuous within the uterus** of gravid female.

- Each uterus contains **8–10 eggs arranged anteroposteriorly** in a single row (**Fig. 1**).
- They are **oval** and measure **50–60 μm in length** and **30–35 μm in breadth** (**Fig. 2**).
- As soon as the eggs are laid, they hatch out to rhabditiform larva** (first stage larva). Thus, **it is the larva and not the egg, which is excreted in feces** and detected on stool examination and not egg.

Larva

Rhabditiform Larva (L1 Stage) (Fig. 3A)

This is the first stage of larva. Eggs hatch out to form L1 larva in the **small intestine**.

- It is the **most common form** of the parasite found in the feces.
- It measures **0.25 mm in length**, with a relatively short muscular **double bulb esophagus** (**Fig. 3B**).
- The L1 larva **migrates into the lumen of the intestine** and passes down the gut to be released in feces.

Filariform Larva (L3 Stage)

This is the **third stage** of larva.

- L1 larva moults twice** to become the L3 larva.
- It is long and slender and measures **0.55 mm in length** with a **long esophagus of uniform width** and **notched tail** (**Fig. 3C**).
- It is the **infective stage** of the parasite to man.

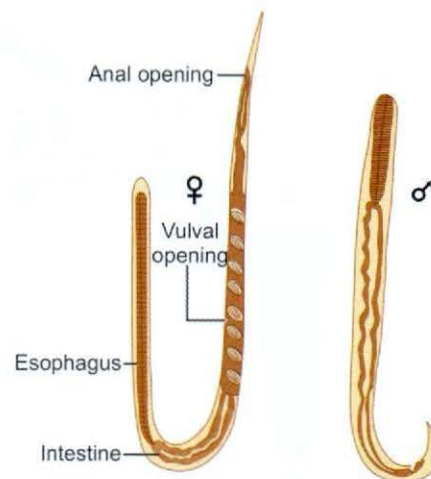


Fig. 1: Adult worm (male and female)

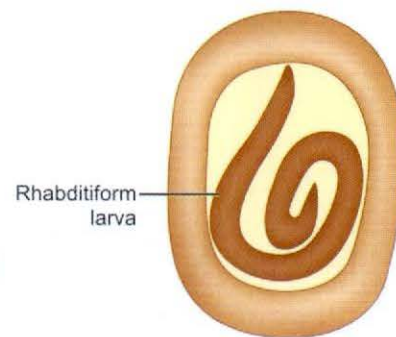
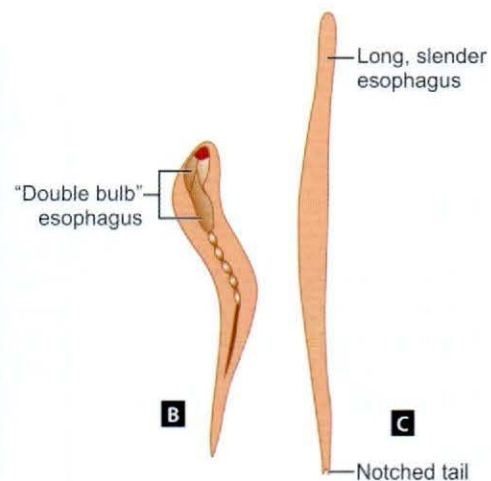
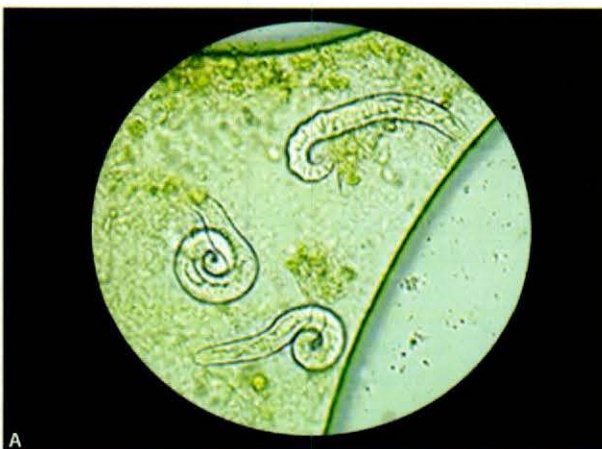

Fig. 2: Egg of *Strongyloides stercoralis*



Figs 3A to C: Larvae of *Strongyloides stercoralis*. (A and B) Rhabditiform Larva (Courtney Dr Anita Nandi); (C) Filariform larva

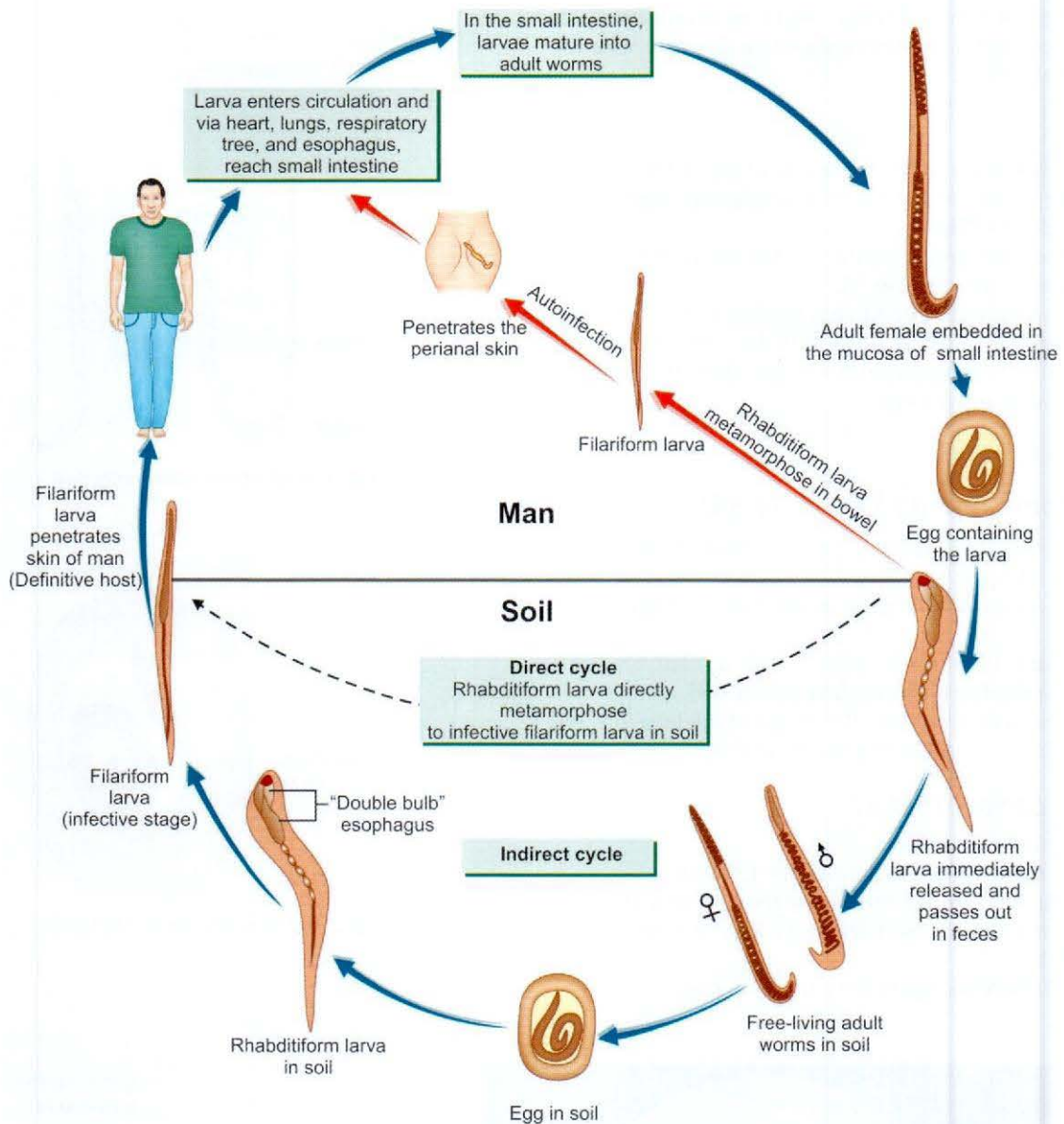


Fig. 4: Life cycle of *Strongyloides stercoralis*

■ LIFE CYCLE

The **life cycle of *S. stercoralis* is complex** because of the multiplicity of pathways through which it can develop. It is **unique among human nematodes** as it has a **parasitic cycle** and a **free-living soil cycle**, in which it can **persist for long periods in soil by feeding on soil bacteria**, passing through several generations (Fig. 4 and Flow chart 1).

Natural Host

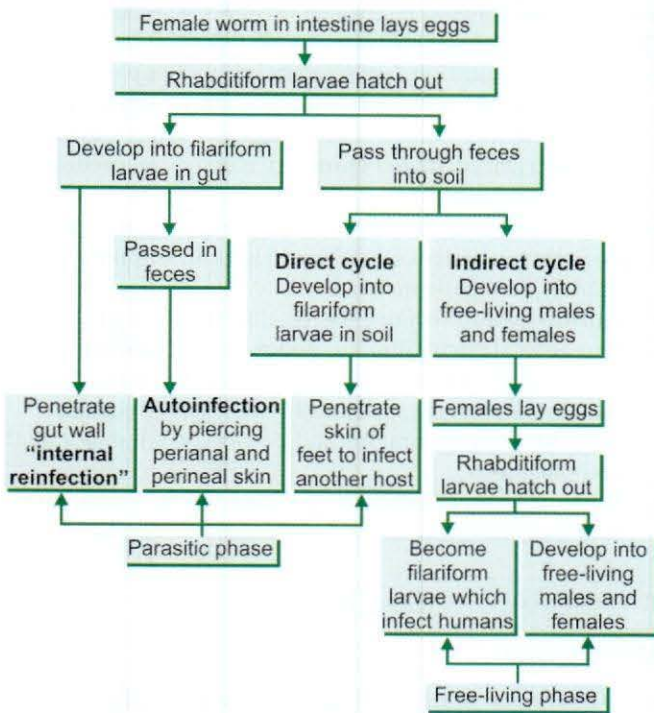
Man, although **dogs and cats** are found infected with morphologically indistinguishable strains.

Infective Form

Filariform larva.

• Mode of infection:

- **Penetration of skin** by the third stage filariform larva, when a person walks barefoot
- **Autoinfection (Box 2)**.
- The adult female worm is found in the human intestine embedded in the **mucosa of the duodenum and upper jejunum**.
- Since only the female worms are seen in the intestine, it was earlier believed that they are **parthenogenetic** and

Flow chart 1: Life cycle of *Strongyloides stercoralis*

Box 2: Autoinfection

- **External autoinfection:** *S. stercoralis* has a cycle of autoinfection. Here the rhabditiform larvae mature into the infective third stage larvae during their passage down the gut. These filariform larvae cause reinfection by piercing the perianal and perineal skin during defecation. The larvae wander in the dermis of the perianal region for sometime, causing a radiating perianal creeping eruption, a form of *cutaneous larva migrans*. They ultimately enter the lymphatics or venules and are carried to the right heart and the lungs to complete the life cycle as earlier.
- **Internal autoinfection:** In this type of autoinfection, seen typically in immunodeficient hosts, the rhabditiform larvae mature into the infective filariform larvae in the bowel itself. The filariform larvae penetrate the deeper layers of the intestine, to reach the mesenteric venules and are carried in circulation to complete the life cycle. This mode of autoinfection is called *internal reinfection*. It may lead to very heavy infection causing serious and sometimes even fatal illness.

can produce offsprings without being fertilized by the male. But, it has now been established that parasitic males do exist. They can be demonstrated in experimentally infected dogs. They are not seen in human infections because they do not invade the intestinal wall and so are eliminated from the bowel soon after the females begin to oviposit. However, the majority of females are probably parthenogenetic.

- The eggs laid in the mucosa hatch immediately, releasing rhabditiform larva.

- The rhabditiform larva migrates into the lumen of the intestine and passes down the gut to be released in feces.
- The rhabditiform larva may even metamorphose into filariform larva during passage through the bowel.
- These filariform larvae may penetrate colonic mucosa or perianal skin without leaving the host and going to the soil, thus providing a source of autoinfection. This ability to cause autoinfection explains the persistence of the infection in patients for long periods, even 30–40 years, after leaving the endemic areas.
- The rhabditiform larva voided with the feces may undergo two types of development in the soil (Flow chart 1):
 1. Direct development
 2. Indirect development.
- **Direct development:** The rhabditiform larva on reaching the soil moults twice to become the infective filariform larva.
 - Each rhabditiform larva gives rise to one filariform larva. When a person walks barefoot on soil containing the infective filariform larvae, they penetrate the skin and enter the circulation.
 - The larvae are carried along the venous circulation to the right side of the heart and to the lungs.
 - Here, they escape from the pulmonary capillaries into the alveoli, migrate up the respiratory tract to the pharynx, and are swallowed, reaching their final destination, small intestine.
 - In the intestine, they mature into adult parasitic females and males in 15–20 days. Female worms then burrow into the mucosa of the intestine and lays eggs.
 - The rhabditiform larvae hatch out immediately and enter into lumen of the bowel. They are excreted in the feces and thus, the life cycle is repeated.
- **Free-living phase/indirect development:** The rhabditiform larva passed in stools develop in moist soil into free-living males and females.
 - They mate in soil.
 - The fertilized female lays eggs, which hatch to release the next generation of rhabditiform larvae.
 - These may repeat the free-living cycle or may develop into the filariform larvae, which infect humans and initiate the parasitic phase.

■ PATHOGENICITY AND CLINICAL FEATURES

Strongyloidiasis (infection caused by *S. stercoralis*) is generally benign and asymptomatic. Blood eosinophilia and larvae in stool being the only indications of infection.

- Sometimes it may cause clinical manifestations, which may be severe and even fatal, particularly in those with defective immune response.
- The clinical disease may have cutaneous, pulmonary and intestinal manifestations.

Cutaneous Manifestations

There may be **dermatitis**, with **erythema** and **itching** at the site of penetration of the filariform larva, particularly when large numbers of larvae enter the skin.

- In those **sensitized by prior infection**, there may be an allergic response.
- **Pruritus** and **urticaria**, particularly around the perianal skin and buttocks, are **symptoms of chronic strongyloidiasis**.
- The term **larva currens** (meaning **racing larvae**) has been applied to the **rapidly progressing linear or serpiginous urticarial tracks** caused by **migrating filariform larvae**. These often follow **autoinfection** and **start perianally**.

Pulmonary Manifestations

When the larva escape from the pulmonary capillaries into the alveoli, small hemorrhages may **occur in the alveoli and bronchioles**.

- **Bronchopneumonia** may be present, which may **progress to chronic bronchitis** and **asthmatic symptoms** in some patients.
- Larva of *Strongyloides* may be found in the **sputum** of these patients.

Intestinal Manifestations

The symptoms may resemble those of **peptic ulcer** or of **malabsorption syndrome**.

- **Mucus diarrhea** is often present. In heavy infection, the **mucosa** may be **honeycombed** with the worm and there may be **extensive sloughing**, causing **dysenteric stools**.
- Other manifestations are **protein-losing enteropathy** and **paralytic ileus**.

Hyperinfection

In **debilitated individuals** and particularly in those with **cellular immune defects**, **extensive internal reinfection** takes

place, leading to an enormous number of adult worms in the intestines and lungs and larvae in various tissues and organs. This is known as **hyperinfection**.

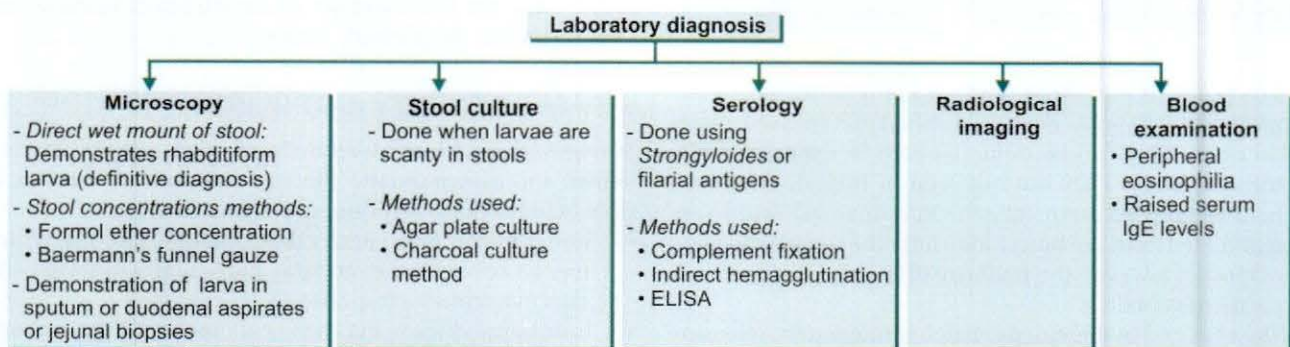
- Severe malnutrition, **lepromatous leprosy**, **lymphoreticular malignancies**, **acquired immunodeficiency syndrome (AIDS)**, **immunosuppressive drugs** and other situations, in which cell-mediated immunity is defective, predispose to this condition.
- **Hyperinfection is an important hazard of steroid therapy** and other instances of prolonged immunosuppression as in transplant patients.
- During hyperinfection, the **filariform larvae may enter into arterial circulation and lodge in various organs**, e.g. heart, lungs, brain, kidney, pancreas, liver and lymph nodes. Manifestations depend on the sites affected.
- **Brain abscess**, **meningitis** and **peritonitis** are major fatal complications.
- It has been reported that **circulating Strongyloides larvae** may carry **intestinal bacteria**, causing **septicemia**.

LABORATORY DIAGNOSIS

Microscopy

- **Direct wet mount of stool:** **Demonstration of the rhabditiform larvae** in freshly passed stools is the most important method of specific diagnosis. **Larvae found in stale stools have to be differentiated from larvae hatched from hookworm eggs (Flow chart 2)**.
- **Concentration methods of stool examination:** Stool may be concentrated by **formol-ether concentration method** or **Baermann's funnel gauze method** and examined for larvae more efficiently. **Baermann's test requires a special apparatus** and relies on the principle that **larva will actively migrate out of the feces on a wire mesh covered with several layers of gauze**.
- Larvae may sometimes be present in **sputum** or **duodenal aspirates** and **jejunal biopsies**.

Flow chart 2: Laboratory diagnosis of *Strongyloides stercoralis*



Abbreviations: ELISA, enzyme-linked immunosorbent assay; IgE, immunoglobulin E

Stool Culture

When larvae are scanty in stools, diagnosis may be facilitated by stool culture.

Culture techniques used:

- Agar plate culture
- Charcoal culture method.
- The larvae develop into free-living forms and multiply in charcoal cultures set up with stools. Large number of free-living larvae and adult worms can be seen after 7–10 days.
- Serial examinations and the use of agar plate detection method improves the sensitivity of stool diagnosis.

Serology

Serological tests have been described, using *Strongyloides* or filarial antigens.

- Complement fixation, indirect hemagglutination and enzyme-linked immunosorbent assay (ELISA) have been reported.
- Enzyme-linked immunosorbent assay has a sensitivity of 95% and should be used when microscopic examinations are negative.
- **Limitations of serological tests:**
 - Larval antigens are not freely available.
 - There is extensive cross-reactions with other helminthic infections.

Imaging

Radiological appearances in intestinal and pulmonary infection are said to be characteristic and helpful in diagnosis.

Others

- Peripheral eosinophilia (>500/cu mL of blood) is a constant finding. However, in severe hyperinfection, eosinophilia may sometimes be absent.
- Total serum immunoglobulin (Ig) E antibody level is elevated in more than half of the patients (Flow chart 2).

TREATMENT

All cases of *strongyloidiasis*, whether symptomatic or not, should be treated to prevent severe invasive disease.

- Ivermectin (200 mg/kg daily for 2 days) is more effective than albendazole (400 mg daily for 3 days).
- For disseminated strongyloidiasis, treatment with ivermectin should be extended for at least 5–7 days.

PROPHYLAXIS

Strongyloidiasis can be prevented by:

- Prevention of contamination of soil with feces.

- Avoiding contact with infective soil and contaminated surface waters.
- Treatment of all cases.

KEY POINTS OF STRONGYLOIDES STERCORALIS

- It is the smallest nematode infecting man.
- Adult worm lives in duodenum and jejunum of man.
- Females are ovoviviparous.
- Egg is ovoid, thin-walled and transparent.
- *Natural host:* Man (optimal host).
- *Infective form:* Third stage filariform larva.
- *Mode of transmission:* Penetration through the skin by the filariform larva in soil. Autoinfection can occur.
- *Clinical features:* Generally benign and asymptomatic, but may cause cutaneous, pulmonary and intestinal manifestations.
- *Diagnosis:* By demonstrating larva or adult females in stool or by demonstrating larval antigen by serological methods like ELISA.
- *Technique for stool concentration:* Baermann's technique and formol-ether concentration.
- *Techniques for stool culture:* Agar plate culture, charcoal culture.
- *Treatment:* Drug of choice is ivermectin or albendazole.

REVIEW QUESTIONS

1. Classify intestinal nematodes and describe briefly the life cycle of *Strongyloides*.
2. Short notes on:
 - a. *Strongyloides*
 - b. Hyperinfection
 - c. Larva currens
3. Differentiate between filariform larvae of hookworm and *Strongyloides*.

MULTIPLE CHOICE QUESTIONS

1. Parasites penetrating through skin for entry into the body are
 - a. *Trichinella*
 - b. *Strongyloides*
 - c. Roundworm
 - d. *Trichuris trichiura*
2. Larval form of the following parasites is found in stool except
 - a. *Strongyloides stercoralis*
 - b. *Ancylostoma duodenale*
 - c. *Ascaris lumbricoides*
 - d. *Necator americanus*
3. Autoinfection is seen with
 - a. *Cryptosporidium*
 - b. *Strongyloides*
 - c. *Giardia*
 - d. *Gnathostoma*

4. The term *larva currens* is used for migrating larva of

- a. *Strongyloides stercoralis*
- b. *Necator americanus*
- c. *Ancylostoma duodenale*
- d. *Hymenolepis nana*

5. Smallest nematode known to cause infection in man is

- a. *Trichinella spiralis*
- b. *Strongyloides stercoralis*
- c. *Ancylostoma duodenale*
- d. *Trichuris trichiura*

6. Infective form of *Strongyloides* is

- a. Eggs
- b. Rhabditiform larva
- c. Filariform larva
- d. Cercaria larva

7. Baermann's funnel gauze method is used for detection of larva of

- a. *Necator*
- b. *Strongyloides*
- c. *Ancylostoma*
- d. *Ascaris*

8. *Strongyloides* can be cultured in /by

- a. NNN medium
- b. Harada Mori method of stool culture
- c. Agar plate culture
- d. Hockmeyer's medium

Answer

- | | | | |
|------|------|------|------|
| 1. b | 2. c | 3. b | 4. a |
| 5. b | 6. c | 7. b | 8. c |

Hookworm

■ HISTORY AND DISTRIBUTION

Hookworms have been known since very ancient times. They have been referred to in the Ebers Papyrus (Circa 1600 BC).

- Two species of hookworms are human parasites: (1) *Ancylostoma duodenale* and (2) *Necator americanus*.
- *Ancylostoma duodenale* (Greek *ankylos*—hooked, *stoma*—mouth) was originally described by Dubini in 1843 in Italy. The life cycle of the worm was worked out by Looss in 1898 in Egypt.
- The second species *Necator americanus* was identified by Stiles in 1902 in specimens obtained from Texas, United States of America (USA). The name literally means the “American murderer” (Latin *necator*—murderer). It is called the American or the “New World” hookworm and *A. duodenale* the “Old World” hookworm. But, it is believed that *N. americanus* actually originated in Africa and was transported to America with the slave trade.
- Hookworm disease is prevalent throughout the tropics and subtropics. Even though it has been controlled in the advanced countries, it is estimated that it still affects some 900 million people, causing the loss of about 9 million liters of blood overall each day (Box 1).
- *A. duodenale* was prevalent along the Mediterranean coast of Europe and Africa, in northern India, China and Japan, while *N. americanus* was prevalent in Central and South America, Central and Southern Africa, Southern India, the Far East and the Southern Pacific region.

Box 1: Conditions favoring hookworm infection

- Presence of infected persons.
- Dispersal of eggs in soil due to indiscriminate defecation and inadequate processing of excreta.
- Appropriate environmental factors facilitating development of eggs in soil, and opportunity for the larva to infect people through their exposed skin surfaces.

Note: These conditions prevail throughout the year in most parts of the tropics, but in subtropical areas, these conditions exist only seasonally, being limited to the warmer months.

- However, in more recent times, movement of infected persons has blurred the geographic differences in distribution of the two species. For example, *A. duodenale* is now commonly seen along with *N. americanus* in South India and South East Asia.

■ ANCYLOSTOMA DUODENALE

Habitat

The adult worms live in the small intestines of infected persons, mostly in the *jejunum*, less often in the duodenum, and infrequently in the ileum.

Morphology

Adult Worm

They are relatively *stout cylindroidal* worms.

- They are pale pink or greyish white, but may appear reddish-brown due to ingested blood.
- The body is curved with the dorsal aspect concave and the ventral aspect convex. The anterior end is somewhat constricted and bent dorsally in the same direction of general body curvature. This cervical curvature gave it the name *hookworm* (Fig. 1).
- The mouth is not at the tip but directed dorsally. The prominent *buccal capsule*, reinforced with a hard chitin-like substance carries *six teeth*, four hook-like teeth ventrally and two knob-like with a median cleft dorsally.

Male worm: The male worm is smaller than female worm—8–11 mm in length and 0.4 mm thick.

- The posterior end of the male is expanded into a copulatory bursa which consists of *three lobes*, one dorsal and two lateral. There are *13 fleshy chitinous rays*, five each in lateral lobes and three in dorsal lobe. The dorsal ray is partially divided at the tip and each division is *tripartite*. The pattern of the rays helps in distinguishing between different species.

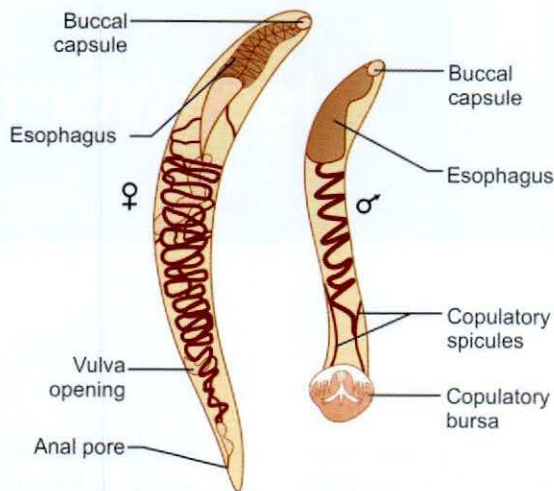


Fig. 1: Adult worm of *Ancylostoma duodenale* (male and female)

Table 1: Distinguishing features of male and female worms of *Ancylostoma duodenale*

	Male	Female
Size	Smaller, about 8–11 mm in length	Larger, 10–13 mm in length
Copulatory bursa	Present	Absent
Genital opening	Opens in cloaca along with anus	Opens at the junction of the middle and posterior third of body
Posterior end	Expanded in like umbrella	Tapering

- The cloaca into which the rectum and genital canal open is situated within the copulatory bursa.
- There are two long retractile bristle-like *copulatory spicules*, the tips of which project from the bursa.

Female worm: The female worm is larger, 10–13 mm long and 0.6 mm thick.

- Its hind end is conoid, with a subterminal anus situated ventrally.
- The vulva opens ventrally at the junction of the middle and posterior thirds of the body.
- The vagina leads to two intricately coiled ovarian tubes which occupy the hind and middle parts of the worm.
- During copulation the male attaches its copulatory bursa to the vulva. The copulating pair therefore presents a **Y-shaped** appearance.
- Sexes are easily differentiated by their size, the shape of the posterior end and the position of the genital opening (Table 1).

Egg

The egg of hookworm is:

- Oval or elliptical, measuring 60 μm by 40 μm .
- Colorless, **not bile stained**.
- Surrounded by a thin transparent hyaline shell membrane.
- Floats in saturated salt solution.
- When released by the worm in the intestine, the egg contains an unsegmented ovum.
- During its passage down the intestine, the ovum develops. When passed in feces, the egg contains a segmented ovum, usually with **four or eight blastomeres**.
- There is a **clear space** between the segmented ovum and the egg shell (Figs 2A and B).
- A single female worm lays about 25,000–30,000 eggs in a day and some 18–54 million during its life time.

Life Cycle

Life cycle of *Ancylostoma* is completed in a **single host** (Fig. 3).

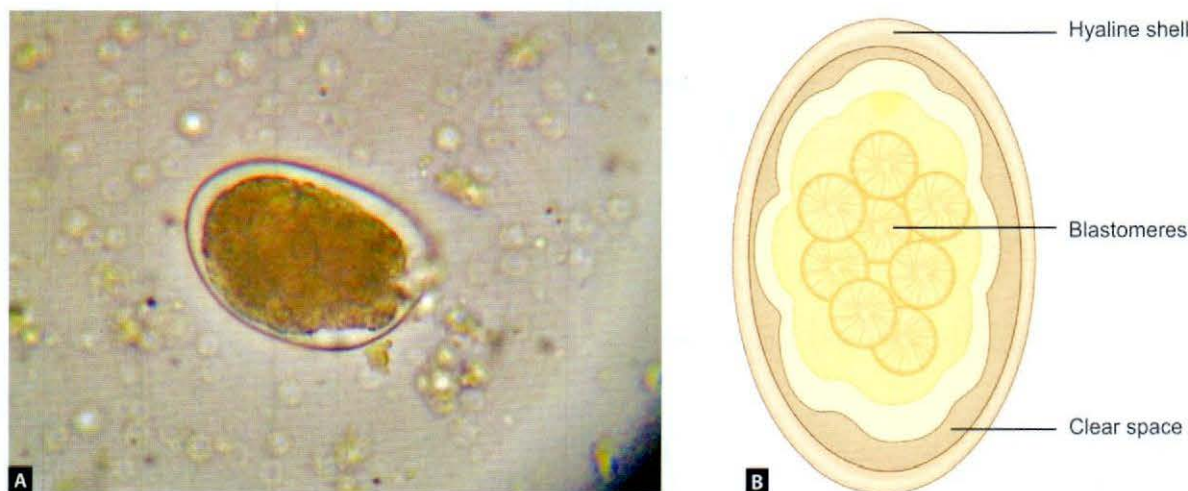
Definitive Host

Humans are the only natural host. No intermediate host is required like other helminths (Box 2).

Infective Form

Third-stage filariform larva.

- Adult worm inhabiting the small intestine of man attach themselves to the mucous membrane by means of their mouth parts. The female worm lays eggs.
- The eggs containing segmented ova with four blastomeres, are passed out in the feces of infected person (Fig. 3). Eggs freshly passed in feces are not infective for humans.
- When deposited in the soil, the embryo develops inside the eggs. Its development takes place optimally in sandy loamy soil with decaying vegetation under a moist, warm, shady environment.
- In about 2 days, a **rhabditiform larva**, measuring 250 μm in length, hatches out of the egg. It feeds on bacteria and other organic matter in the soil and grows in size (Fig. 3).
- It **moults twice**, on the **3rd and 5th days** after hatching to become the **third-stage infective filariform larva** (Fig. 3).
- **Filariform larva** is about 500–600 μm long, with a sharp pointed tail. The filariform larva is nonfeeding. They can live in the soil for 5–6 weeks, with their heads waving in the air, waiting for their hosts. They can also ascend on blades of grass or other vegetation, being carried in capillary water films on their surface. Direct sunlight, drying, or salt water can kill the larva.
- **Mode of infection:**
 - When a person walks *barefooted* on soil containing the filariform larva, they penetrate the *skin* and enter



Figs 2A and B: Egg of *Ancylostoma duodenale*. (A) As seen under microscope; and (B) Schematic diagram

Box 2: Helminths requiring no intermediate host

- *Ancylostoma duodenale*
- *Necator americanus*
- *Ascaris lumbricoides*
- *Trichuris trichiura*
- *Enterobius vermicularis*
- *Hymenolepis nana*

the subcutaneous tissue. The common sites of entry are the skin between the toes, the dorsum of the foot and the medial aspect of the sole. In farm workers and miners, the larvae may penetrate the skin of the hands.

- Rarely, infection may take place by the oral route, the filariform larva being carried on contaminated vegetables or fruits. The larvae may penetrate the buccal mucosa to reach the venous circulation and complete their migration via the lungs.
- Transmammary and transplacental transmission has been also reported for *Ancylostoma*, but not for *Necator*.
- Inside the human body, the larvae are carried along the venous circulation to the right side of the heart and to the lungs. Here, they escape from the pulmonary capillaries into the alveoli, migrate up the respiratory tract to the pharynx, and are swallowed, reaching their final destination, small intestine.
- During migration or on reaching the esophagus, they undergo **third moulting**.
- They feed, grow in size, and undergo a **fourth** and **final moulting** in the small intestine and develop the buccal capsule, by which they attach themselves to the small intestine and grow into adults.

- There is no multiplication in the host and a single infective larva develops into a single adult, male or female.
- It takes usually about **6 weeks** from the time of infection for the adult worms to become sexually mature and start laying eggs. But sometimes, there may be an arrest in development and the process may take much longer, 6 months or more.
- Alternatively, the larvae may be swallowed and may develop directly into adults in the small intestine without a tissue phase.

■ *NECATOR AMERICANUS*

Morphology

The adult worms are slightly smaller than *A. duodenale*, the male being 7–9 mm by 0.3 mm and the female 9–11 mm by 0.4 mm.

- The anterior end is bent in a **direction opposite** to the general curvature of the body, while in *A. duodenale* the bend is in the **same direction**.
- They have a smaller buccal capsule with **two pairs of semilunar cutting plates** instead of teeth as in *A. duodenale*.
- The copulatory bursa of the male is long and wide. The copulatory spicules are fused at the ends to form a barbed tip.
- In female, the vulva is placed in the middle of the body or anterior to it (**Figs 4A to C**).

The eggs of *N. americanus* are identical with those of *A. duodenale*. Their life cycle is similar to that of *A. duodenale*. The lifespan of *Necator* is much longer being about 4–20 years than in *Ancylostoma*, where it is of 2–7 years.

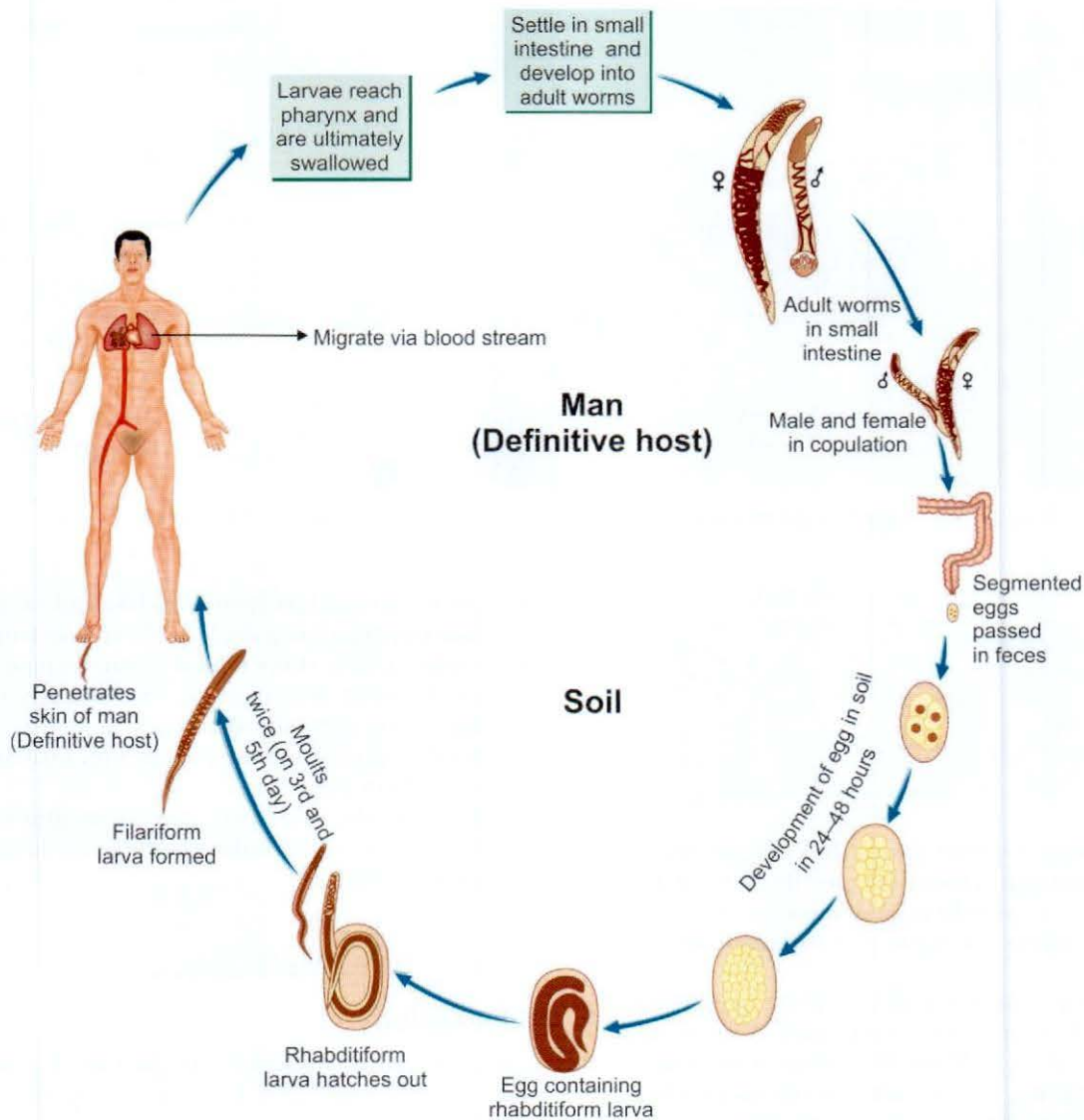


Fig. 3: Life cycle of *Ancylostoma duodenale*

The differentiating features of *A. duodenale* and *N. americanus* have been discussed in **Table 2** and differentiating features between filariform larva of both species has been discussed in **Table 3**.

■ PATHOGENICITY AND CLINICAL FEATURES OF HOOKWORM INFECTION

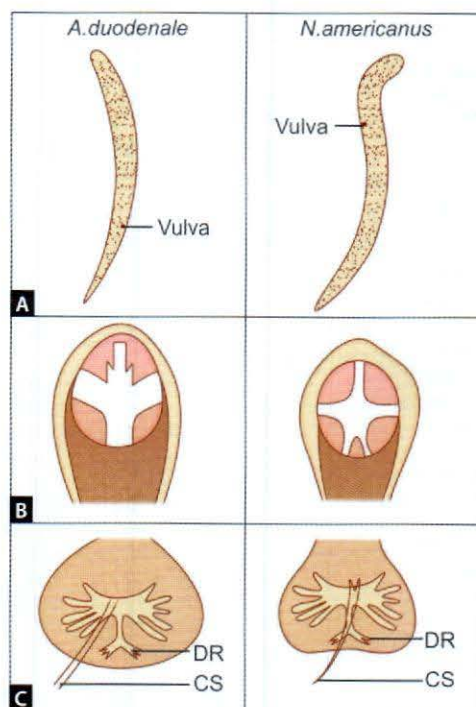
Effects Due to Migrating Larva

- **Ground itch:** Larvae may give rise to severe itching at the site of penetration. It is more common in *N. americanus* than in *A. duodenale*.

- **Creeping eruption:** It is formed due to subcutaneous migration of filariform larvae. There is reddish itchy papule along the path traversed by them.
- **Respiratory system:** Mild transient pneumonitis, or bronchitis occurs when larvae break out of pulmonary capillaries into alveoli.

Effect Due to Adult Worm

- **Early hookworm infection:** Adult worms produce epigastric pain, dyspepsia, nausea, vomiting and diarrhea.
- **Chronic hookworm infection:** It leads to *iron deficiency anemia* and *protein energy malnutrition* resulting from



Figs 4A to C: Major distinguishing features between *Ancylostoma duodenale* and *N. americanus*. (A) Adult female in *Ancylostoma*—anterior curvature uniform with body curve; in *Necator* anterior curvature in opposite direction to body curve. Vulva opens at junction of middle and posterior thirds in *Ancylostoma*; in (*Necator*) it opens a little in front of the middle; (B) Buccal capsule, (*Ancylostoma*) has two pairs of hook-like teeth ventrally and a dental plate with median cleft dorsally; (*Necator*) has two pairs of semilunar cutting plates instead of teeth; and (C) Copulatory bursa. In (*Ancylostoma*), the dorsal ray (DR) is single with a split end, making a total of 13 rays; (*Necator*) has a paired dorsal ray, making a total of 14 rays. Copulatory spicules (CS) separate in (*Ancylostoma*); they are fused at the tip in (*Necator*)

blood loss. Adult worms attach themselves to intestinal wall by buccal capsule and teeth and suck blood.

- *A. duodenale* ingests **0.15–0.25 mL** of blood and *N. americanus* **0.03 mL** of blood per day. They also secrete anticoagulants at the attachment site so that bleeding from these sites continue. There is also interference of absorption of **iron, vitamin B12 and folic acid**.

The pathogenesis and clinical features has been described in **Flow chart 1**.

LABORATORY DIAGNOSIS

Direct Methods

- Demonstration of characteristic oval segmented hookworm eggs in feces by **direct wet microscopy** or by

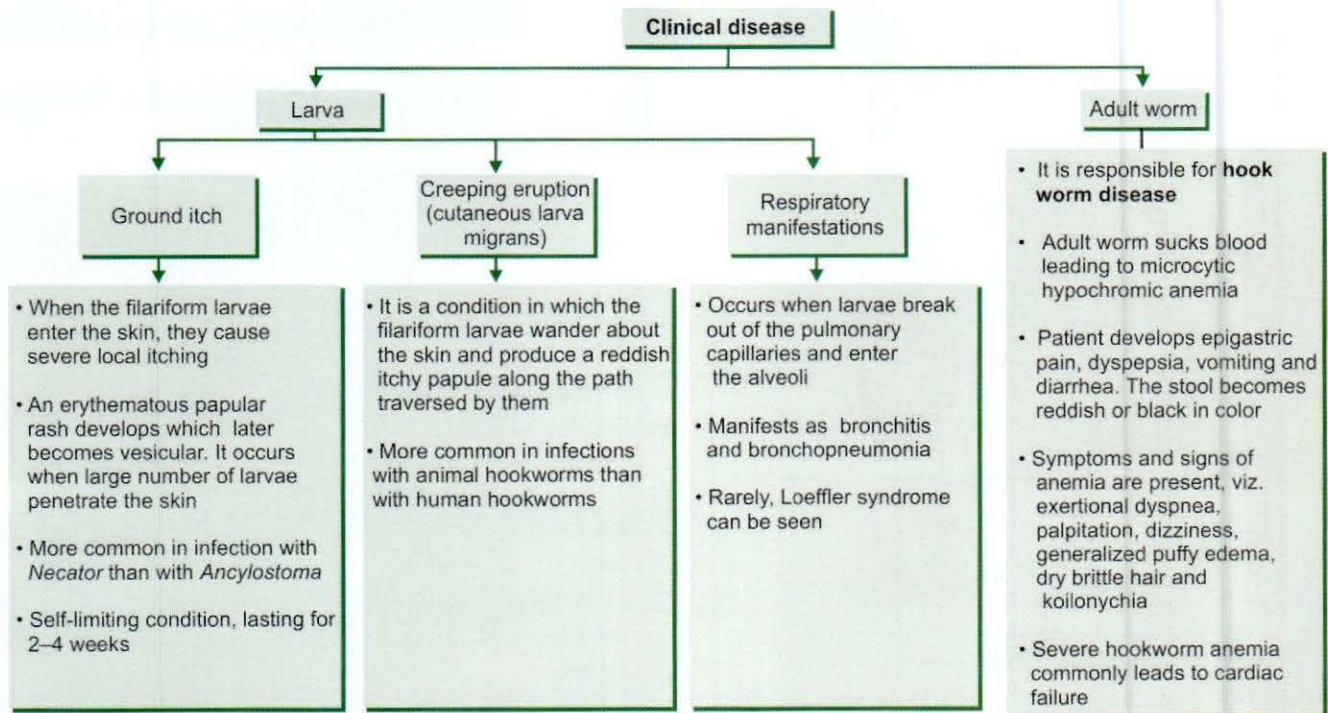
Table 2: Differentiating features of two species of hookworm

	<i>Ancylostoma duodenale</i>	<i>Necator americanus</i>
<i>Adult worms</i>		
Size	Large and thicker	Small and slender
Shape	Head bent in same direction as body	Head bent in opposite direction
Buccal capsule	Four ventral teeth and two dorsal knob-like teeth	Two ventral and two dorsal chitinous cutting plates
Copulatory bursa	13 rays, two separate spicules, dorsal ray single	14 rays, two spicules fused at the tip, dorsal ray split
Caudal spine in female	Present	Absent
Vulval opening	Situated behind the middle of the body	Situated in anterior to middle part of body
Pathogenicity	More	Comparatively less
Eggs	Similar	Similar
First and second stage larva	Similar	Similar
Egg/day	15,000–20,000	6,000–11,000
Rate of development	Faster	Slower
Pulmonary reaction	More common	Less common
Blood loss/worm	0.2 mL/day	0.03 mL/day
Iron loss (mg/day)	0.76 mg	0.45 mg
Male:female ratio	1:1	1.5:1
Life span	2–7 years	4–20 years

Table 3: Differential features of filariform larva (third-stage larva)

	<i>Ancylostoma duodenale</i>	<i>Necator americanus</i>
Size	720 μ m	660 μ m
Head	Slightly conical	Rounded
Buccal cavity	Short, lumen larger	Larger, lumen shorter
Sheath	Faint cuticular striations	Prominent striation
Intestine	No gap between esophagus and intestine	A gap is present between esophagus and intestine
Posterior end of intestine	A small retractile body is present	No retractile body
Esophageal spurs	Not prominent	Prominent
Tail	Long and blunt	Short and pointed

Flow chart 1: Clinical disease in hookworm



concentration methods is the best method of diagnosis. In stool samples examined 24 hours or more after collection, the eggs may have hatched and rhabditiform larvae may be present. These have to be differentiated from *Strongyloides larvae*.

- **Egg counts** give a measure of the intensity of infection. **Modified Kato-Katz smear technique** is a useful method for quantitative estimation of eggs in stool. A count of less than five eggs per mg of feces seldom causes clinical disease, while counts of 20 eggs or more are associated with significant anemia (**Box 3**). Egg counts of 50 or more represent massive infection.
- Adult hookworms may sometimes be seen in feces. Eggs of *A. duodenale* and *N. americanus* cannot be differentiated by morphology. Thus specific diagnosis can only be made by studying morphology of adult worms.
- Duodenal contents may reveal eggs or adult worms.
- **Stool culture: Harada-Mori method** of stool culture is carried out to demonstrate third-stage filariform larvae which helps in distinguishing *A. duodenale* and *N. americanus* (**Flow chart 2**).

Indirect Methods

- Blood examination reveals microcytic, hypochromic anemia and eosinophilia.

Box 3: Causes of anemia in hookworm infection

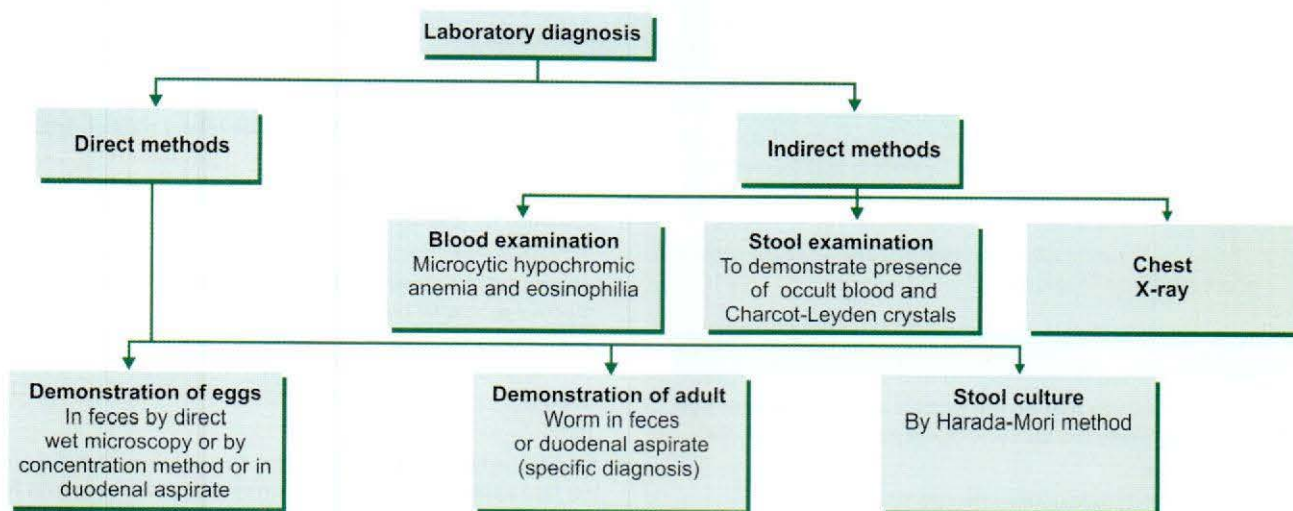
- Blood sucking by the parasite for their food.
- Chronic hemorrhages from the punctured sites from jejunal mucosa.
- Deficient absorption of vitamin B12 and folic acid.
- Depression of hematopoietic system by deficient intake of proteins.
- Average blood loss by the host per worm per day is 0.03 mL with *N. americanus* and 0.2 mL with *A. duodenale*.
- With iron deficiency, **hypochromic microcytic anemia** is caused and with deficiency of both iron and vitamin B12 or folic acid, **dimorphic anemia** is caused.
- Secretion of anticoagulants at the site of attachment.

- Stool examination may show occult blood and Charcot-Leyden crystals (**Flow chart 2**).
- Chest X-ray may show pulmonary infiltrates in the migratory phase.

TREATMENT

- For specific antihelminthic treatment, the most practical and effective drug is albendazole (400 mg single dose) or mebendazole (500 mg once). Pyrantel pamoate (11 mg/kg × 3 days) is also effective and can be used in pregnancy. Thiabendazole is less effective. The old drug tetrachloroethylene is active, but toxic. Bephenium

Flow chart 2: Laboratory diagnosis of hookworm



hydroxynaphthoate is active against *Ancylostoma* but not against *Necator*.

- Treatment of hookworm disease also includes relief of anemia. In hookworm disease, the intestinal absorption of iron is apparently normal so that oral administration of iron can correct the anemia, but in severe cases, a preliminary packed cell transfusion may be needed. When the hemoglobin level is very low, antihelminthic drugs should not be used before correcting the anemia.

■ PROPHYLAXIS

- Prevention of soil pollution with feces and proper disposal of night soil and use of sanitary latrines.
- Use of footwear to prevent entry of larva through the skin of the foot. Gloves give similar protection to the hands of farm workers.
- Treatment of patients and carriers, preferably all at the same time, limit to the source of infection.

■ OTHER HOOKWORMS

Ancylostoma ceylanicum naturally parasitizes cats and wild felines in South-East Asia, but can occasionally infect man. *A. braziliense*, a parasite of cats and dogs and some other species of animal ancylostomes have been reported to infect man, but they tend to cause creeping eruption (larva migrans) rather than intestinal infection.

■ TRICHOSTRONGYLIASIS

- *Trichostrongylus* species, normally parasitic in sheep and goats, can also cause human infections.

- This is particularly likely, where the use of night soil as manure is prevalent.
- The infection is present in some parts of India.
- The life cycle is similar to that of hookworms.
- Human infection is usually acquired by ingestion of leafy vegetables carrying the third-stage larva.
- Adults attach themselves to small intestinal mucosa, suck blood and live for long periods. Infection is mostly asymptomatic but epigastric discomfort and anemia with marked eosinophilia occur in massive infections.
- The eggs passed in feces resemble hookworm eggs, but are larger, with more pointed ends and show greater segmentation with 16–32 blastomeres. Metronidazole is effective in treatment.

KEY POINTS OF HOOKWORM

- *A. duodenale* is the Old World hookworm and *N. americanus* is the New World hookworm.
- Adult worm live in small intestine (jejunum and duodenum).
- In *A. duodenale*, the anterior end is bent dorsally in the same direction of body curvature, hence the name hookworm. The mouth contains six teeth, four hook-like teeth ventrally and two knob-like dorsally. Posterior end of male has a copulatory bursa.
- Female is longer than male with tapering end.
- Eggs are oval, colorless, not bile-stained, and float in saturated salt solution and contain segmented ovum with four blastomeres.
- *Natural host*: Humans, life cycle is completed in a single host.
- *Infective form*: Third-stage filariform larva.
- *Portal of entry*: Penetration of skin.

Contd...

Contd...

- **Clinical features:** Ground itch, creeping eruption (cutaneous larva migrans), bronchitis and bronchopneumonia in lung, hypochromic microcytic or dimorphic anemia and intestinal symptoms like epigastric pain, dyspepsia, nausea and pica.
- **Diagnosis:** Done by demonstration of characteristic egg in the feces by direct microscopy or by concentration methods or by demonstration of adult worms in stool or duodenal aspirate.
- **Treatment:** Albendazole, mebendazole and pyrantel pamoate. Oral iron in anemia.

REVIEW QUESTIONS

1. Name the helminths that do not require any intermediate host and describe briefly the life cycle of *Ancylostoma duodenale*.
2. Short notes on:
 - a. Causes of anemia in hookworm infection
 - b. Clinical disease in hookworm infection
 - c. Trichostrongyliasis
 - d. Prevention of hookworm infection
3. Differentiate between:
 - a. Male and female of *Ancylostoma duodenale*
 - b. *Ancylostoma duodenale* and *Necator americanus*
 - c. Filariform larvae of *Ancylostoma* and *Necator*

MULTIPLE CHOICE QUESTIONS

1. Highest incidence of anemia in the tropics is due to
 - a. Hookworm
 - b. Thread worm
 - c. Ascaris
 - d. Guinea worm

2. The average blood loss per worm in ancylostomiasis is
 - a. 0.2 mL/day
 - b. 2 mL/day
 - c. 0.33 mL/day
 - d. 1 mL/day
3. Which of the following does not cause biliary tract obstruction
 - a. *Ascaris lumbricoides*
 - b. *Ancylostoma duodenale*
 - c. *Clonorchis sinensis*
 - d. *Fasciola hepatica*
4. Which of the following stages of *Ancylostoma duodenale* is infective to human beings
 - a. Rhabditiform larva
 - b. Filariform larva
 - c. Eggs
 - d. Adult worm
5. A 6-year-old girl is emaciated with a hemoglobin level of 6 g/dL. Her face appears puffy with swollen eyelids and edema over feet and ankles. There are no laboratory facilities available. The most likely cause of the child's condition is
 - a. Schistosomiasis
 - b. Cercarial dermatitis
 - c. Ascariasis
 - d. Hookworm disease
6. All of the following are characteristics of *Ancylostoma* except
 - a. Its copulatory bursa has 13 rays
 - b. Caudal spine is present in females
 - c. Head is bent in a direction opposite to body
 - d. Vulval opening is situated in the middle of the body.

Answer

1. a 2. a 3. b 4. b 5. d 6. c

Enterobius Vermicularis

■ INTRODUCTION

The name *Enterobius vermicularis* means a tiny worm living in the intestine (Greek *enteron*—intestine, *bios*—life and *vermiculus*—small worm). The term *Oxyuris* means “sharp tail”, a feature of the female worm, from which the name “pinworm” is also derived.

■ COMMON NAME

Pinworm, seatworm, threadworm.

■ HISTORY AND DISTRIBUTION

Enterobius vermicularis, formerly called *Oxyuris vermicularis* has been known from ancient times.

- Leuckart (1865) first described the complete life cycle of the parasite.
- It is worldwide in distribution. Unlike the usual situation, where helminthic infections are more prevalent in the poor people of the tropics, *E. vermicularis* is one worm infestation which is far more common in the affluent nations in the cold and temperate regions (cosmopolitan).
- *Enterobius vermicularis* is considered to be *world’s most common* parasite, which specially affects the children.

■ HABITAT

Adult worms are found in the cecum, appendix and adjacent portion of ascending colon.

■ MORPHOLOGY

Adult Worm

The adults are short, white, **fusiform worms** with pointed ends, looking like bits of white thread.

- The mouth is surrounded by three wing-like cuticular expansions (cervical alae), which are transversely striated.

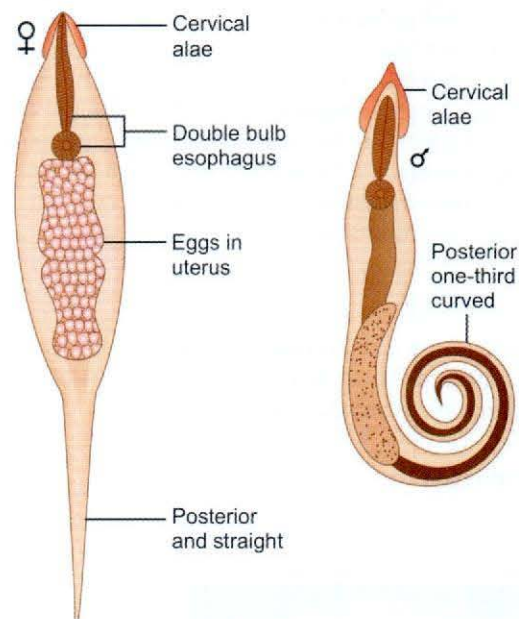


Fig. 1: Adult worm of *Enterobius vermicularis* (male and female)

- The esophagus has a **double bulb structure**, a feature unique to this worm (Fig. 1).

Female Worm

The female is 8–13 mm long and 0.3–0.5 mm thick.

- Its posterior third is drawn into a thin pointed **pin-like tail** (Fig. 1).
- The vulva is located just in front of the middle third of the body and opens into the single vagina, which leads to the paired uteri, oviducts and ovaries. In the gravid female, virtually the whole body is filled by the distended uteri carrying thousands of eggs.
- The worm is **oviparous**.
- Females survive for 5–12 weeks.

Male Worm

The male worm is 2–5 mm long and 0.1–0.2 mm thick.

- Its posterior end is tightly curved ventrally, sharply truncated and carries a prominent copulatory spicule (**Fig. 1**).
- Males live for about 7–8 weeks.

Egg

The egg is colorless and **not bile-stained**.

- It floats in saturated salt solution.
- It has a characteristic shape, being elongated ovoid, flattened on one side and convex on the other (**planoconvex**), measuring 50–60 μm by 20–30 μm (**Fig. 2**).
- The egg shell is double-layered and relatively thick, though transparent. The outer albuminous layer makes the eggs stick to each other and to clothing and other objects.
- The egg contains a **tadpole-shaped** coiled embryo, which is fully formed, but becomes infectious only 6 hours after being deposited on the skin. Under cool moist conditions, the egg remains viable for about 2 weeks (**Fig. 2**).
- A single female worm lays 5,000–17,000 eggs.

■ LIFE CYCLE

Enterobius vermicularis is **monoxenous**, passing its entire life cycle in the human host. It has no intermediate host and does not undergo any systemic migration (**Box 1**).

Natural Host

Man.

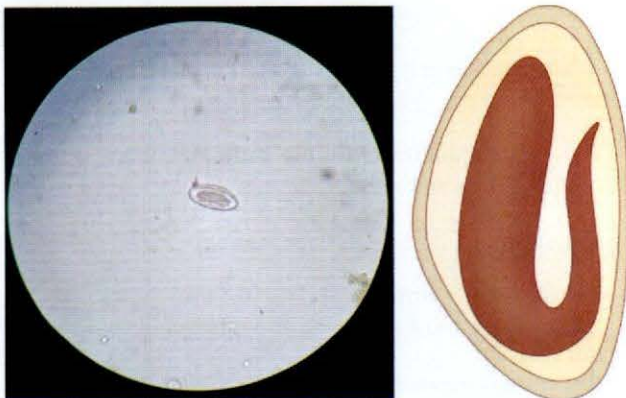


Fig. 2: Planoconvex egg of *Enterobius vermicularis* containing tadpole-shaped embryo

Box 1: Nematodes not showing systemic migration in man

- *Enterobius vermicularis*
- *Trichuris trichiura*.

Infective Form

Embryonated Eggs

- **Mode of infection:** Man acquires infection by ingesting embryonated eggs containing larva by means of:
 - Contaminated fingers
 - Autoinfection.
- Eggs laid on perianal skin containing infective larvae are swallowed and hatch out in the intestine.
- They moult in the ileum and enter the cecum, where they mature into adults.
- It takes from 2 weeks to 2 months from the time the eggs are ingested, to the development of the gravid female, ready to lay eggs.
- The gravid female migrates down the colon to the rectum. At night, when the host is in bed, the worm comes out through the anus and crawls about on the perianal and perineal skin to lay its sticky eggs. The worm may retreat into the anal canal and come out again to lay more eggs.
- The female worm may wander into the vulva, vagina and even into the uterus and fallopian tubes, sometimes reaching the peritoneum.
- The male is seldom seen as it does not migrate. It usually dies after mating and is passed in the feces.
- When all the eggs are laid, the female worm dies or gets crushed by the host during scratching. The worm may often be seen on the feces, having been passively carried from the rectum. The eggs, however, are only infrequently found in feces, as the female worm lays eggs in the perianal area and not the rectum.
- Crawling of the gravid female worm leads to pruritus and the patient scratches the affected perianal area. These patients have eggs of *E. vermicularis* on fingers and under nails leading to autoinfection (**Fig. 3**).
- **Autoinfection:** Ingestion of eggs due to scratching of perianal area with fingers leading to deposition of eggs under the nails. This type of infection is mostly common in children. This mode of infection occurs from anus to mouth.
- **Retroinfection:** In this process, the eggs laid on the perianal skin immediately hatch into the infective stage larva and migrate through the anus to develop into worms in the colon. This mode of infection occurs from anus to colon.

■ PATHOGENICITY AND CLINICAL FEATURES

Enterobiasis occurs mostly in **children**. It is more common in females than in males. About one-third of infections are asymptomatic.

- The worm produces intense irritation and pruritus of the perianal and perineal area (**pruritus ani**), when it crawls out of the anus to lay eggs. This leads to scratching and excoriation of the skin around the anus.

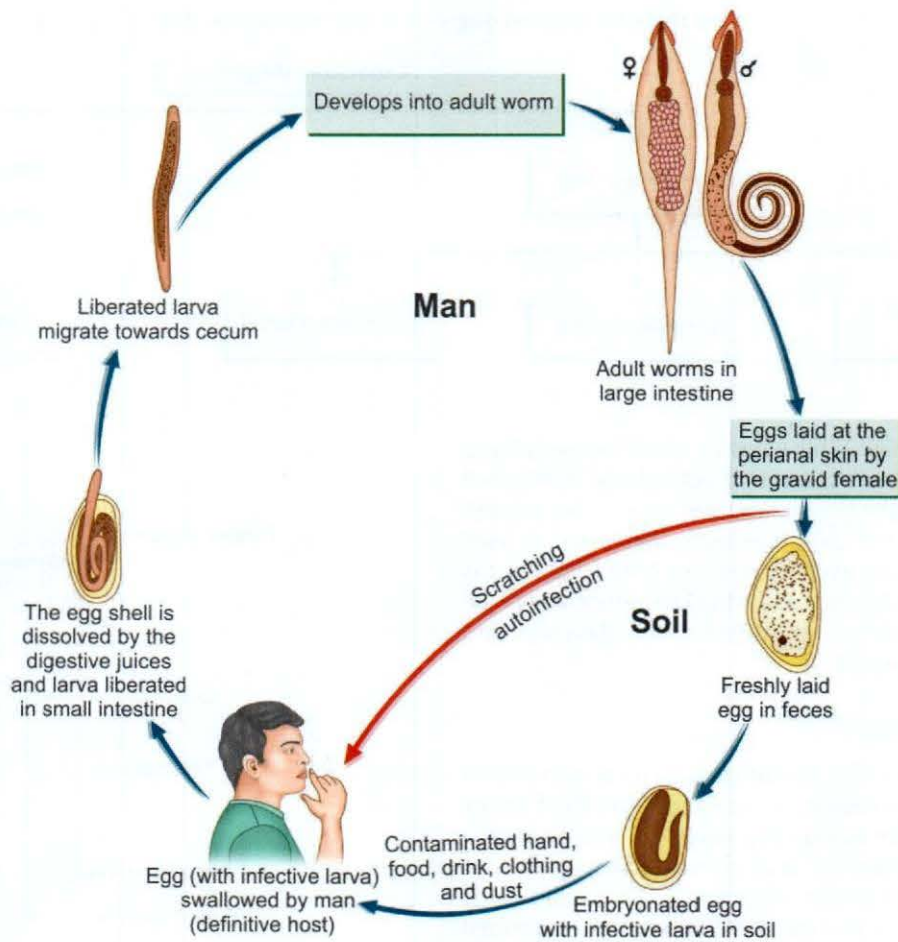


Fig. 3: Life cycle of *Enterobius vermicularis*

- As the worm migrates out at night, it disturbs sleep. **Nocturnal enuresis** is sometimes seen.
- The worm crawling into the vulva and vagina causes irritation and a mucoid discharge. It may migrate up to the uterus, fallopian tubes and into the peritoneum. This may cause symptoms of *chronic salpingitis*, cervicitis, peritonitis and recurrent urinary tract infections.
- The worm is sometimes found in surgically removed appendix and has been claimed to be responsible for *appendicitis*.

■ LABORATORY DIAGNOSIS

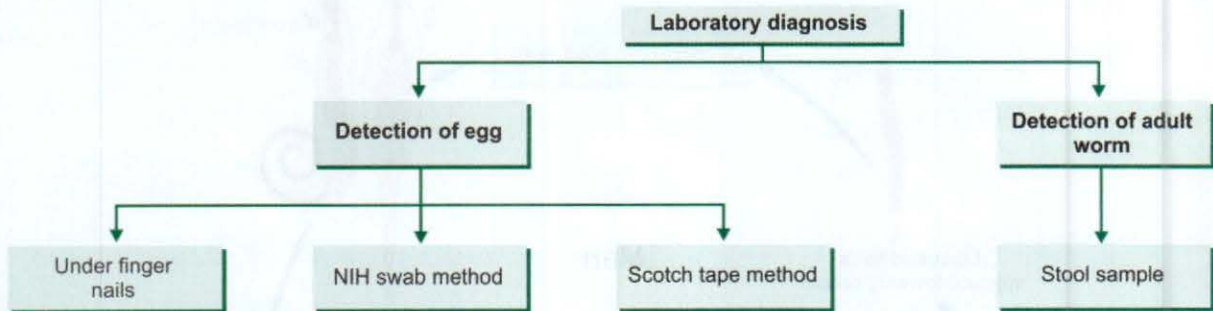
Pinworm infestation can be suspected from the history of perianal pruritus. Diagnosis depends on the demonstration of the eggs or adult worms (**Flow chart 1**).

Demonstration of Eggs

- Eggs are present in the feces only in a small proportion of patients and so feces examination is not useful in diagnosis.
- They are deposited in large numbers on the perianal and perineal skin at night and can be demonstrated in swabs collected from the sites early morning, before going to the toilet or bathing. Swabs from perianal folds are most often positive.
- The eggs may sometimes be demonstrated in the dirt collected from beneath the finger nails in infected children.

NIH Swab Method

The *NIH swab* [named after National Institutes of Health, United States of America (USA)] has been widely used for

Flow chart 1: Laboratory diagnosis of *Enterobius vermicularis*

collection of specimens. This consists of a glass rod at one end of which a piece of transparent cellophane is attached with a rubber band. The glass rod is fixed on a rubber stopper and kept in a wide test tube. The cellophane part is used for swabbing by rolling over the perianal area (Fig. 4). It is returned to the test tube and sent to the laboratory, where the cellophane piece is detached, spread over a glass slide and examined microscopically.

Scotch Tape Method

Another method for collection of specimens is with scotch tape (adhesive transparent cellophane tape) held sticky side out, on a wooden tongue depressor. The mounted tape is firmly pressed against the anal margin, covering all sides (Fig. 5). The tape is transferred to a glass slide, sticky side down, with a drop of toluene for clearing and examined under the microscope.

Demonstration of Adult Worm

The adult worms may sometimes be noticed on the surface of stools.

- They may occasionally be found crawling out of the anus while the children are asleep.
- They may be detected in stools collected after an enema and may be in the appendix during appendectomy (Box 2).

Note: Unlike the other intestinal nematodes, *Enterobius* infection is not associated with eosinophilia or with elevated immunoglobulin E (IgE).

■ TREATMENT

Pyrantel pamoate (11 mg/kg once, maximum 1 g), albendazole (400 mg once) or mebendazole (100 mg once) can be used for single dose therapy, while piperazine has to be given daily for 1 week.

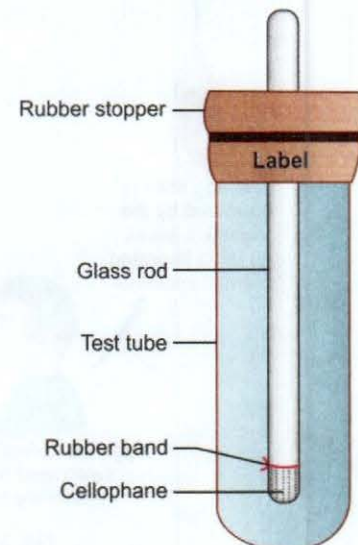


Fig. 4: National Institutes of Health (NIH) swab. A piece of transparent cellophane is attached with rubber band to one end of a glass rod, which is fixed on a rubber stopper and kept in a wide test tube

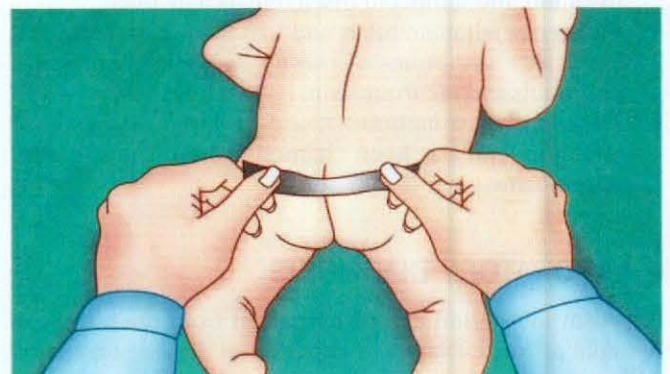


Fig. 5: Scotch tape method (press the sticky side of the tape against the skin across the anal opening)

Box 2: Infectious parasites which may be present in a fecal sample

- *Enterobius vermicularis*
- *Strongyloides stercoralis*
- *Taenia solium*
- *Hymenolepis nana*
- *Entamoeba histolytica*
- *Giardia lamblia*
- *Cryptosporidium parvum*

- It is necessary to repeat the treatment after 2 weeks to take care of autochthonous infections and ensure elimination of all worms.
- As pinworm infection usually affects a group, it is advisable to treat the whole family or group of children, as the case may be.

■ PROPHYLAXIS

- Maintenance of personal and community hygiene such as frequent hand washing, finger nail cleaning and regular bathing.
- Frequent washing of night clothes and bed linen.

KEY POINTS OF ENTEROBIUS VERMICULARIS

- Adult worm lives in cecum and appendix.
- Mouth is surrounded by three wing-like cervical alae. Esophagus has a double bulb structure.
- Worm is oviparous.
- Eggs are colorless, not bile-stained; plano-convex in shape.
- *Natural host:* Humans. *E. vermicularis* passes its entire life cycle in human host. No intermediate host is required.
- *Infective form:* Embryonated egg containing infective larva.
- *Mode of infection:* By ingestion of eggs or autoinfection. Seen mostly in children and among family members.
- *Clinical features:* Pruritus ani, nocturnal enuresis. Sometimes, salpingitis, peritonitis, appendicitis, etc. may be seen.
- *Diagnosis:* Detection of eggs by NIH swab and cellophane scotch tape method. Detection of adult worm in finger nails or from stool after enema.
- *Treatment:* Mebendazole, albendazole, or pyrantel pamoate.

REVIEW QUESTIONS

1. List the parasites causing autoinfection and describe briefly the life cycle of *Enterobius vermicularis*.
2. Short notes on:
 - a. Egg of *Enterobius vermicularis*
 - b. Laboratory diagnosis of *Enterobius vermicularis*
 - c. NIH swab

MULTIPLE CHOICE QUESTIONS

1. Most common presenting symptom of thread worm infection amongst the following is
 - a. Abdominal pain
 - b. Rectal prolapse
 - c. Urticaria
 - d. Vaginitis
2. Which one of the following does not pass through the lungs
 - a. Hookworm
 - b. *Ascaris*
 - c. *Strongyloides*
 - d. *Enterobius vermicularis*
3. Infection with which of the following parasites may cause enuresis
 - a. *Ascaris lumbricoides*
 - b. *Enterobius vermicularis*
 - c. *Trichinella spiralis*
 - d. *Wuchereria bancrofti*
4. History of mild intestinal distress, sleeplessness, itching, and anxiety is seen in preschool child attending play school. Possible parasite agent causing these manifestations is
 - a. *Trichomonas vaginalis*
 - b. *Enterobius vermicularis*
 - c. *Ascaris lumbricoides*
 - d. *Necator americanus*
5. The common name for *Enterobius vermicularis* is
 - a. Threadworm
 - b. Pinworm
 - c. Seatworm
 - d. Whip worm
6. Which of the following nematodes lays eggs containing larvae
 - a. *Trichinella spiralis*
 - b. *Enterobius vermicularis*
 - c. *Brugia malayi*
 - d. *Ascaris lumbricoides*

Answer

1. a 2. d 3. b 4. b 5. c 6. b

Ascaris Lumbricoides

■ COMMON NAME

Roundworm.

■ HISTORY AND DISTRIBUTION

Ascaris lumbricoides has been observed and described from very ancient times, when it was sometimes confused with the earthworm.

- Its specific name *lumbricoides* is derived from its resemblance with earthworm (*Lumbricus*, meaning *earthworm* in Latin).
- It is the most common of human helminths and is distributed worldwide. A billion people are estimated to be infected with roundworms. The individual worm burden could be very high, even up to over a thousand. An editorial in the *Lancet* in 1989 observed that if all the roundworms in all the people worldwide were placed end-to-end they would encircle the world 50 times.
- The incidence may be as high as 80–100% in rural areas with poor sanitation.

■ HABITAT

Adult worms live in the **small intestine (85% in jejunum and 15% in ileum)**.

The roundworm, *Ascaris lumbricoides* is the **largest nematode** parasite in the human intestine.

■ MORPHOLOGY

Adult Worm

They are large **cylindrical** worms, with **tapering** ends, the anterior end being more pointed than the posterior (**Fig. 1**).

- They are pale pink or flesh colored when freshly passed in stools, but become white outside the body.
- The mouth at the anterior end has **three** finely toothed lips, one **dorsal** and **two ventrolateral** (**Figs 2A to E**).



Fig. 1: Specimen of *Ascaris lumbricoides*

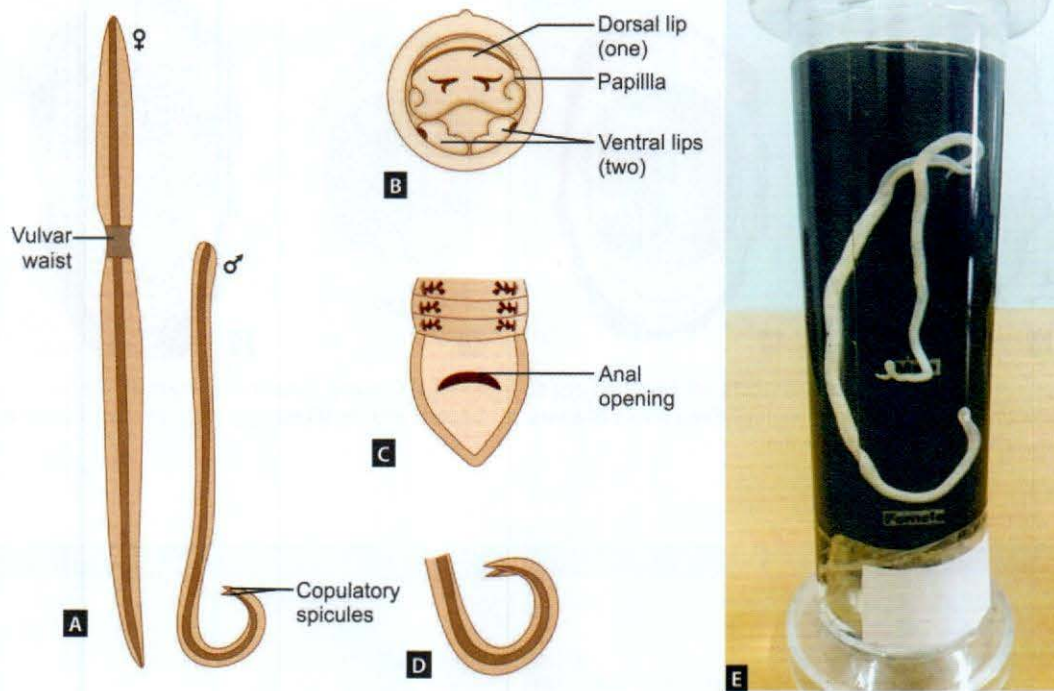
Male Worm

- The adult male worm is little *smaller* than female. It measures 15–30 cm in length and 2–4 mm in thickness (**Figs 2A to E**).
- Its posterior end is curved ventrally to form a *hook* and carries **two copulatory spicules** (**Figs 2A to E**).

Female Worm

The female is *larger* than male, measuring 20–40 cm in length and 3–6 mm in thickness.

- Its posterior extremity is **straight** and **conical**.
- The vulva is situated mid-ventrally, near the junction of the anterior and middle thirds of the body. A **distinct groove** is often seen surrounding the worm at the level of the vulvar opening. This is called the **vulvar waist** or **genital girdle** and is believed to facilitate mating (**Figs 2A to E**). The vulva leads to a single vagina, which branches



Figs 2A to E: *Ascaris lumbricoides*. (A) Adult female and male worms; (B) Anterior end of worm. Head-on view, showing one dorsal and two ventral lips with papillae; (C) Posterior end of female, showing anal opening, a little above the conical tip; (D) Posterior end of male, showing two protruding copulatory spicules(s); and (E) Specimen showing *Ascaris lumbricoides*, male and female

into a pair of genital tubules that lie convoluted through much of the posterior two-thirds of the body. The genital tubules of the gravid worm contain an enormous number of eggs as many as 27 million at a time (**Box 1**).

- A single worm lays up to 200,000 eggs per day. The eggs are passed in feces.

Egg

Two types of eggs are passed by the worms: (1) fertilized and (2) unfertilized.

1. The fertilized eggs, laid by females, inseminated by mating with a male, are embryonated and develop into the infective eggs (**Figs 3A to C**).
2. The unfertilized eggs, are laid by unseminated female. These are nonembryonated and cannot become infective (**Fig. 3D**).

Note: Stool samples may show both fertilized and unfertilized eggs, or either type alone (**Table 1**).

■ LIFE CYCLE

Life cycle of *Ascaris* involves only one host.

Box 1: Parasites with bile-stained eggs

- *Ascaris lumbricoides*
- *Clonorchis sinensis*
- *Trichuris trichiura*
- *Fasciola hepatica*
- *Taenia solium*
- *Fasciolopsis buski*
- *Taenia saginata*.

Natural Host

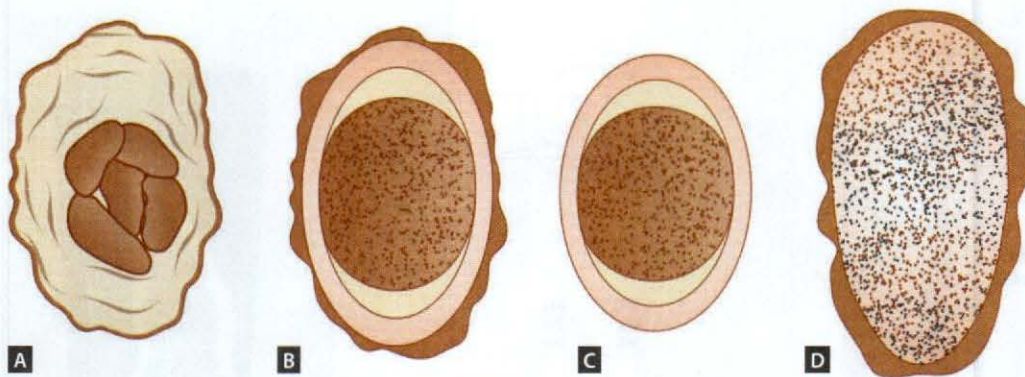
Man. There is no intermediate host.

Infective Form

Embryonated eggs.

- **Mode of transmission:**

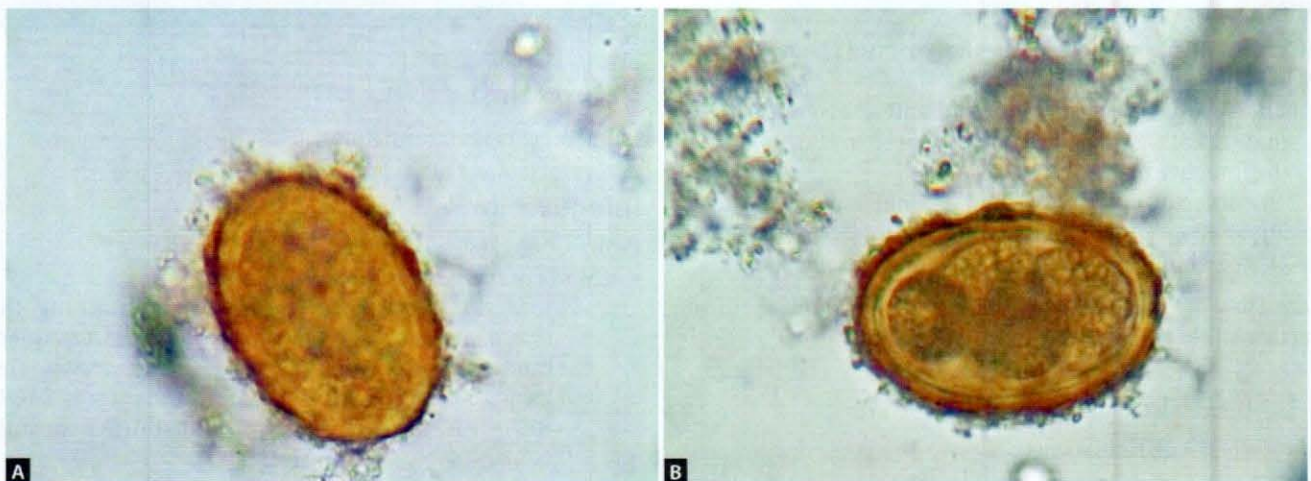
- Infection occurs when the egg containing the infective rhabditiform larva is swallowed. A frequent mode of transmission is through fresh vegetables grown in fields manured with human feces (*night soil*). Infection may also be transmitted through contaminated drinking water.



Figs 3A to D: Types of *Ascaris* eggs found in stools. (A) Fertilized egg surface focus, showing outer mamillary coat; (B) Fertilized egg, median focus, showing unsegmented ovum surrounded by three layers of coats; (C) Decorticated fertilized egg, the mamillary coat is absent; and (D) Unfertilized egg, elongated, with atrophic ovum

Table 1: Features of roundworm egg

Type of egg	Main feature
Unfertilized egg (Fig. 4A)	<ul style="list-style-type: none"> • Elliptical in shape • Narrower and longer • 80 μm \times 55 μm in size • Has a thinner shell with an irregular coating of albumin • Contains a small atrophied ovum with a mass of disorganized highly refractile granules of various size • Does not float in salt solution
Fertilized eggs (Fig. 4B)	<ul style="list-style-type: none"> • Round or oval in shape • Size 60–75 μm \times 40–45 μm • Always bile-stained • Golden brown in color • Surrounded by thick smooth translucent shell with an outer coarsely mammillated albuminous coat, a thick transparent middle layer and the inner lipoidal vitelline membrane • Some eggs are found in feces without the outer mammillated coat. They are called the decorticated eggs (Fig. 3C) • In the middle of the egg is a large unsegmented ovum, containing a mass of coarse lecithin granules. It nearly fills the egg, except for a clear crescentic area at either poles • Floats in saturated solution of common salt



Figs 4A and B: (A) Unfertilized egg of *Ascaris*; and (B) Fertilized egg of *Ascaris*

- Children playing about in mud can transmit eggs to their mouth through dirty fingers (*geophagy*).
- Where soil contamination is heavy due to indiscriminate defecation, the eggs sometimes get airborne along with windswept dust and are inhaled. The inhaled eggs get swallowed.

Development in Soil

The fertilized egg passed in feces is not immediately infective. It has to undergo a period of incubation in soil before acquiring infectivity.

- The eggs are resistant to adverse conditions and can survive for several years.
- The development of the egg in soil depends on the nature of the soil and various environmental factors. A heavy clayey soil and moist shady location, with temperature between 20°C and 30°C are optimal for rapid development of the embryo.
- The development usually takes from 10–40 days, during which time the embryo **moults twice** and becomes the infective rhabditiform larva, coiled up within the egg.

Development in Man

When the swallowed eggs reach the duodenum, the larvae hatch out.

- The **rhabditiform larva**, about 250 µm in length and 14 µm in diameter, are actively motile.
- They penetrate the intestinal mucosa, enter the *portal vessels* and are carried to the *liver*.
- They then pass via the hepatic vein, inferior vena cava, and the right side of the heart and in about **4 days** reach the *lungs*, where they grow and **moult twice**.
- After development in the lungs, in about **10–15 days**, the larvae pierce the lung capillaries and reach the alveoli. They crawl up or are carried up the respiratory passage to the throat and are swallowed.
- The larvae **moult finally** and develop into adults in the upper part of the *small intestine*. They become sexually mature in about **6–12 weeks** and the gravid females start laying eggs to repeat the cycle (**Fig. 5**).
- The adult worm has a lifespan of 12–20 months.

■ PATHOGENICITY AND CLINICAL FEATURES

Disease caused by *A. lumbricoides* is called as *ascariasis*.

- Clinical manifestations in ascariasis can be caused either by the migrating larvae or by the adult worms.

Symptoms Due to the Migrating Larvae

The pathogenic effects of larval migration are due to allergic reaction and not the presence of larvae as such. Therefore,

the initial exposure to larvae is usually asymptomatic, except when the larval load is very heavy.

- When reinfection occurs subsequently, there may be intense cellular reaction to the migrating larvae in the lungs, with infiltration of eosinophils, macrophages and epithelioid cells.
- This ***Ascaris pneumonia*** is characterized by low-grade fever, dry cough, asthmatic wheezing, urticaria, eosinophilia and mottled lung infiltration in the chest radiograph.
- The sputum is often *blood-tinged* and may contain *Charcot-Leyden* crystals. The larvae may occasionally be found in the sputum, but are seen more often in gastric washings. This condition is called ***Loeffler's syndrome***.
- The clinical features generally clear in 1 or 2 weeks, though it may sometimes be severe and rarely, even fatal. Loeffler's syndrome can also be caused by hypersensitivity to other agents, both living and nonliving (**Box 2**).

Symptoms Due to the Adult Worm

Clinical manifestations due to adult worm vary from asymptomatic infection to severe and even fatal consequences.

- ***Asymptomatic infection***: Generally seen in mildly infected cases; however, it is not unusual to find children apparently unaffected in spite of heavy infestation with the worms.
- The pathological effects, when present, are caused by *spoliative action*, *toxic action*, *mechanical effects* and *wandering effects*.
 - ***The spoliative or nutritional effects*** are usually seen when the worm burden is heavy. The worms may be present in enormous numbers, sometimes exceeding 500, in small children, occupying a large part of the intestinal tract. This interferes with proper digestion and absorption of food. Ascariasis may contribute to ***protein-energy malnutrition*** and ***vitamin A deficiency***. Patients have loss of appetite and are often listless. Abnormalities of the jejunal mucosa are often present, including broadening and shortening of villi, elongation of crypts and round cell infiltration of lamina propria. These changes are reversed when the worms are eliminated.
 - ***The toxic effects*** are due to hypersensitivity to the worm antigens and may be manifested as fever, urticaria, angioneurotic edema, wheezing and conjunctivitis. These are more often seen in persons who come into contact with the worm occupationally, as in laboratory technicians and abattoir workers (who become sensitive to the pig ascarid, *A. suum*), than in children having intestinal infestation.
 - ***The mechanical effects*** are the most important manifestations of ascariasis. Mechanical effects can

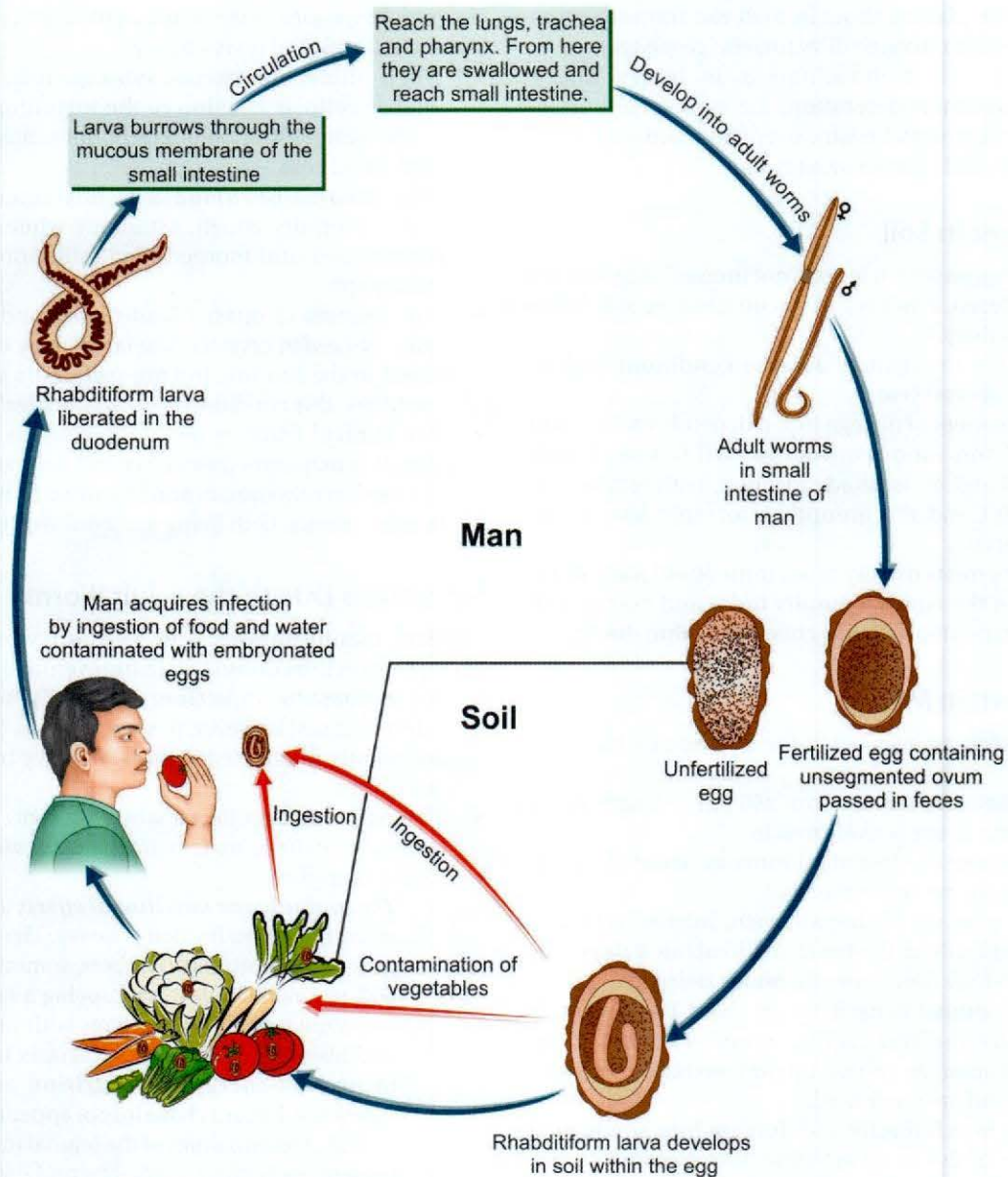


Fig. 5: Life cycle of *Ascaris lumbricoides*

Box 2: Parasites causing pneumonitis or Loeffler's syndrome

- Migrating larvae of:
 - *Ascaris lumbricoides*
 - *Strongyloides stercoralis*
 - *Ancylostoma duodenale*
 - *Necator americanus*
- *Echinococcus granulosus*
- Eggs of *Paragonimus westermani*
- *Cryptosporidium parvum*
- *Trichomonas tenax*
- *Entamoeba histolytica*.

be due to masses of worms causing luminal occlusion or even a single worm infiltrating into a vital area. The adult worms live in the upper part of the small intestine, where they maintain their position due to their body muscle tone, spanning the lumen.

They may stimulate reflex peristalsis, causing recurrent and often severe colicky pain in the abdomen. The worms may be clumped together into a mass, filling the lumen, leading to *volvulus*, *intussusception*, or *intestinal obstruction* and *intestinal perforation*.

- **Ectopic ascariasis (Wanderlust):** The worms are restless wanderers, apparently showing great inquisitiveness, in that they tend to probe and insinuate themselves into any aperture they find on the way. The wandering is enhanced when the host is ill, particularly when febrile, with temperature above 39°C. The male worm is more responsive to illness of the host, than the female. The worm may wander up or down along the gut. Going up, it may enter the opening of the biliary or pancreatic duct causing **acute biliary obstruction** or **pancreatitis**. It may enter the liver parenchyma, where it may lead to liver abscesses. The worm may go up the esophagus and come out through the mouth or nose. It may crawl into the trachea and the lung causing respiratory obstruction or lung abscesses. Migrating downwards, the worm may cause *obstructive appendicitis*. It may lead to peritonitis when it perforates the intestine, generally at weak spots such as typhoid or tuberculous ulcers or through suture lines. This tendency makes preoperative deworming necessary before gastrointestinal surgery in endemic areas. The wandering worm may also reach kidneys.
- Ascarids are prolific egg layers. A single female may account for about three eggs per mg of feces. At this concentration, the eggs can be readily seen by microscopic examination of a saline emulsion of feces. Both fertilized and unfertilized eggs are usually present. Occasionally, only one type is seen. The fertilized eggs may sometimes appear decorticated. The unfertilized eggs are not detectable by salt floatation.
- Rarely when the infestation is light, eggs are demonstrable only by concentration methods.
- Eggs may not be seen if only male worms are present, as may occasionally be the case. Fecal films often contain many artifacts resembling *Ascaris* eggs and care must be taken to differentiate them.
- Eggs may be demonstrative in **the bile** obtained by **duodenal aspirates (Flow chart 1)**.

■ LABORATORY DIAGNOSIS

Detection of Parasite

Adult Worm

The adult worm can occasionally be detected in stool or sputum of patient by naked eye.

- Barium meal may reveal the presence of adult worm in the small intestine.
- A plain abdominal film may reveal masses of worms in gas-filled loops of bowel in patients with intestinal obstruction.
- Pancreaticobiliary worms can be detected by ultrasound (more than 50% sensitive) and endoscopic retrograde cholangiopancreatography (ERCP; 90% sensitive).

Larvae

In the early stages of infection, when migrating larvae cause Loeffler's syndrome, the diagnosis may be made by demonstrating the larvae in *sputum*, or more often in *gastric washings*.

- Presence of Charcot-Leyden crystals in sputum and an attendant eosinophilia supports the diagnosis. At this stage, no eggs are seen in feces.
- **Chest X-ray** may show patchy pulmonary infiltrates.

Eggs

Definitive diagnosis of ascariasis is made by demonstration of eggs in **feces**.

Serological Tests

Ascaris antibody can be detected by:

- Indirect hemagglutination (IHA)
- Indirect fluorescent antibody (IFA)
- Enzyme-linked immunosorbent assay (ELISA).
- Serodiagnosis is helpful in extraintestinal ascariasis like Loeffler's syndrome (**Flow chart 1**).

Blood Examination

Complete blood count may show eosinophilia in early stage of invasion (**Flow chart 1**).

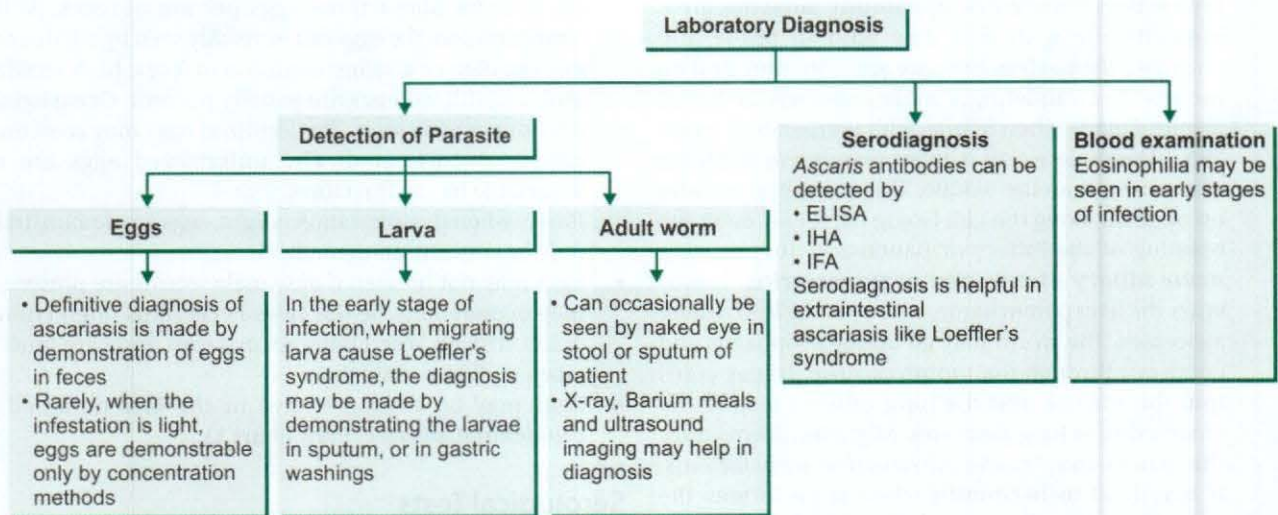
■ TREATMENT

Several safe and effective drugs are now available for treatment of ascariasis. These include pyrantel pamoate (11 mg/kg once; maximum 1 g), albendazole (400 mg once), mebendazole (100 g twice daily for 3 days or 500 mg once), or ivermectin (150–200 mg/kg once). These medications are contraindicated in pregnancy; however, pyrantel pamoate is safe in pregnancy.

- Partial intestinal obstruction should be managed with nasogastric suction, intravenous fluid administration and instillation of piperazine through the nasogastric tube.
- Complete obstruction requires immediate **surgical intervention**.

■ PROPHYLAXIS

- Ascariasis can be eliminated by preventing fecal contamination of soil. The *Ascaris* egg is highly resistant. Therefore, the use of night soil as manure will lead to spread of the infection, unless destruction of the eggs is ensured by proper composting. Treatment of vegetables and other garden crops with water containing iodine 200

Flow chart 1: Laboratory diagnosis of *Ascaris lumbricoides*

Abbreviations: ELISA, enzyme-linked immunosorbent assay; IFA, indirect fluorescent antibody; IHA, indirect hemagglutination

ppm for 15 minutes kills the eggs and larvae of *Ascaris* and other helminths.

- Avoid eating raw vegetables.
- Improvement of personal hygiene.
- Treatment of infected persons especially the children.

KEY POINTS OF *ASCARIS LUMBRICOIDES*

- A. lumbricoides* is the largest nematode infecting human.
- Adult worm is cylindrical resembling an earthworm.
- Male is little smaller than female. Posterior end of male is curved ventrally to form a hook with two copulatory spicules. Posterior end of female is conical and straight.
- Fertilized eggs are bile-stained, round or oval, surrounded by a thin translucent wall with outer mammillated coat containing a large unsegmented ovum. Unfertilized eggs are elliptical, longer with an outer thinner irregular mammillated coat, containing a small atrophied ovum and refractile granules.
- Natural host:** Man.
- Infective form:** Embryonated egg containing rhabditiform larva.
- Clinical features:** Spoliative action—protein and vitamin A deficiency. Toxic action—urticaria and angioneurotic edema. Mechanical action—intestinal obstruction, intussusception, volvulus, intestinal perforation. In lungs—*Ascaris* can cause pneumonia (Loeffler's syndrome).
- Diagnosis:** Demonstration of eggs in stool, finding of larvae in sputum, finding of adult worm in stool or sputum.
- Treatment:** Albendazole, mebendazole, ivermectin, or pyrantel pamoate.



Fig. 6: Adult worms of *Toxocara canis*

OTHER ROUNDWORMS

Toxocara

Toxocara canis and *T. cati*, natural parasites of dogs and cats (Fig. 6), respectively can cause aberrant infection in humans leading to *visceral larva migrans*.

- Infection is acquired in puppies by transmission of larvae transplacentally or lactogenically (through breast milk), but in kittens, only lactogenic transmission is recorded.

Box 3: Geohelminths

- **Soil-transmitted** intestinal nematodes are called *Geohelminths*. In all of them, eggs passed in feces undergo maturation in soil. They are classified into three categories based on their life cycle:
 1. *Direct*: Ingested infective eggs directly develop into adults in the intestine, e.g. whipworms.
 2. *Modified direct*: Larvae from ingested eggs penetrate intestinal mucosa enter bloodstream and through the liver, heart, lungs, bronchus and esophagus, reach the gut to develop into adults, e.g. roundworms.
 3. *Skin penetrating*: Infective larvae in soil penetrate host skin, reach the lung, and proceed to the gut as in the modified direct method, e.g. hookworms.
- Geohelminths pose a serious health problem in poor countries, particularly among children. Their control requires general measures such as personal hygiene, sanitation and health education, besides provision of diagnostic and treatment facilities.

- Older animals are infected by ingestion of mature eggs in soil or of larvae by eating infected rodents, birds, or other paratenic hosts.
- Eggs are shed in feces and become infective in 2–3 weeks.
- Human infection is by ingestion of eggs.
- Larvae hatch out in the small intestine, penetrate the mucosa, and reach the liver, lungs, or other viscera. They do not develop any further.
- Most infections are asymptomatic, but in some, particularly in young children, *visceral larva migrans* develops, characterized by fever, hepatomegaly, cough, pulmonary infiltrates, high eosinophilia and hyperglobulinemia. In some, the eye is affected (*ophthalmic larva migrans*).

Baylisascaris

Baylisascaris procyonis, an ascarid parasite of raccoons in North America, is known to cause serious zoonotic infections leading to visceral larva migrans, ophthalmic larva migrans and **neural larva migrans**. Complications include blindness and central nervous system lesions ranging from minor neuropsychiatric conditions to seizures, coma and death (Box 3).

REVIEW QUESTIONS

1. Name the parasites causing pneumonitis and describe briefly the life cycle and laboratory diagnosis of *Ascaris lumbricoides*.
2. Short notes on:
 - a. Clinical manifestations of ascariasis
 - b. Loeffler's syndrome
 - c. Surgical complications of ascariasis
 - d. Toxocariasis
 - e. Geohelminths
3. Differentiate between fertilized and unfertilized egg of *Ascaris lumbricoides*.

MULTIPLE CHOICE QUESTIONS

1. Which of the following parasites does not penetrate human skin
 - a. *Ascaris lumbricoides*
 - b. *Ancylostoma duodenale*
 - c. *Strongyloides stercoralis*
 - d. *Schistosoma haematobium*
2. The common name for *Ascaris lumbricoides* is
 - a. Roundworm
 - b. Hookworm
 - c. Threadworm
 - d. None of the above
3. The largest intestinal nematode infecting humans is
 - a. *Necator americanus*
 - b. *Ascaris lumbricoides*
 - c. *Enterobius vermicularis*
 - d. None of the above
4. All of the following are correct regarding fertilized egg of *Ascaris* except
 - a. It is always bile-stained
 - b. Covered by an outer mamilliated coat
 - c. Floats in saturated solution of salt
 - d. Does not float in saturated solution of salt
5. All of the following parasites have bile-stained eggs except
 - a. *Ascaris*
 - b. *Clonorchis*
 - c. *Taenia solium*
 - d. *Enterobius*
6. Loeffler's syndrome may be seen in infection with
 - a. *Ancylostoma duodenale*
 - b. *Ascaris lumbricoides*
 - c. *Trichinella spiralis*
 - d. *Trichuris trichiura*

Answer

1. a 2. a 3. b 4. d 5. d 6. b

Filarial Worms

INTRODUCTION

Nematodes belonging to the *superfamily Filarioidea* are *slender thread-like worms* (Latin, *filum* and *thread*), which are transmitted by the bite of blood-sucking insects.

- The filarial worms reside in the subcutaneous tissues, lymphatic system, or body cavities of humans (**Table 1**).
- The adult worm generally measures 80–100 mm in length and 0.25–0.30 mm in breadth; the female worm being longer than the males.
- The tail of the male worm has perianal papillae and unequal spicules but no caudal bursa.
- The female worms are **viviparous** and give birth to larvae known as **microfilariae**.
- The microfilariae released by the female worm, can be detected in the peripheral blood or cutaneous tissues, depending on the species.
- In some species, the microfilariae retain their egg membranes which envelop them as *sheath*. They are known as **sheathed microfilariae**.
- In some other species of filarial nematodes, the egg membrane is ruptured and is known as **unsheathed microfilariae**.
- Once the microfilariae are classified on the basis of sheath as “sheathed” or “unsheathed”, their further differentiation can be done on the characteristic arrangement of nuclei (**Flow chart 1 and Table 2**).
- **Periodicity**: Depending on when the largest number of microfilariae occur in blood, filarial worms can exhibit **nocturnal, diurnal periodicity** or **no periodicity** at all (**Box 1**).

The basis of periodicity is unknown but it may be an adaptation to the biting habits of the vector.

- The life cycle of filarial nematodes is passed in **two hosts**: (1) **definitive host** is man and (2) **intermediate host** are the *blood-sucking arthropods*.
- The microfilariae complete their development in the arthropod host to produce the infective larval stages.

Table 1: Classification of filarial worm based on location in body

Lymphatic filariasis	Subcutaneous filariasis	Serous cavity filariasis
• <i>Wuchereria bancrofti</i>	• <i>Loa loa</i>	• <i>Mansonella perstans</i>
• <i>Brugia malayi</i>	• <i>Onchocerca volvulus</i>	• <i>Mansonella ozzardi</i> (They are virtually nonpathogenic)
• <i>Brugia timori</i>	• <i>Mansonella streptocerca</i>	

These are transmitted to humans by arthropod, which are their vectors also during the next feed. Adult worms live for many years whereas microfilariae survive for 3–36 months.

- **Eight species** of filarial worms infect humans, of them six are pathogenic—(1) ***Wuchereria bancrofti***, (2) ***Brugia malayi*** and (3) ***B. timori*** cause lymphatic filariasis; (4) ***Loa loa*** causes malabar swellings and allergic lesions; (5) ***Onchocerca volvulus*** causes eye lesions and dermatitis; (6) ***Mansonella streptocerca*** leads to skin diseases; and two of them, (7) ***M. ozzardi*** and (8) ***M. perstans*** are virtually nonpathogenic (**Table 3**).
- Infection with any of the filarial worms may be called *filariasis*, but traditionally, the term filariasis refers to lymphatic filariasis caused by *Wuchereria* or *Brugia* species.
- Adult filarial worm contains an endosymbiotic *Rickettsia*-like α -proteobacterium of the genus ***Wolbachia* spp.** This has got definite role in the pathogenesis of filariasis and has become a target for antifilarial chemotherapy.
- *Wolbachia* spp. along with filarial antigen activates the release of proinflammatory and chemotactic cytokines. These include cellular infiltration and amplification of inflammatory processes. Toll-like receptors (TLRs) play an important role in the process.

Box 1: Different types of periodicity exhibited by microfilariae

- *Nocturnal periodicity:* When the largest number of microfilariae occur in blood at night, e.g. *Wuchereria bancrofti*
 - *Diurnal periodicity:* When the largest number of microfilariae occur in blood during day, e.g. *Loa loa*
 - *Nonperiodic:* When the microfilariae circulate at constant levels during the day and night, e.g. *Onchocerca volvulus*
 - *Subperiodic or nocturnally subperiodic:* When the microfilariae can be detected in the blood throughout the day but are detected in higher numbers during the late afternoon or at night.
- Note: The microfilariae are found in capillaries and blood vessels of lungs during the period when they are not present in the peripheral blood.

Table 3: Filarial nematodes infecting humans

Parasite	Location in body adult	Microfilaria	Characteristics of microfilaria	Periodicity of microfilaria	Principal vector
<i>I. Lymphatic filariasis</i>					
<i>Wuchereria bancrofti</i>	Lymphatics	Blood	Sheathed, pointed tail tip free of nuclei	Nocturnal	<i>Culex quinquefasciatus</i>
<i>Brugia malayi</i>	Lymphatics	Blood	Sheathed, blunt tail tip with two terminal nuclei	Nocturnal	<i>Mansonia</i> spp.
<i>Brugia timori</i>	Lymphatics	Blood	Sheathed, longer than <i>Mf. malayi</i>	Nocturnal	<i>Anopheles barbirostris</i>
<i>II. Subcutaneous filariasis</i>					
<i>Loa loa</i>	Connective tissue, conjunctiva	Blood	Sheathed, nuclei extending up to pointed tail tip	Diurnal	<i>Chrysops</i> spp.
<i>Onchocerca volvulus</i>	Subcutaneous nodules	Skin, eyes	Unsheathed, blunt tail tip free of nuclei	Nonperiodic	<i>Simulium</i> spp.
<i>Mansonella streptocerca</i>	Subcutaneous	Skin	Unsheathed blunt tail tip with nuclei	Nonperiodic	<i>Culicoides</i>
<i>III. Serous cavity filariasis</i>					
<i>Mansonella ozzardi</i>	Peritoneum and pleura	Blood	Unsheathed, pointed tail tip without nuclei	Nonperiodic	<i>Culicoides</i>
<i>Mansonella perstans</i>	Peritoneum and pleura	Blood	Unsheathed, pointed tail tip with nuclei	Nonperiodic	<i>Culicoides</i>

■ LYMPHATIC FILARIASIS

Wuchereria Bancrofti

History and Distribution

Filariasis has been known from antiquity. Elephantiasis had been described in India by Sushruta and in Persia by Rhazes and Avicenna.

- **Elephantiasis**—painful, disfiguring swelling of the legs and genital organs—is a classic sign of late-stage disease.
- The term *Malabar leg* was applied to the condition by Clarke in 1709 in Cochin.
- Microfilaria was first observed by **Demarquay** (1863) in the hydrocele fluid of a patient from Havana, Cuba. The genus is named after **Wucherer**, a Brazilian physician who reported microfilariae in chylous urine in 1868.

Microfilaria was first demonstrated in human blood in Calcutta by **Lewis** (1872).

- In 1876, **Bancroft** first reported and described adult female worm and in 1888, adult male worm was described by Bourne.
- Manson (1878) in China identified the *Culex* mosquito as the vector. This was the first discovery of insect transmission of a human disease. Manson (1879) also demonstrated the nocturnal periodicity of microfilariae in peripheral blood.
- *W. bancrofti* is distributed widely in the tropics and subtropics of sub-Saharan Africa, South-East Asia, India and the Pacific islands. The largest number of cases of filariasis occurs in India (**Fig. 1**).
- In India, the endemic areas are mainly along the sea coast and along the banks of the large rivers, though infection occurs virtually in all states, except in the north-west.

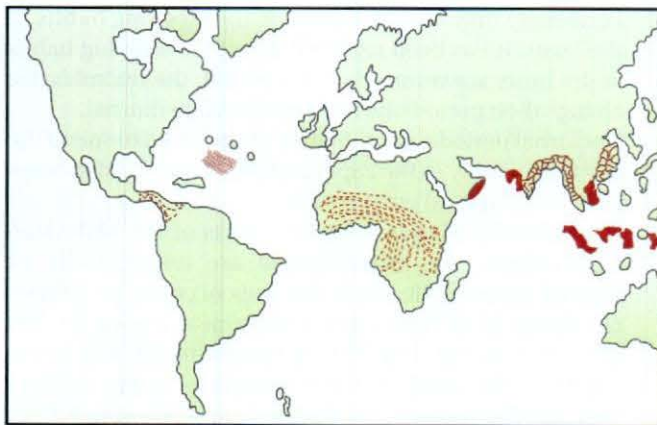


Fig. 1: Geographical distribution of *Wuchereria bancrofti*

Habitat

The adult worms reside in the lymphatic system of man. The microfilariae are found in blood.

Morphology

Adult worm: The adults are whitish, translucent, thread-like worms with smooth cuticle and tapering ends.

- The female is larger (70–100 × 0.25 mm) than the male (25–40 × 0.1 mm).
- The posterior end of the female worm is straight, while that of the male is curved vertically and contains two spicules of unequal length.
- Males and females remain coiled together usually in the abdominal and inguinal lymphatics and in the testicular tissues (Fig. 2).
- The female worm is *viviparous* and directly liberates sheathed microfilariae into lymph.
- The adult worms live for many years, probably 10–15 years or more.

Microfilariae: The microfilaria has a colorless, translucent body with a **blunt head**, and **pointed tail** (Fig. 3).

- It measures 250–300 μm in length and 6–10 μm in thickness. It can move forwards and backwards within the sheath which is much longer than the embryo.
- It is covered by a hyaline sheath, within which it can actively move forwards and backwards as sheath is much longer than the embryo.
- When stained with Leishman or other Romanowsky stains, structural details can be made out. Along the central axis of the microfilaria, a **column of granules** can be seen, which are called **somatic cells or nuclei**. The granules are absent at certain specific locations—a feature which helps in the identification of the species. The specific locations are as following (Fig. 3):

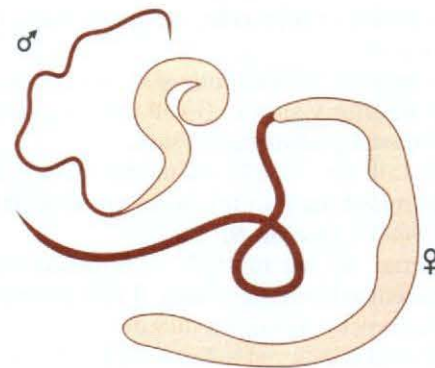


Fig. 2: Adult worm of *Wuchereria bancrofti*

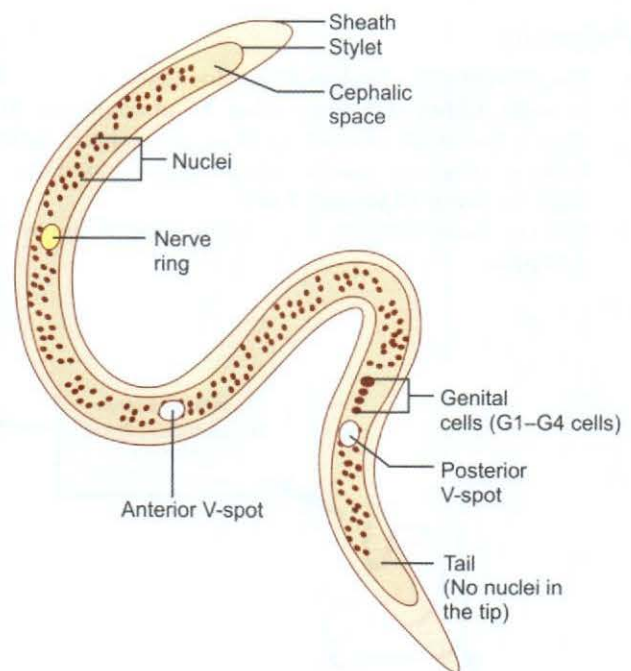


Fig. 3: Morphology of *Microfilaria bancrofti*

- At the head end is a clear space devoid of granules, called the **cephalic space**. In *Microfilaria bancrofti*, the cephalic space is as long as it is broad, while in *Microfilaria malayi*, it is longer than its breadth. With vital stains, a stylet can be demonstrated projecting from the cephalic space (see Fig. 9).
- In the anterior half of the microfilaria, is an oblique area devoid of granules called the **nerve ring**.
- Approximately midway along the length of the microfilaria is the **anterior V-spot**, which represents the **rudimentary excretory system**.
- The **posterior V-spot** (tail spot) represents the cloaca or anal pore.

- The genital cells (**G-cells**) are situated anterior to the *anal pore*.
- The *internal (central) body of Manson* extending from the anterior V-spot to G-cell one, representing the *rudimentary alimentary system*.
- The tail tip, devoid of nuclei in *Mf. bancrofti* (distinguishing feature), bears two distinct nuclei in *Mf. malayi* (see Fig. 9).
- Microfilariae do not multiply or undergo any further development in the human body. If they are not taken up by a female vector mosquito, they die.
- Their lifespan is believed to be about 2-3 months.
- It is estimated that a microfilarial density of at least 15 per drop of blood is necessary for infecting mosquitoes.

Periodicity

- The microfilariae circulate in the bloodstream.
- In India, China and many other Asian countries, they show a nocturnal periodicity in peripheral circulation; being seen in large numbers in peripheral blood only at night (between **10 pm and 4 am**).
- This correlates with the night biting habit of the vector mosquito.

- Periodicity may also be related to the **sleeping habits** of the hosts. It has been reported that if the sleeping habits of the hosts are reversed over a period, the microfilariae change their periodicity from nocturnal to diurnal.
- Nocturnal periodic microfilariae are believed to spend the day time mainly in the capillaries of the lung and kidneys or in the heart and great vessels.
- In the Pacific islands and some parts of the Malaysian archipelago, the microfilariae are nonperiodic or diurnal subperiodic, such that they occur in peripheral circulation at all times, with a slight peak during the late afternoon or evening. This is related to the day-biting habits of the local vector mosquitoes (some authors separate the subperiodic Pacific type of *W. bancrofti* as a distinct species designated *W. pacifica*, but this is not widely accepted).

Life Cycle

Wuchereria bancrofti passes its life cycle in two hosts (**Fig. 4**):

1. **Definitive host:** Man. No animal host or reservoir is known for *W. bancrofti*.
2. **Intermediate host:** Female mosquito, of different species acts as vectors in different geographic areas. The major

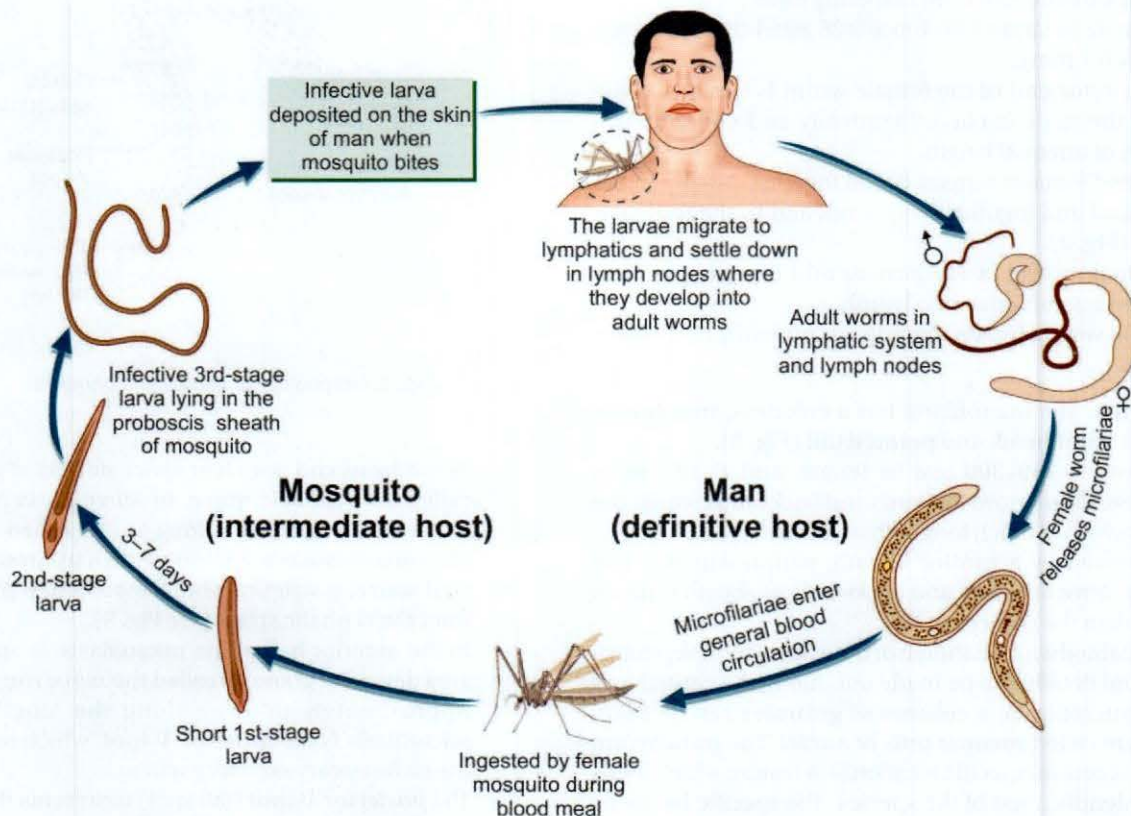


Fig. 4: Life cycle of *Wuchereria bancrofti*

Box 2: Parasites with mosquito as intermediate host

- *Wuchereria bancrofti*
- *Brugia* spp.
- *Mansonella* spp.
- *Dirofilaria* spp.

vector in India and most other parts of Asia is *Culex quinquefasciatus* (*C. fatigans*) (**Box 2**).

Infective form: Actively motile third-stage filariform larva is infective to man.

Mode of transmission: Humans get infection by bite of mosquito carrying filariform larva.

Development in mosquito: When a vector mosquito feeds on a carrier, the microfilariae are taken in with the blood meal and reach the stomach of the mosquito.

- Within 2–6 hours, they cast off their sheaths (*exsheathing*), penetrate the stomach wall and within 4–17 hours migrate to the thoracic muscles where they undergo further development.
- During the next 2 days, they metamorphose into the **first-stage larva**, which is a *sausage-shaped* with a *spiky tail*, measuring 125–250 × 10–15 μm (**Fig. 4**).
- Within a week, it moults once or twice, increases in size and becomes the **second-stage larva**, measuring 225–325 × 15–30 μm (**Fig. 4**).
- In another week, it develops its internal structures and becomes the elongated **third-stage filariform larva**, measuring 1,500–2,000 × 15–25 μm. It is actively motile and is the **infective form** (**Fig. 4**).
- It enters the *proboscis sheath* of the mosquito, awaiting opportunity for infecting humans on whom the mosquito feeds.
- There is no multiplication of the microfilaria in the mosquito and one microfilaria develops into one infective larva only.
- The time taken from the entry of the microfilaria into the mosquito till the development of the infective third-stage larva located in its proboscis sheath, constitutes the **extrinsic incubation period**. Its duration varies with environmental factors such as temperature and humidity, as well as with the vector species. Under optimal conditions, its duration is **10–20 days**.
- When a mosquito with infective larvae in its proboscis feeds on a person, the larvae get deposited, usually in pairs, on the skin near the puncture site.

Development in man: The larvae enter through the puncture wound or penetrate the skin by themselves.

- The infective dose for man is not known, but many larvae fail to penetrate the skin by themselves and many more are destroyed in the tissues by immunological and other

Table 4: Differences between classical and occult filariasis

	<i>Classical filariasis</i>	<i>Occult filariasis</i>
Cause	Due to adult and developing worms	Hypersensitivity to microfilarial antigen
Basic lesion	Lymphangitis, lymphadenitis	Eosinophilic granuloma formation
Organs involved	Lymphatic vessels and lymph node	Lymphatic system, lung, liver, spleen, joints
Microfilaria	Present in blood	Present in tissues but not in blood
Serological test	Complement fixation test not so sensitive	Complement fixation test highly sensitive
Therapeutic response	No response	Prompt response to diethylcarbamazine (DEC)

defense mechanisms. A very large number of infected mosquito bites are required to ensure transmission to man, perhaps as many as 15,000 infective bites per person.

- After penetrating the skin, the third-stage larvae enter the lymphatic vessels and are carried usually to abdominal or inguinal lymph nodes, where they develop into adult forms (**Fig. 4**).
- There is **no multiplication** at this stage and only one adult develops from one larva, male or female.
- They become sexually mature in about 6 months and mate.
- The gravid female worm releases large numbers of microfilariae, as many as 50,000 per day. They pass through the thoracic duct and pulmonary capillaries to enter the peripheral circulation.
- The microfilariae are ingested with the blood meal by mosquito and the cycle is repeated.

Prepatent period: The period from the entry of the infective third-stage larvae into the human host till the first appearance of microfilariae in circulation is called the *biological incubation period* or the *prepatent period*. This is usually about **8–12 months**.

Clinical incubation period: The period from the entry of the infective larvae, till the development of the earliest clinical manifestation is called the *clinical incubation period*. This is very variable, but is usually **8–16 months**, though it may often be much longer.

Pathogenesis

Infection caused by *W. bancrofti* is termed as *wuchereriosis* or *bancroftian filariasis*.

The disease can present as (**Table 4**):

- **Classical filariasis**
- **Occult filariasis**.

Classical filariasis:**Pathogenesis:**

- It occurs due to blockage of lymph vessels and lymph nodes by the adult worms. The blockage could be due to **mechanical factors** or **allergic inflammatory reaction** to worm antigens and secretions. The affected lymph nodes and vessels are infiltrated with macrophages, eosinophils, lymphocytes and plasma cells. The vessel walls get thickened and the lumen narrowed or occluded, leading to lymph stasis and dilatation of lymph vessels. The worms inside lymph nodes and vessels may cause **granuloma formation**, with subsequent scarring and even calcification. Inflammatory changes damage the valves in lymph vessels, further aggravating lymph stasis. Increased permeability of lymph vessel walls lead to leakage of protein-rich lymph into the tissues. This produces the typical hard pitting or **brawny edema** of filariasis. Fibroblasts invade the edematous tissues, laying down fibrous tissue, producing the nonpitting gross edema of elephantiasis. Recurrent secondary bacterial infections cause further damage.
- Animal models have been developed, such as experimental filarial infection in cats with *Brugia pahangi* or *Br. malayi*. These have helped in understanding the pathogenesis of the disease, but in cats and other animals, filarial infection does not cause elephantiasis. Elephantiasis is a feature unique to human filariasis, apparently caused by human erect posture and consequent hydrodynamic factors affecting lymph flow.

Clinical manifestations: The most common presentations of lymphatic filariasis are asymptomatic (subclinical) microfilaremia, acute adenolymphangitis (ADL) and chronic lymphatic disease.

- Most of the patients appear clinically asymptomatic but virtually all of them have subclinical disease including microscopic hematuria or proteinuria, dilated lymphatics (visualized by imaging) and in men with *W. bancrofti* infection, scrotal lymphangiectasia (detected by ultrasound).
- **Acute adenolymphangitis** is characterized by high fever, lymphatic inflammation (lymphangitis and lymphadenitis) and transient local edema.
 - **Fever** is of high grade, sudden in onset, associated with rigors and last for 2 or 3 days.
 - **Lymphangitis** is inflamed lymph vessels seen as red streaks underneath the skin. Lymphatics of the testes and spermatic cord are frequently involved, with epididymo-orchitis and funiculitis. Acute lymphangitis is usually caused by allergic or inflammatory reaction to filarial infection, but may often be associated with streptococcal infection also.

- **Lymphadenitis:** Inflammation of lymph nodes. Most common affected lymph nodes being inguinal nodes followed by axillary nodes. The lymph nodes become enlarged, painful and tender.
- **Lymphedema:** This follows successive attacks of lymphangitis and usually starts as swelling around the ankle, spreading to the back of the foot and leg. It may also affect the arms, breast, scrotum, vulva, or any other part of body. Initially, the edema is pitting in nature, but in course of time, becomes hard and nonpitting.
- **Lymphangiovarix:** Dilatation of lymph vessels commonly occurs in the inguinal, scrotal, testicular and abdominal sites.
- The lymphangitis and lymphadenitis can involve both the upper and lower extremities in both bancroftian and brugian filariasis but involvement of genital lymphatics occurs exclusively with *W. bancrofti* infection. The genital involvement can be in the form of funiculitis, epididymitis and hydrocele formation.
- **Hydrocele:** This is a very common manifestation of filariasis. Accumulation of fluid occurs due to obstruction of lymph vessels of the spermatic cord and also by exudation from the inflamed testes and epididymis. The fluid is usually clear and straw colored but may sometimes be cloudy, milky, or hemorrhagic. The hydrocele may be unilateral or bilateral and is generally small in size in the early stage, but may occasionally assume enormous proportions in association with elephantiasis of the scrotum. The largest reported hydrocele weighed over 100 kilograms.
- **Lymphorrhagia:** Rupture of lymph varices leading to release of lymph or chyle and resulting in **chyluria** (Fig. 5), chylous diarrhea, chylous ascites and chylothorax, depending on the involved site.
- **Elephantiasis:** This is a delayed sequel to repeated lymphangitis, obstruction and lymphedema. Repeated leakage of lymph into tissues first results in lymphedema, then to elephantiasis, in which there is nonpitting brawny edema with growth of new adventitious tissue and thickened skin, cracks, and fissures with secondary bacterial and fungal infections, commonly seen in leg but may also involve other parts of body (Fig. 6).

Clinical features of filariasis

- Asymptomatic microfilaremia, acute adenolymphangitis, lymphadenitis
- Lymphedema, lymphangiovarix, chronic funiculitis, epididymitis, hydrocele, elephantiasis, chylothorax, chyluria

Occult filariasis:

- It occurs as a result of hypersensitivity reaction to microfilarial antigens, not directly due to lymphatic involvement.



Fig. 5: Chylous urine

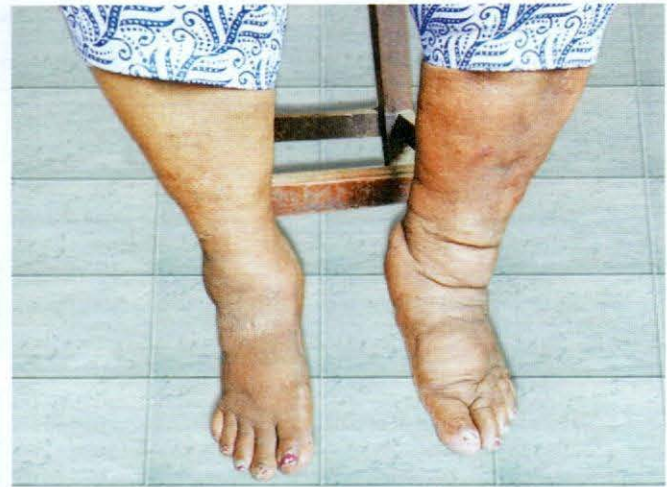

Fig. 6: Elephantiasis of the legs

- Microfilariae are not found in blood, as they are destroyed by the allergic inflammation in the tissues.
- **Clinical manifestations:**
 - Massive eosinophilia (30–80%)
 - Hepatosplenomegaly
 - Pulmonary symptoms like dry nocturnal cough, dyspnea and asthmatic wheezing.
 - Occult filariasis has also been reported to cause arthritis, glomerulonephritis, thrombophlebitis, tenosynovitis, etc.
 - Classical features of lymphatic filariasis are absent.
- **Meyers Kouwenaar syndrome** is a synonym for occult filariasis.
- **Tropical pulmonary eosinophilia:**
 - This is a manifestation of occult filariasis which presents with low-grade fever, loss of weight, and pulmonary symptoms such as dry nocturnal cough, dyspnea and asthmatic wheezing.
 - Children and young adults are more commonly affected in areas of endemic filariasis including the Indian subcontinent.
 - There is a marked increase in **eosinophil count** (>3000 μm which may go up to 50,000 or more).
 - Chest X-ray shows **mottled shadows** similar to miliary tuberculosis.
 - It is associated with a high level of **serum immunoglobulin E (IgE)** and filarial antibodies.
 - Serological tests with filarial antigen are usually strongly positive.
 - The condition responds to treatment with diethylcarbamazine (DEC), which acts on microfilariae.

Laboratory Diagnosis

The diagnosis of filariasis depends on the clinical features, history of exposure in endemic areas and on laboratory findings.

The laboratory tests that can be used for diagnosis has been described in **Flow chart 2**.

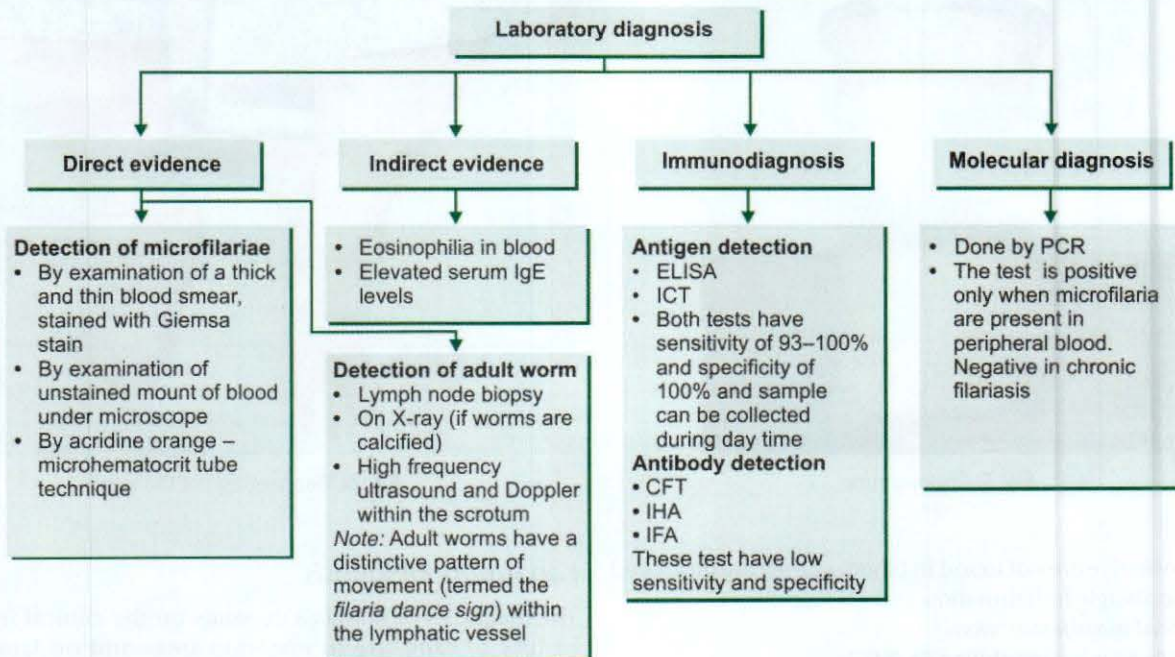
Demonstration of microfilaria:

- Microfilaria can be demonstrated in blood, chylous urine (**Fig. 6**) exudate of lymph varix and hydrocele fluid. Peripheral blood is the specimen of choice.
- The method has the advantage that the species of the infecting filaria can be identified from the morphology of the microfilaria seen. It is also the method used for carrier surveys.
- In India and other areas, where the prevalent filarial species is nocturnally periodic, it is best to collect “**night blood**” samples between 10 pm and 4 am.
- Microfilaria can be demonstrated in unstained as well as stained preparations and in thick as well as thin smears (**Fig. 7**).

Unstained film:

- Examination under the low power microscope shows the actively motile microfilariae lashing the blood cells around.
- The timing of blood collection is critical and should be based on the periodicity of the microfilariae.
- The examination may be conveniently made the next morning as microfilariae retain their viability and motility for a day or 2 at room temperature.

Stained film: A “thick and thin” blood smear is prepared on a clean glass slide and dried.

Flow chart 2: Laboratory diagnosis of *Wuchereria bancrofti*

Abbreviations: CFT, complement fixation test; ELISA, enzyme-linked immunosorbent assay; ICT, immunochromatographic test; IFA, indirect fluorescent antibody; IgE, immunoglobulin E; IHA, indirect hemagglutination; PCR, polymerase chain reaction

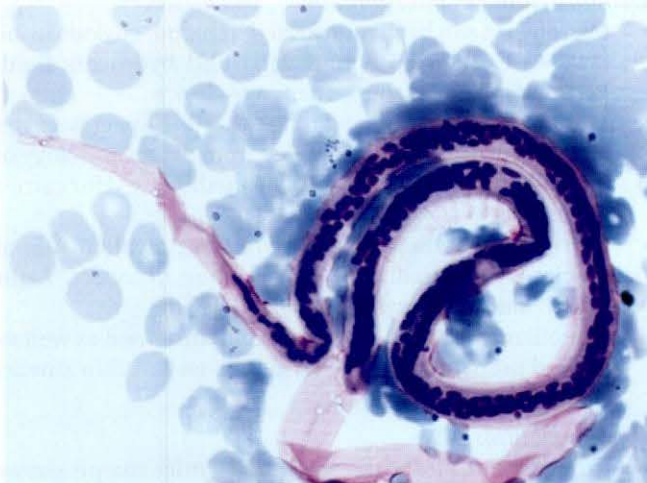


Fig. 7: Microfilaria in blood film

Source: Mohan H. Textbook of Pathology, 6th edition. New Delhi: Jaypee Brothers Medical Publishers; 2010. p. 190.

- The thick part of the smear is dehemoglobinized by applying distilled water. The smear is fixed in methanol and stained with Giemsa, Leishman, or polychrome methylene blue stains. Microfilariae may be seen under the low power microscope in the thick film.

- The morphology of microfilariae can be studied in thin film. The microfilaria of *W. bancrofti* are **sheathed** and appear as **smooth curves** in stained smear and are 298 μm long and 7.5–10 μm in diameter (Fig. 7).
- By using a micropipette for taking a known quantity of blood (20–60 mm^3) for preparing the smear and counting the number of microfilariae in the entire stained smear, microfilaria counts can be obtained.

Concentration techniques: When the microfilaria density is low, concentration techniques are used:

- Knott's concentration technique:** Anticoagulated blood (1 mL) is placed in 9 mL of 2% formalin and centrifuged $500 \times g$ for 1 minute. The sediment is spread on a slide to dry thoroughly. The slide is stained with Wright or Giemsa stain and examined microscopically for microfilariae.
- Nucleopore filtration:** In the filtration methods used at present, larger volumes of blood, up to 5 mL, can be filtered through millipore or nucleopore membranes (3 μm diameter). The membranes may be examined as such or after staining, for microfilariae. The filter membrane technique is much more sensitive, so that blood can be collected even during day time for screening. The disadvantages of the technique are the cost and the need for venipuncture.
- Diethylcarbamazine provocation test:** A small dose of DEC (2 mg per kg body weight) induces microfilariae to

Box 3: Parasites found in urine

- *Wuchereria bancrofti*
- *Schistosoma hematobium*
- *Trichomonas vaginalis*.

appear in peripheral blood even during day time. For surveys, blood samples can be collected 20–50 minutes after the administration of one 100 mg tablet of DEC to adults.

- **Other specimens:** Microfilaria may be demonstrated in centrifuged deposits of lymph, hydrocele fluid, chylous urine or other appropriate specimens. Usually 10–20 mL of the first early morning urine is collected for examination and demonstration (**Box 3**).

Biopsy: Adult filarial worms can be seen in sections of biopsied lymph nodes, but this is not employed in routine diagnosis.

Skin test: Intradermal injection of filarial antigens (extracts of microfilariae, adult worms and third-stage larvae of *B. malayi* or of the dog filaria *Dirofilaria immitis*) induce an immediate hypersensitivity reaction. But, the diagnostic value of the skin test is very limited due to the high rate of false-positive and negative reactions.

Imaging techniques:

Ultrasonography: High frequency ultrasonography (USG) of scrotum and female breast coupled with Doppler imaging may result in identification of motile adult worm (filaria dance sign) within the dilated lymphatics.

- Adult worm may be visualized in the lymphatics of the spermatic cord in up to 80% of the infected men with microfilaria associated with *W. bancrofti*.

Radiology:

- Dead and calcified worms can be detected occasionally by X-ray.
- In tropical pulmonary eosinophilia (TPE), chest X-ray shows mottled appearance resembling miliary tuberculosis.
- Intravenous urography, retrograde pyelography, lymphangiography and lymphoscintigraphy may be used to demonstrate abnormal lymphatic urinary fistula.

Serodiagnosis:

Demonstration of antibody: Several serological tests, including complement fixation, indirect hemagglutination (IHA), indirect fluorescent antibody (IFA), immunodiffusion and immunoenzyme tests have been described.

- Indirect immunofluorescence and enzyme-linked immunosorbent assay (ELISA) detect antibodies in over 95% of active cases and 70% of established elephantiasis.

Disadvantages: Antibody detection test cannot differentiate between current and past infections.

Demonstration of circulating antigen: Highly sensitive and specific test for detection of specific circulating filarial antigen (CFA) have been developed for detection of recent bancroftian filariasis.

- The **Trop-bio test** is a semiquantitative sandwich ELISA for detection of CFA in serum or plasma specimen.
- **Immunochromatographic test (ICT)** is a new and rapid filarial antigen test that detects soluble *W. bancrofti* antigens using **monoclonal antibody (ADI2)** in the serum of infected humans.
- Both assay have sensitivities of 93–100% and specificities approaching 100%.
- Specific IgG4 antibody against *W. bancrofti* antigen **WbSXP-1** have been used to develop ELISA for detecting circulating filarial antigen in sera of patients with filariasis.
- There is however, extensive cross-reactivity between filarial antigens and antigens of other helminths, including intestinal roundworm, thus interpretation of serological findings can be difficult.

Advantages: Antigen detection tests are more sensitive than microscopy and can differentiate between current and past infections.

Molecular diagnostic technique: Polymerase chain reaction (PCR) can detect filarial deoxyribonucleic acid (DNA) from patient's blood, only when circulating microfilaria are present in peripheral blood but not in chronic carrier state.

- Usually the test provides sensitivities that are up to tenfold greater than parasitic detection by direct examination and is 100% specific.

Indirect evidences: Eosinophilia (5–15%) is a common finding in filariasis. Elevated **serum IgE** levels can also be seen.

Treatment

Diethylcarbamazine is the drug of choice. It is given orally in a dose of 6 mg/kg body weight daily for a period of 12 days amounting to a total of 72 mg of DEC per kg of body weight. It has both macro and microfilaricidal properties. Following treatment with DEC severe allergic reaction (Mazzotti reaction) may occur due to death of microfilariae. It kills both microfilaria and adult worm.

Antihistamines or corticosteroids may require to control the allergic phenomenon.

The administration of DEC can be carried out in three ways:

1. **Mass therapy:** In this approach, DEC is given to almost everyone in community irrespective of whether they have microfilaria disease manifestation or no signs of infection except those under 2 years of age, pregnant women and seriously-ill patients. The dose recommended is 6 mg/kg body weight. In some countries it is used alone and in some, with albendazole or ivermectin. Mass therapy is indicated in highly endemic areas.

2. **Selective treatment:** Diethylcarbamazine is given only to those who are microfilaria-positive. In India, the current strategy is based on detection and treatment of human carriers and filarial cases. The recommended dose in the Indian program is DEC 6 mg/kg of body weight daily for 12 doses, to be completed in 2 weeks. In endemic areas, treatment must be repeated every 2 years.
3. **Diethylcarbamazine medicated salts:** Common salt medicated with 1–4 gram of DEC per kg has been used for filariasis control in Lakshadweep island, after an initial reduction in prevalence had been achieved by mass or selective treatment of microfilaria carriers.

Ivermectin: In doses of 200 µg/kg can kill the microfilariae but has no effect on adults. It is not used in India. It is used in regions of Africa.

Tetracyclines or doxycycline for 4–8 weeks also have an effect in the treatment of filariasis by inhibiting endosymbiotic bacteria (*Wolbachia species*) that are essential for the fertility of the worm.

Supportive treatment:

- Chronic condition may not be curable by antifilarial drugs and require other measures like elevation of the affected limb, use of elastic bandage and local foot care reduce some of the symptoms of elephantiasis.
- **Surgery** is required for hydrocele.
- Medical management of chyluria includes bed rest, high protein diet with exclusion of fat, drug therapy with DEC and use of abdominal binders.
- Surgical management of refractory case includes endoscopic sclerotherapy using silver nitrate.

Prophylaxis

The two major measures in prevention and control of filariasis are:

1. Eradication of the vector mosquito.
2. Detection and treatment of carriers.

Eradication of vector mosquito:

- **Antilarval measures:** The ideal method of vector control would be elimination of breeding places by providing adequate sanitation and underground waste water disposal system. However, this involves a lot of expenditure, hence current approach in India is to restrict the antilarval measures to urban areas by:
 - **Chemical control:** Using antilarval chemicals like:
 - ♦ Mosquito larvicidal oil
 - ♦ Pyrosene oil-E
 - ♦ Organophosphorous larvicides like temephos, fenthion, etc.
 - **Removal of Pistia plant:** Mainly restricted to control of *Mansonia* mosquitoes leading to brugian filariasis.

- **Antiadult measures:** Adult mosquitoes can be restricted by use of dichlorodiphenyltrichloroethane (DDT), dieldrin and pyrethrum. However, vector mosquitoes of filariasis have become resistant to DDT and dieldrin. Pyrethrum, as a space spray, is still being used.
- **Personal prophylaxis:** Using mosquito nets and mosquito repellants is the best method.

KEY POINTS OF WUCHERERIA BANCROFTI

- Adult worm is white, thread-like with smooth cuticle and tapering end.
- The female worm is viviparous. The embryo (microfilaria) is colorless, sheathed, with tail-tip free of nuclei and actively motile.
- Microfilaria in blood shows nocturnal periodicity (10 pm to 4 am).
- **Definitive host:** Man.
- **Intermediate host:** *Culex quinquefasciatus* (*C. fatigans*).
- Microfilaria do not multiply in man. When taken up by vector mosquito, it undergoes stages of development and become third-stage filariform larva which is the *infective form*.
- **Pathogenesis:** Adult worm causes mechanical blockage of lymphatic system and allergic manifestations.
- **Clinical features:** Early stage—fever, malaise, urticaria, fugitive swelling, lymphangitis. Chronic stage—lymphadenitis, lymphangiomas, chyluria, hydrocele and elephantiasis. Tropical pulmonary eosinophilia occurs due to hypersensitivity reaction to filarial antigen.
- **Diagnosis:** Demonstration of microfilaria in peripheral blood or chylous urine. Demonstration of adult worm in biopsy, Doppler USG and X-ray. Demonstration of filarial antigen and antibody.
- **Treatment:** Drug of choice is DEC and ivermectin. Supportive and surgical management in some cases.
 - **Detection and treatment of carriers:** The recommended treatment is DEC 6 mg per kg body weight daily for 12 days, the drug being given for 2 weeks, 6 days in a week.

Brugia Malayi

History and Distribution

- The genus *Brugia* was named after **Brug**, who in 1927 described a new type of microfilaria in the blood of natives in Sumatra.
- The adult worm of *B. malayi* was described by Rao and Maplestone in India (1940).
- Besides *B. malayi*, the genus includes *B. timori*, which parasitizes humans in Timor, Indonesia and a number of animal species, such as *B. pahangi* and *B. patei* infecting dogs and cats.
- The geographical distribution of *B. malayi* is much more restricted than that of *W. bancrofti*. It occurs in India and Far-East, Indonesia, Philippines, Malaysia, Thailand, Vietnam, China, South Korea and Japan.

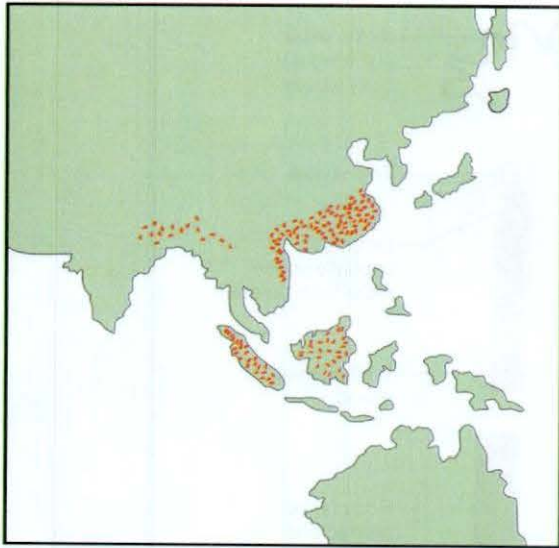


Fig. 8: Geographical distribution of *Brugia malayi*

- In India, Kerala is the largest endemic area, particularly the districts of Quilon, Alleppey, Kottayam, Ernakulam and Trichur. Endemic pockets occur in Assam, Orissa, Madhya Pradesh and West Bengal. *B. malayi* and *W. bancrofti* may be present together in the same endemic area, as in Kerala. In such places, *B. malayi* tends to be predominantly rural and *W. bancrofti* urban in distribution (Fig. 8).

Morphology

Adult worms:

- The adult worms of *B. malayi* are generally similar to those of *W. bancrofti*, though smaller in size.

Microfilariae: The microfilariae of *B. malayi*, although sheathed are different in a number of respects from *Microfilaria bancrofti*.

- Mf. malayi* is smaller in size, shows **kinks** and **secondary curves**, its cephalic space is **longer**, carries double stylets at the anterior end, the nuclear column appears blurred in Giemsa-stained films and the tail tip carries **two distinct nuclei**, one terminal and the other subterminal (Fig. 9 and Table 5).

Life Cycle

The life cycle of *B. malayi* is similar to that of *W. bancrofti*; however, the intermediate host of *Brugia* are vectors of genera *Mansonia*, *Anopheles* and *Aedes*. In India, main vectors are *Mansonia annulifera* and *M. uniformis*.

- Pathogenicity, clinical features, laboratory diagnosis and treatment are similar to *W. bancrofti*.

Table 5: Distinguishing features of *Mf. bancrofti* and *Mf. malayi*

Features	<i>Mf. bancrofti</i>	<i>Mf. malayi</i>
Length	250–300 µm	175–230 µm
Appearance	Graceful, sweeping curves	Kinky, with secondary curves
Cephalic space	Length and breadth equal	Almost twice as long as broad
Stylet at anterior end	Single	Double
Excretory pore	Not prominent	Prominent
Nuclear column	Discrete nuclei	Blurred
Tail tip	Pointed, free of nuclei	Two distinct nuclei, are at tip, the other subterminal
Sheath	Faintly-stained	Well-stained

- Prevention:** The breeding of *Mansonia* mosquito is associated with certain plants such as *Pistia*. In absence of these plants, mosquito cannot breed. Thus in countries like Sri Lanka and India where *M. annulifera* is the chief vector of *B. malayi*, the transmission of the parasite can be effectively reduced by removal of these plants in addition to the antilarval, antiadult and self prophylaxis methods described in *W. bancrofti*.

Brugia Timori

Brugia timori is limited to Timor and some other islands of Eastern Indonesia.

- The vector of *B. timori* is *Anopheles barbirostris*, which breeds in rice fields and is a night feeder.
- Definitive host:** Man. No animal reservoir is known.
- The microfilaria is larger than *Mf. malayi*. The sheath of *Mf. timori* fails to take Giemsa stain with 5–8 nuclei present in the tail.
- The lesions produced by *B. timori* are milder than those of bancroftian or malayan filariasis. A characteristic lesion is the development of draining abscesses caused by worms in lymph nodes and vessels along the saphenous vein, leading to scarring.

■ SUBCUTANEOUS FILARIASIS

Loa Loa

Common Name

African eyeworm.

History and Distribution

Loa loa, causing loiasis, “fugitive swellings” or “Calabar swellings”, was first detected in the eye of a patient in West

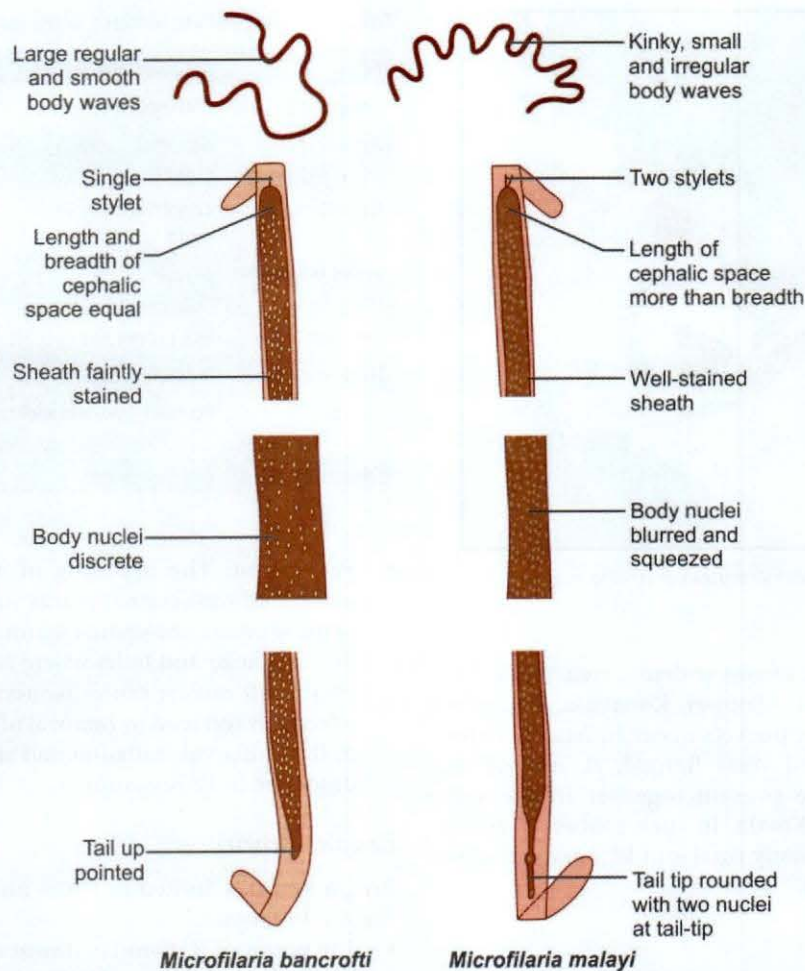


Fig. 9: Schematic diagram showing distinguishing features of *Microfilaria bancrofti* and *Microfilaria malayi*

Indies in 1770. But at present, it is limited to its primary endemic areas in the forests of West and Central Africa, where about 10 million people are affected.

Morphology

Adult worm: The adult worm is thin and transparent, measuring about 30–70 mm in length and 0.3–0.5 mm in thickness.

- In infected persons, they live in the subcutaneous tissues, through which they wander. They may also occur in the subconjunctival tissue.
- Adults live for 4–17 years.

Microfilaria: The microfilariae are **sheathed** with column of nuclei extending completely to the tip of the tail.

- They appear in peripheral circulation only during the day from 12 noon to 2 pm (**diurnal periodicity**).

Life Cycle

Life cycle is completed in two hosts:

1. **Definitive host:** Man
2. **Intermediate host or vectors:** Day-biting flies (mango flies) of the genus *Chrysops*, (*C. dimidiata*, *C. silacea* and other species) in which the microfilariae develop into the **infective third-stage larvae**.
 - Infection is transmitted to man through the bite of infected *Chrysops* during their blood meal.
 - The infective third-stage larvae enter the subcutaneous tissue, moult, and develop into mature adult worm over 6–12 months and migrate in subcutaneous tissues.
 - Female worms produce sheathed microfilaria which have diurnal periodicity.
 - The microfilaria is ingested by *Chrysops* during its blood meal.

- They cast off their sheaths, penetrate the stomach wall and reach thoracic muscles where they develop into infective larvae.
- Development in *Chrysops* is completed in about 10 days.

Pathogenicity and Clinical Features

The pathogenesis of *loiasis* depends on the migratory habit of the adult worm.

- Their wanderings through subcutaneous tissues set up temporary foci of inflammation, which appear as swellings, of up to 3 cm in size, usually seen on the extremities. These are the *Calabar swellings* or *fugitive swellings*, because they disappear in a few days, only to reappear elsewhere.
- **Ocular manifestations** occur when the worm reaches the subconjunctival tissues during its wanderings. The *ocular lesions* include *granulomata* in the bulbar conjunctiva, *painless edema* of the eyelids and *proptosis*.
- Complications like nephropathy, encephalopathy and cardiomyopathy can occur but are rare.

Laboratory Diagnosis

Diagnosis rests on the appearance of fugitive swelling in persons exposed to infection in endemic area.

- Definitive diagnosis requires the detection of microfilaria in peripheral blood or the isolation of the adult worm from the eye.
- Microfilariae may be shown in peripheral blood collected during the day.
- The adult worm can be demonstrated by removal from the skin or conjunctiva or from a subcutaneous biopsy specimen from a site of swelling.
- High eosinophil count is common.

Treatment

Diethylcarbamazine (8–10 mg/kg per day for 21 days) is effective against both the adult and the microfilarial forms of *L. loa*, but requires multiple courses. It has to be used with caution as severe adverse reactions may develop following the sudden death of large numbers of microfilariae.

- Simultaneous administration of corticosteroids minimizes such reaction.
- Ivermectin or albendazole although not approved by Food and Drug Administration (FDA) for this purpose, is effective in reducing microfilarial loads. Ivermectin is contraindicated in patients with heavy microfilaremia (>5,000 microfilaria/mL).
- Treatment by surgical removal of the adult worms is rarely done.

KEY POINTS OF LOA LOA

- *Loa loa* is also known as African eyeworm and causes loiasis.
- Vectors: Day-biting flies (*Chrysops*).
- Microfilaria is sheathed and nuclei extend up to tail tip.
- Microfilaria appears during the day (diurnal periodic).
- *Clinical features*: Subcutaneous swellings (Calabar swellings), ocular granuloma, edema of eyelid and proptosis.
- *Diagnosis*: Demonstration of adult worm from skin and conjunctiva. Demonstration of microfilaria in peripheral blood during day. High eosinophil count.
- *Treatment*: Diethylcarbamazine with simultaneous administration of corticosteroid or other drugs which may be used. Ivermectin or albendazole.

Onchocerca Volvulus

History and Distribution

Onchocerca volvulus, the “convoluted filaria”, or the “blinding filaria” producing onchocerciasis or “river blindness” was first described by Leuckart in 1893.

- It affects about 40 million people, mainly in tropical Africa, but also in Central and South America. A small focus of infection exists in Yemen and South Arabia.
- Onchocerciasis is the *second* major cause of blindness in the world.

Habitat

The adult worms are seen in nodules in subcutaneous connective tissue of infected persons.

Morphology

Adult worm: The adult worms are whitish, opalescent, with transverse striations on the cuticle (**Fig. 10**).



Fig. 10: *Onchocerca volvulus*

- The *posterior end* is curved, hence the name *Onchocerca*, which means "curved tail".
- The male worm measures about 30 mm in length and 0.15 mm in thickness and the female measures 50 cm by 0.4 mm.

Microfilaria: The microfilariae are **unsheathed** and **nonperiodic**.

- They measure about 300 by 0.8 μm .
- The microfilaria is found typically in the skin and subcutaneous lymphatics in the vicinity of parent worms.
- They may also be found in the conjunctiva and rarely in peripheral blood.

Life Cycle

Life cycle is completed in two hosts:

1. **Definitive host:** Humans are the only definitive host.
2. **Intermediate hosts:** Day-biting female **black flies** of the genus *Simulium* (black flies).

The vector *Simulium* species breed in "fast-flowing rivers"; and therefore, the disease is most common along the course of rivers. Hence, the name "river blindness".

- The female black flies are "pool feeders" and suck in blood and tissue fluids. Microfilariae from the skin and lymphatics are ingested and develop within the vector, becoming the infective third-stage larvae, which migrate to its mouth parts.
- The extrinsic incubation period is about 6 days. Infection is transmitted when an infected *Simulium* bites a person.
- The *prepatent period* in man is 3–15 months.
- The adult worm lives in the human host for about 15 years and the microfilariae for about 1 year.

Pathogenicity and Clinical Features

Pathogenesis depends on the host's allergic and inflammatory reactions to the adult worm and microfilariae.

- The infective larvae deposited in the skin by the bite of the vector develop at the site to adult worms. Adult worms are seen singly, in pairs, or in tangled masses in *subcutaneous tissues*. They may occur in the subcutaneous nodules or free in the tissues.
- The *subcutaneous* nodule or **onchocercoma** is a circumscribed, firm, nontender tumor, formed as a result of fibroblastic reaction around the worms. Nodules vary in size from a few mm to about 10 cm. They tend to occur over anatomical sites where the bones are superficial, such as the scalp, scapulae, ribs, elbows, iliac crest, sacrum and knees. The nodules are painless and cause no trouble except for their unsightly appearance
- Microfilariae cause lesions in the skin and eyes.
 - The skin lesion is a dermatitis with pruritus, pigmentation, atrophy and fibrosis. In an immunologically hyperactive form of **onchodermatitis** called

as **Sowdah**, the affected skin darkens as a result of intense inflammation, which occurs as result of clearing of microfilariae from blood.

- **Ocular** manifestations range from photophobia to gradual blurring of vision, progressing to total blindness. Lesions may develop in all parts of the eye. The most common early finding is conjunctivitis with photophobia. Other ocular lesions include punctate or sclerosing keratitis, iridocyclitis, secondary glaucoma, choroidoretinitis and optic atrophy.

Laboratory Diagnosis

Microscopy: The microfilariae may be demonstrated by examination of skin snip from the area of maximal microfilarial density such as iliac crest or trapezius region, which is placed on a slide in water or saline. The specimen is best collected around midday. This method is specific and most accurate.

- Microfilariae may also be shown in *aspirated material* from subcutaneous nodules.
- In patients with ocular manifestations, microfilariae may be found in **conjunctival biopsies**.
- Adult worms can be detected in the biopsy material of the subcutaneous nodule.

Serology: Serological tests are useful for the diagnosis of cases in which microfilariae are not demonstrated in the skin.

- Enzyme-linked immunosorbent assay is more sensitive than skin snip tests. The test detects antibodies against specific onchocercal antigen.
- A rapid card test using antigen OV16 to detect IgG4 in serum has been evaluated.

Molecular diagnosis: Polymerase chain reaction from skin snips is done in specialized laboratories and is highly sensitive and specific.

Prophylaxis

In 1974, World Health Organization (WHO) launched a control program in West Africa using aerial larvicide for vector control and treatment of patients with ivermectin. This is believed to have prevented blindness in millions of children.

Treatment

- Chemotherapy with **ivermectin** is the main stay of treatment. Ivermectin is given orally in a single dose of 150 $\mu\text{g}/\text{kg}$ either yearly or semiannually. In areas of Africa coendemic for *O. volvulus* and *Loa loa*, however, ivermectin is contraindicated because of severe post-treatment encephalopathy seen in patients.
- **Diethylcarbamazine** and **suramin** have also been used. DEC destroys microfilariae, but usually causes an intense reaction (*Mazzotti reaction*) consisting of pruritus, rash,

lymphadenopathy, fever, hypotension and occasionally, eye damage.

- A 6 week course of doxycycline is macrofilaristatic, rendering the female worm sterile as it targets the *Wolbachia* endosymbiont of filarial parasites.
- Surgical excision is recommended when nodules are located on the head due to the proximity of the worm to the eyes.

KEY POINTS OF ONCHOCERCA VOLVULUS

- *Onchocerca volvulus*, produces onchocerciasis or “river blindness”.
- The adult worm is white with transverse striation on the cuticle. The posterior end is curved.
- Microfilaria is unsheathed, tail-tip free of nuclei and nonperiodic.
- **Definitive host:** Humans.
- **Intermediate host:** Female black flies (*Simulium*).
- **Clinical features:** Subcutaneous nodule formation (onchocercoma). Ocular manifestations—sclerosing keratitis, secondary glaucoma, optic atrophy, chorioretinitis. It is the second major cause of blindness in world.
- **Diagnosis:** Demonstration of microfilaria from skin snips and aspirated material from subcutaneous nodules. Demonstration of IgG4 antibody and PCR.
- **Treatment:** Ivermectin is the drug of choice except in areas coendemic for *O. volvulus* and *L. loa*.

Mansonella Streptocerca

Also known as *Acanthocheilonema*, *Dipetalonema*, or *Tetrapetalonema streptocerca*, this worm is seen only in West Africa.

- The adult worms live in the dermis, just under the skin surface.
- The **unsheathed** microfilariae are found in the *skin*.
- **Culicoides** species are the vectors.
- Chimpanzees may act as reservoir hosts.
- Infection may cause **dermatitis** with pruritus and **hypopigmented macules**.
- Diagnosis is made by demonstration of the microfilariae in skin clippings.
- Ivermectin (single dose of 150 µg/kg) is effective in treating *streptocerciasis*.

■ SEROUS CAVITY FILARIASIS

Mansonella Ozzardi

Mansonella ozzardi is a New World filaria seen only in Central and South America and the West Indies.

- The adult worms are found in the peritoneal and pleural cavities of humans.

- The nonperiodic **unsheathed** microfilariae are found in the blood.
- **Culicoides** species are the vectors.
- Infection does not cause any illness.
- Diagnosis is made by demonstrating microfilariae in blood.
- Ivermectin (single dose 6 mg) is effective in treatment.

Mansonella Perstans

Also known as *Acanthocheilonema*, *Dipetalonema*, or *Tetrapetalonema perstans*, this worm is extensively distributed in tropical Africa and coastal South America.

- The adult worms live in the **body cavities** of humans, mainly in *peritoneum*, less often in *pleura*, and rarely in *pericardium*.
- The microfilariae are unsheathed and subperiodic.
- Vectors are **Culicoides** species.
- African primates have been reported to act as reservoir hosts.
- Infection is generally asymptomatic, though it has been claimed that it causes transient abdominal pain, rashes, angioedema and malaise.
- Diagnosis is by demonstration of the microfilariae in peripheral blood or serosal effusion.
- Doxycycline (200 mg twice a day for 6 weeks) targeting the *Wolbachia* endosymbiont in *M. perstans* is the first effective treatment.

Zoonotic Filariasis

Filariae naturally parasitic in domestic and wild animals may rarely cause accidental infection in man through the bite of their vectors.

- In such zoonotic filariasis, the infective larvae develop into adults, but do not mature to produce microfilariae.
- The worm dies and the inflammatory reaction around the dead worm usually causes clinical manifestations.

Brugia Pahangi

A parasite of **dogs** and **cats** in Malaysia may infect man and cause lymphangitis and lymphadenitis.

Dirofilaria Immitis

The dog “**heartworm**” is a common parasite of dogs, widely distributed in the tropics and subtropics. When humans get infected, the worm lodges in the right heart or branches of the pulmonary artery. The dead worm becomes an embolus blocking a small branch of the pulmonary artery, producing a pulmonary infarct. The healed infarct may appear as a “**coin lesion**” on chest radiography and can be mistaken for malignancy.

Dirofilaria Repens

A natural parasite of dogs, it may sometimes infect humans, causing subcutaneous and subconjunctival nodules. Many *Dirofilaria* species may form nodules in human conjunctiva and are collectively called *Dirofilaria conjunctivae*.

REVIEW QUESTIONS

1. Name the species of filarial worms that infect humans and describe briefly the life cycle and laboratory diagnosis of *Wuchereria bancrofti*.
2. Short notes on:
 - a. Microfilariae
 - b. Periodicity of microfilariae
 - c. Pathogenesis of lymphatic filariasis
 - d. Tropical pulmonary eosinophilia
 - e. Filariasis
 - f. Preventive measures in filariasis
 - g. *Brugia malayi*
 - h. *Loa loa*
 - i. *Onchocerca volvulus*
3. Differentiate between:
 - a. Occult and classical filariasis
 - b. *Microfilaria bancrofti* and *Microfilaria malayi*

MULTIPLE CHOICE QUESTIONS

1. All are true regarding filariasis except
 - a. Man is an intermediate host
 - b. Caused by *Wuchereria bancrofti*
 - c. Involves lymphatic system
 - d. DEC is used in treatment
2. All of the following are true about *Brugia malayi* except
 - a. The intermediate host in India is *Mansonia* mosquito
 - b. The tail tip is free from nuclei
 - c. Nuclei are blurred, so counting is difficult
 - d. Adult worm is found in the lymphatic system
3. Hydrocele and edema in foot occurs in
 - a. *Wuchereria bancrofti*
 - b. *Brugia malayi*
 - c. *Brugia timori*
 - d. *Onchocerca volvulus*
4. In which stage of filariasis are microfilaria seen in peripheral blood
 - a. Tropical eosinophilia
 - b. Early adenolymphangitis stage
 - c. Late adenolymphangitis stage
 - d. Elephantiasis
5. Diurnal periodicity is seen in larvae of
 - a. *Brugia malayi*
 - b. *Wuchereria bancrofti*
 - c. *Loa loa*
 - d. *Mansonella perstans*
6. Which of the following microfilariae is unsheathed
 - a. *Mf. loa*
 - b. *Mf. bancrofti*
 - c. *Mf. malayi*
 - d. *Mf. perstans*
7. All of the following parasites can be detected in urine sample except
 - a. *Wuchereria bancrofti*
 - b. *Schistosoma haematobium*
 - c. *Trichomonas vaginalis*
 - d. *Giardia lamblia*
8. Fugitive or calabar swelling is seen in infection with
 - a. *Onchocerca volvulus*
 - b. *Loa loa*
 - c. *Wuchereria bancrofti*
 - d. *Brugia timori*
9. River blindness is the name given to disease caused by
 - a. *Loa loa*
 - b. *Onchocerca volvulus*
 - c. *Toxoplasma gondii*
 - d. *Acanthamoeba culbertsoni*
10. The filarial worm which can be seen in conjunctiva is
 - a. *Brugia malayi*
 - b. *Loa loa*
 - c. *Onchocerca volvulus*
 - d. None of the above

Answer

1. a 2. b 3. a 4. b 5. c 6. d 7. d
8. b 9. b 10. b

Dracunculus Medinensis

■ COMMON NAME

Guinea worm.

■ HISTORY AND DISTRIBUTION

The guinea worm has been known from antiquity. It is believed to have been the “fiery serpent” in the Bible, which tormented the Israelites on the banks of the Red Sea.

- The technique of extracting the worm by twisting it on a stick, still practiced by patients in endemic areas is said to have been devised by Moses. The picture of the “serpent worm” on a stick may have given rise to the physician’s symbol of caduceus.
- Galen named the disease *dracontiasis*, (Greek *draco*—*dragon or serpent*). Avicenna called it the *Medina worm* as it was prevalent there. Hence, the name *Dracunculus medinensis* (*Dracunculus* being the diminutive of *Draco*).
- The worm was present in tropical Africa, the Middle East in Arabia, Iraq, Iran, and in Pakistan and India. In *India*, it was seen in the dry areas in Rajasthan, Gujarat, Madhya Pradesh, Andhra Pradesh, Maharashtra, Tamil Nadu and Karnataka (**Fig. 1**). About 50 million people were estimated to be infected with the worm.

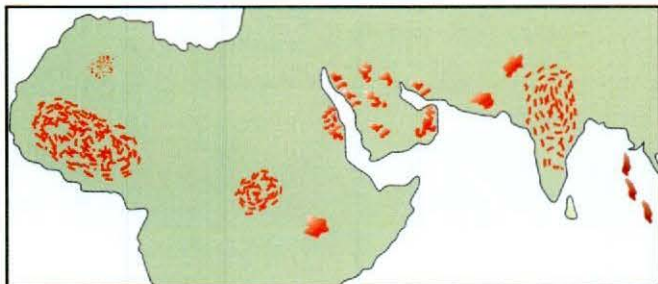


Fig. 1: Geographical distribution of *Dracunculus medinensis* infection (before its eradication)

- The infection has been **eradicated** from India and all of Southeast Asia region by 2000.
- The disease still remains endemic in 13 African countries including Sudan (highest incidence), Niger, etc.

■ HABITAT

The adult females of *D. medinensis* are usually found in the subcutaneous tissue of the legs, arms and back in man.

■ MORPHOLOGY

Adult Worm

The adult female is a long, cylindrical worm with smooth milky-white cuticle resembling a long piece of white twine. It has a blunt anterior end and a tapering recurved tail (**Fig. 2**).

- It measures about a **meter** (60–120 cm) in length and 1–2 mm in thickness.
- The body of the gravid female is virtually filled with the branches of an enormous uterus, containing some 3 million embryos.
- The female worm is **viviparous** (**Box 1**).
- The male worm, which is rarely seen, is much smaller than female being 10–40 mm long and 0.4 mm thick.
- Female worm survives for about a year, whereas life span of male worm is not more than 6 months.

Larva

The larva measures 500–750 μm in length and 15–25 μm in breadth.

- It has a broad anterior end and a slender filiform tail which extends for a third of the entire body length (**Fig. 3**).
- The cuticle shows prominent striations.
- The larva swims about with a coiling and uncoiling motion.

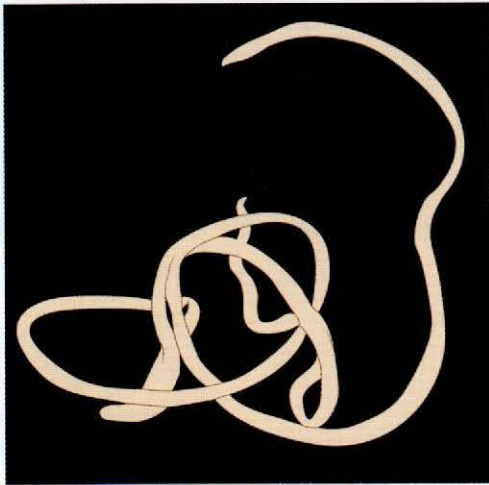


Fig. 2: Adult worm of *Dracunculus medinensis*




Fig. 3: Larva of *Dracunculus medinensis*

Box 1: Viviparous nematodes

- *Dracunculus medinensis*
- *Trichinella spiralis*
- *Wuchereria bancrofti*
- *Brugia malayi*
- *Brugia timori*

- Ovoviviparous nematodes
- *Strongyloides stercoralis*.

■ LIFE CYCLE

D. medinensis passes its life cycle in two hosts:

1. **Definitive host:** Man
2. **Intermediate host:** *Cyclops*, in which embryos undergo developmental changes. There is no animal reservoir (Table 1).

Infective Form

Third-stage larva present in the hemocele of infected *Cyclops*.

- **Mode of transmission:** Humans get infected by drinking unfiltered water containing **infected *Cyclops***.
- **Incubation period:** About 1 year.
- The adult worm, which is viviparous discharges larvae, which are ingested by the **freshwater crustacean *Cyclops***, the intermediate host.

Development of Adult Worm in Man

When water containing infected *Cyclops* is swallowed by man, the *Cyclops* is killed by the gastric acidity and the guinea worm larvae present in its hemocele are released.

- The larvae penetrate the wall of the duodenum and reach the retroperitoneal and subcutaneous connective tissues.

Table 1: Parasites requiring one intermediate host to complete their life cycle

Intermediate host	Parasite
Man	<ul style="list-style-type: none"> • <i>Plasmodium</i> species • <i>Echinococcus granulosus</i> • <i>Echinococcus multilocularis</i> • <i>Taenia multiceps</i>
Pig	<ul style="list-style-type: none"> • <i>Taenia solium</i> • <i>Taenia saginata asiatica</i> • <i>Sarcocystis sui/hominis</i> • <i>Trichinella spiralis</i>
Cow	<ul style="list-style-type: none"> • <i>Taenia saginata</i> • <i>Sarcocystis hominis</i>
Snail	<i>Schistosoma</i> species
<i>Cyclops</i>	<i>Dracunculus medinensis</i>
Sandfly	<i>Leishmania</i> species
Tsetse fly	<i>Trypanosoma</i> species
<i>Chrysops</i>	<i>Loa loa</i>
Mosquito	<ul style="list-style-type: none"> • <i>Wuchereria bancrofti</i> • <i>Brugia</i> spp. • <i>Mansonella</i> spp.
Tick	<i>Babesia</i> species
Triatomine bug	<i>Trypanosoma cruzi</i>
Flea	<ul style="list-style-type: none"> • <i>Hymenolepis nana</i> • <i>Hymenolepis diminuta</i> • <i>Dipylidium caninum</i>

- Here, the larvae develop into male and female adults in about 3–4 months and mate.
- After mating, the male worms die in the tissues and sometimes become calcified.

- In another 6 months time, the fertilized female worm grows in size, matures, and migrates within the connective tissues throughout the body, to finally reach a site where it is likely to come into contact with water.
- The most common site involved is the leg, but other sites such as arms, shoulder, breast, buttocks, or genitalia may also be affected.
- At this site, it secretes a toxin that causes a **blister formation**, which eventually ruptures, discharging a milky-white fluid containing numerous **L1 stage larvae**.
- This process continues for 2–3 weeks, till all the larvae are released.
- The blister develops initially as a reddish papule with a vesicular center and surrounding induration.
- The most common sites for blister formation are the feet between the **metatarsal bones** or on the **ankles**.
- The fluid in the blister is a **sterile yellowish liquid** with polymorphs, eosinophils and mononuclear cells.
- The local discomfort diminishes with the rupture of the blister and release of the embryos.
- **Secondary bacterial infection** is frequent. Sometimes, it may lead to tetanus.
- Sometimes, the worm travels to unusual sites such as the pericardium, the spinal canal, or the eyes, with serious effects.
- *Dracunculiasis* lasts usually for 1–3 months.

Development of Larvae in Cyclops

The larvae swim about in water, where they survive for about a week.

- They are swallowed by the freshwater copepod *Cyclops*, which is the **intermediate host (Fig. 4)**.
- The larvae penetrate the gut wall of the *Cyclops* and enter its body cavity, where they **molt twice**.
- In about **2–4 weeks**, they develop into the infective third-stage larvae (L3).
- The entire life cycle takes about a year, so that all the infected persons develop the blisters and present with clinical manifestations at about the same time of the year (Fig. 4).

■ PATHOGENICITY AND CLINICAL FEATURES

D. medinensis causes *dracunculiasis* or *dracunculosis*.

- Infection induces no illness till the gravid female worm comes to lie under the skin, ready to discharge its embryos.
- The body fluid of the adult worm is **toxic** and leads to **blister formation**.
- A few hours before the development of the blister, there may be constitutional symptoms such as nausea, vomiting, intense pruritus and urticarial rash.

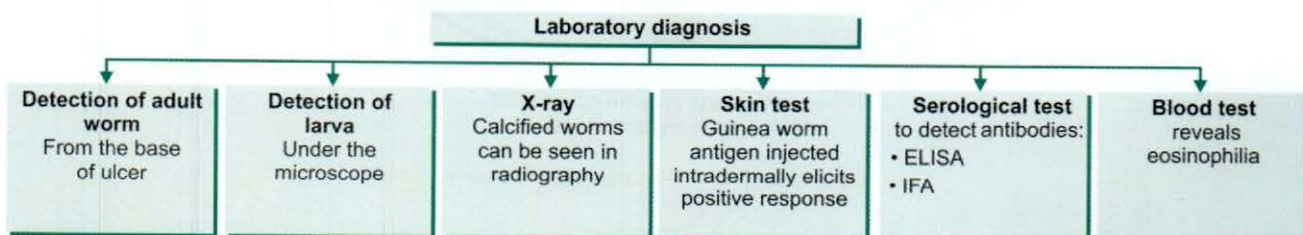
■ LABORATORY DIAGNOSIS

- **Detection of adult worm:** Diagnosis is evident when the tip of the worm projects from the base of the ulcer. Calcified worms can be seen by radiography.
- **Detection of larva:** By bathing the ulcer with water, the worm can be induced to release the embryos (**L1 larvae**), which can be examined under the microscope.
- **Skin test:** An intradermal test with guinea worm antigen elicits positive response.
- **Serological test:** Enzyme-linked immunosorbent assay (ELISA) and immunofluorescence assay (IFA) are frequently used to detect **antibodies** to *D. medinensis* (Flow chart 1).

■ TREATMENT

- Antihistaminics and steroids are of help in the initial stage of allergic reaction.
- Metronidazole, niridazole and thiabendazole are useful in treatment.

Flow chart 1: Laboratory diagnosis of *Dracunculus medinensis*



Abbreviations: ELISA, enzyme-linked immunosorbent assay; IFA, immunofluorescence assay

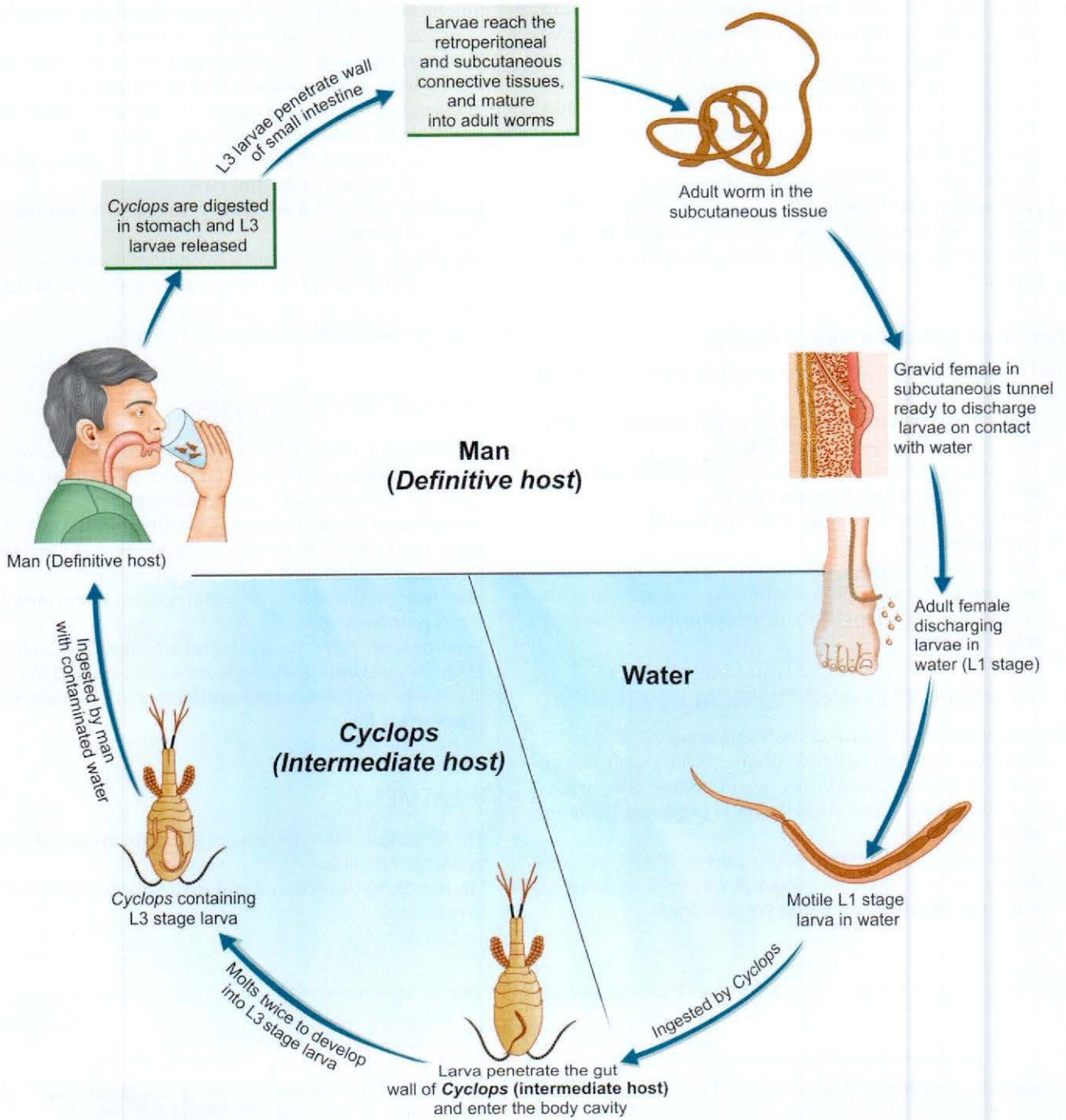


Fig. 4: Life cycle of *Dracunculus medinensis*

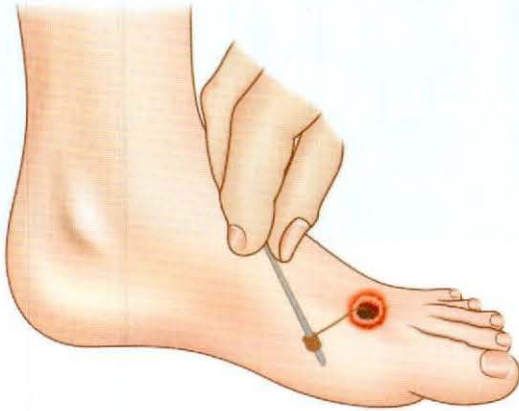


Fig. 5: Ancient technique of removing adult worm from blister

- For removal of the worm, the best method is the ancient technique of patiently twisting it around a stick. It may take 15–20 days to extract the whole worm but if care is taken not to snap the worm, this method is safe and effective (Fig. 5).
- Surgical removal of the worm under anesthesia is another method of treatment.

■ PROPHYLAXIS

- Provision of protected piped water supply is the best method of prevention or else boiling or filtering water through a cloth and then consuming water.
- Destroying *Cyclops* in water by chemical treatment with **Abate** (temephos).
- Not allowing infected persons to bathe or wade in sources of drinking water.

Note: Because of its simple life cycle, localized distribution, and the absence of animal reservoirs, guinea worm infection was eradicable. Measures to eliminate the infection have been successful. Global eradication of the infection is imminent.

KEY POINTS OF DRACUNCULUS MEDINENSIS

- Guinea worm infection has been eradicated from India.
- Adult females are found in subcutaneous tissue of man.
- Female worm is viviparous releasing thousands of motile first-stage larvae into the water.
- **Definitive host:** Humans.

- **Intermediate host:** *Cyclops*, in which larvae undergo development changes to become third-stage larvae.
- **Infective form to humans:** *Cyclops* containing L3 larvae.
- **Clinical features:** Pruritus, urticarial rash, blister formation in skin and cellulitis.
- **Diagnosis:** Detection of adult worm and larval form in ulcer. Demonstration of dead worm by X-ray. Serology—ELISA and IFA.
- **Treatment:** Antihistaminics and steroids in initial stage. Metronidazole and niridazole are useful. Surgical removal of the worm.

REVIEW QUESTIONS

1. List viviparous nematodes and describe briefly the life cycle and laboratory diagnosis of *Dracunculus medicinensis*.
2. Short notes on:
 - a. Pathogenicity and clinical features of dracunculosis
 - b. Tissue nematodes
 - c. Prophylaxis of guinea worm infection

MULTIPLE CHOICE QUESTIONS

1. Which of the following parasite does not enter into the body by skin penetration
 - a. *Dracunculus*
 - b. *Necator americanus*
 - c. *Ancylostoma duodenale*
 - d. *Strongyloides*
2. Definitive host for Guinea worm is
 - a. Man
 - b. *Cyclops*
 - c. Snail
 - d. *Cyclops* and man
3. Guinea worm is
 - a. *Enterobius*
 - b. *Trichuris*
 - c. *Dracunculus*
 - d. *Taenia solium*
4. *Cyclops* is the source of infection in
 - a. *Dracunculus*
 - b. *Spirometra*
 - c. Both
 - d. None

Answer

1. a 2. a 3. c 4. c

Miscellaneous Nematodes

■ ANGIOSTRONGYLUS CANTONENSIS

Common Name

Rat lungworm.

History and Distribution

Angiostrongylus cantonensis causes *eosinophilic meningoencephalitis* (*cerebral angiostrongyliasis*) in humans.

- This condition was first reported from Taiwan in 1945.
- Since then, hundreds of cases have occurred in Taiwan, Thailand, Indonesia and the Pacific islands.
- Human infection has also been recorded in India, Egypt, Cuba and the United States of America (USA).

Habitat

The adult worm is present in the branches of pulmonary artery in rats.

Morphology

- It is about 20 mm long and 0.3 mm thick.
- Eggs of *Angiostrongylus* resemble those of hookworms.

Life Cycle

Natural host: Rats.

Intermediate hosts: Molluscs, slugs and snails.

Infective form: Third-stage larvae.

- The eggs hatch in the lungs and the larvae which migrate up the trachea are swallowed and expelled in the feces.
- The larvae infect molluscs, slugs and snails, which are the intermediate hosts. Crabs, freshwater prawns and frogs have also been found to be naturally infected (Box 1).
- The larva undergoes two molts.
- In about 2 weeks, the infective third-stage larvae develop, which can survive in the body of the intermediate host for about a year.
- Rats become infected when they eat the molluscs.

Box 1: Nematodes with crabs and crayfishes as source of infection

- *Angiostrongylus cantonensis*
- *Paragonimus westermani*

- In the rat, the larvae penetrate the gut wall to enter the venules and are carried in circulation to the brain, where they develop into young adults in about a month.
- These penetrate the cerebral venules and reach the pulmonary artery, where they lodge, mature, and start laying eggs.
- Human infection is acquired by eating infected molluscs and other intermediate hosts containing the third-stage larvae. Infection may also occur through raw vegetables or water contaminated with the larvae.
- The larvae penetrate the gut and are carried to the brain, but they are unable to develop further.
- They die and induce an inflammatory reaction in the brain and meninges to produce meningoencephalitis.
- The incubation period is about 2–3 weeks.

Clinical Features

Patients present with intense headache, fever, neck stiffness, convulsions and various degrees of pareses.

- The worm may also cause ocular complications.
- Infection does not seem to confer immunity, as second attacks have been recorded.
- Fatality is rare.

Diagnosis

Peripheral eosinophilia and high cerebrospinal fluid (CSF) eosinophilia (up to 90%) are constant features.

- Larvae and adult worms may be seen in CSF (Table 1).

Treatment

Most cases recover spontaneously, only some develop residual pareses.

Table 1: Parasites found in cerebrospinal fluid

Protozoa	Helminths
• <i>Trypanosoma brucei</i> spp.	<i>Angiostrongylus cantonensis</i>
• <i>Naegleria fowleri</i>	
• <i>Acanthamoeba</i> spp.	

- **Anthelmintic treatment** is not recommended, as the disease is due to dead larvae.
- The drugs may even enhance the illness due to destruction of more larvae.

Note: *Angiostrongylus costaricensis*, inhabiting the mesenteric arteries of wild rodents in Costa Rica in Central America, may cause human infections. The disease presents as inflammation of the lower bowels and is known as **abdominal angiostrongyliasis**.

■ CAPILLARIA PHILIPPINENSIS

C. philippinensis is a small nematode, about 3–4 mm long. It belongs to the **superfamily Trichuroidea**.

History and Distribution

It has been responsible for several fatal cases of diarrheal illness in the Philippines from 1963.

- It has also been reported from Thailand, Japan, Iran and Egypt.

Habitat

The adult worm inhabits the **small intestine** particularly the **jejunum**.

Life Cycle

Definitive host: Birds (fish-eating birds)

Intermediate host: Fish.

- Its life cycle has not been worked out.
- **Human infection** is believed to occur by **eating infected fish**, which are the intermediate hosts harboring the infective larvae.
- **Autoinfection** is stated to be responsible for the **high degree of infection** in man.

Clinical Features

The clinical disease consists of **malabsorption syndrome** with severe **diarrhea**, **borborygmi** and **abdominal pain**.

- Serious cases may be **fatal in 2 weeks to 2 months**.

Diagnosis

Diagnosis is made by **detection** of the **eggs**, larvae and adults in **stools**. The **eggs resemble those of *Trichuris trichiura***, but are smaller.

Treatment

Mebendazole is useful in treatment.

Note: *C. hepatica* is a common parasite of rats, which may occasionally infect man causing hepatitis that may be fatal.

■ GNATHOSTOMA SPINIGERUM

History and Distribution

Gnathostoma spinigerum, originally described from **gastric tumors of a tiger**, parasitizes dogs, tigers, lions, cats and their wild relatives.

- **Gnathostomiasis** is a **zoonotic infection** of man.
- Human infections have been reported from Thailand and other countries in the Far East.
- Cases of human infection with ***G. spinigerum*** and a related species ***G. hispidum*** have also been reported from India.

Morphology

It is a small **spirurid nematode**. The female (25–55 mm) is longer than the male (10–25 mm).

- The eggs are **oval, brown, unsegmented** bearing a **transparent knob-like thickening** at one end (**Fig. 1**).

Life Cycle

Definitive host: Dog, cat and other carnivorous animals

First intermediate host: *Cyclops*

Second intermediate host: Freshwater fish and frog

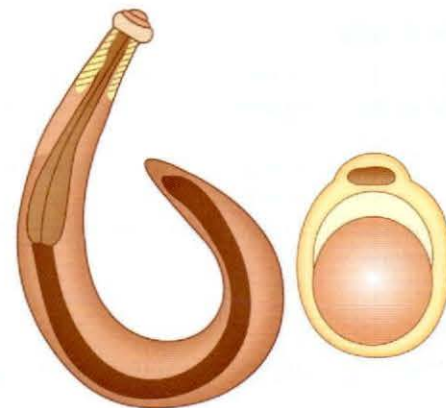

Fig. 1: Adult worm and egg of *Gnathostoma spinigerum*

Table 2: Helminths causing central nervous system (CNS) infection

Cestodes	Trematodes	Nematodes
• <i>Taenia solium</i>	• <i>Schistosoma japonicum</i>	• <i>Trichinella spiralis</i>
• <i>Taenia multiceps</i>	• <i>Paragonimus westermani</i>	• <i>Angiostrongylus cantonensis</i>
• <i>Spirometra</i> spp.		• <i>Toxocara canis</i>
• <i>Echinococcus granulosus</i>		• <i>Toxocara cati</i>
• <i>Echinococcus multilocularis</i>		• <i>Gnathostoma spinigerum</i>
		• <i>Strongyloides stercoralis</i>

Paratenic host: Birds and humans.

- Adult worm resides in the tumors or granulomatous lesions of the stomach wall of cat and dog. Eggs are laid in the tumors.
- They pass into gastric lumen by means of an aperture and are discharged in feces into water, where they hatch into first-stage larva.
- L1 larvae are ingested by *Cyclops* (first intermediate host) in which the second-stage larvae develop.
- *Cyclops* is eaten by fishes, frogs and snakes, in which the third-stage larvae develop (L3).
- When the third-stage larvae are eaten by cats, dogs, or other suitable hosts, the larvae develop into adults inside their body.
- When other hosts that are not suited to be a definitive host (reptiles, birds or mammals) get infected, the larva does not undergo any further development and such a host is paratenic.
- Humans get infected by eating undercooked fish containing third-stage larvae, but further development of the worm cannot proceed normally in paratenic host.
- The larvae migrate in the tissues of infected persons, causing indurated nodules or abscesses and creeping eruption (*larva migrans*) (Table 2).

Clinical Features

The migration of larvae in the tissues of the infected persons leads to indurated nodules or abscesses and creeping eruption.

- When the nodules are superficial, they can be incised and the larvae can be removed.
- The wandering larvae may reach the brain or eyes causing severe damage.

Diagnosis

An intradermal test using the larval or adult antigens has been described.

- The lesion can be biopsied and the presence of typical larva confirms the diagnosis.

Table 3: Parasites with fishes as the source of infection

Freshwater fish	Marine fish
• <i>Gnathostoma spinigerum</i>	<i>Anisakis simplex</i>
• <i>Capillaria philippinensis</i>	
• <i>Clonorchis sinensis</i>	
• <i>Heterophyes heterophyes</i>	
• <i>Metagonimus yokogawai</i>	
• <i>Diphyllobothrium latum</i>	

Treatment

- Incision of the lesion and removal of larva.
- Albendazole, mebendazole in high doses has also been recommended.

ANISAKIASIS

Anisakis species are nematode parasites of marine mammals like dolphins, seals and whales.

Anisakiasis is common in Japan and other places like Netherland and USA where fresh or undertreated fish is a popular food (Table 3).

Life Cycle

Definitive host: Dolphin, seals and whales

Intermediate host: Sea fishes

- The eggs are passed in seawater, hatch and infect marine crustacea (krill).
- Marine fish eats the infected krill and the infective larvae remain in the fish's viscera and flesh.
- When humans consume uncooked or improperly preserved fish containing the infective larvae, they penetrate the gut wall at the level of the throat, stomach, or intestine, leading to local inflammation and granuloma formation.

Clinical Features

Infection with the larva of anisakis is known as **anisakiasis** or **herring worm disease**.

- Local inflammation and granuloma formation is present at the level of throat, stomach, or intestine, depending on the level of penetration of gut wall.
- The illness varies according to the site involved, such as throat irritation or acute gastric or bowel symptoms.
- No case has been reported from India.

Treatment

Endoscopic surgical treatment of gastric and intestinal anisakiasis is the **method of choice**.

Prophylaxis

Proper cooking of sea fish.

REVIEW QUESTIONS

1. Short notes on:
 - a. Anisakiasis
 - b. *Gnathostoma spinigerum*
 - c. *Angiostrongylus cantonensis*
 - d. Paratenic host

MULTIPLE CHOICE QUESTIONS

1. Rat lung worm is the common name of
 - a. *Paragonimus westermani*
 - b. *Toxocara canis*
 - c. *Angiostrongylus cantonensis*
 - d. *Mansonella streptocerca*
2. Paratenic host for *Angiostrongylus cantonensis* is
 - a. Rat
 - b. Man
 - c. Frog
 - d. Camel
3. All of the following parasites are found in CSF except
 - a. *Naegleria*
 - b. *Acanthamoeba*
 - c. *Angiostrongylus*
 - d. *Trypanosoma*
4. Definitive host for *Capillaria philippinensis* is
 - a. Man
 - b. Rat
 - c. Birds
 - d. Fish

Answer

1. c 2. b 3. d 4. c

Diagnostic Methods in Parasitology

■ INTRODUCTION

Laboratory procedures play an important role in the diagnosis of parasitic infections, both for confirmation of clinical suspicion and for identifying unsuspected infections. The principles of laboratory diagnosis are the same as in bacterial and viral infections, but the relative importance of the different methods varies greatly.

- While isolation of the infecting agent and detection of specific antibodies are the major methods in bacteriology and virology, they are of much less importance in parasitology than **morphological identification** of the parasite by microscopy.
- Compared to bacteria and viruses, parasites are very large and possess distinctive shape and structure, which enables their specific diagnosis on morphological grounds.
- Due to their complex antigenic structure and extensive cross-reactions, serological diagnosis is of limited value in parasitic infections.
- Although many pathogenic parasites can be grown in laboratory cultures, this method is not suitable for routine diagnosis because of its relative insensitivity and the delay involved.
- Morphological diagnosis of parasites consists of *two steps*: (1) detection of the parasite or its parts in clinical samples and (2) its identification.
 1. **Detection** depends on collection of the appropriate samples and their examination by suitable techniques.
 2. **Identification** requires adequate skill and expertise in recognizing the parasite in its various stages and its differentiation from morphologically similar artifacts.

A description of the common diagnostic techniques in parasitology is given here.

■ EXAMINATION OF STOOL

Collection of Fresh Stool Specimen

- All stool specimens should be collected in a suitable, clean, wide mouthed container like a plastic container with a light-fitting lid, waxed cardboard box, or match box.
- All fresh specimens should be handled carefully because each specimen represents a potential source of infectious material.
- The specimen should not be contaminated with water, urine, or disinfectants.

Liquid stools should be examined or preserved within **30 minutes** of passage. Soft stools should be examined or preserved within **1 hour of passage** and formed stool should be examined or preserved within **24 hours** of passage.

- Normally passed stools are preferable, although samples obtained after purgative (sodium sulfate) or high saline enema may also be used.
- Examination of fresh specimens is necessary for observing motility of protozoan parasites.
- Stool should be examined for its consistency, color, odor and presence of blood or mucus.
- In some instances, parasites may be seen on gross inspection, as in the case of roundworm, pinworm, or tapeworm proglottids.

Microscopic Examination

- The microscope should be equipped with a *micrometer* eyepiece, as it is often essential to measure the size of parasites. For example, the differentiation between cysts of the pathogenic *Entamoeba histolytica* and the nonpathogenic *E. hartmanni* is based entirely on their sizes.

- Microscopy should also include contributory findings such as the presence of *Charcot-Leyden crystals* and *cellular exudates* such as pus cells, red blood cells (RBCs) and macrophages.
- For detection of parasites, it is best to employ a combination of methods, as different methods serve different purposes.
- The methods include examination of: (i) **wet mounts**, (ii) **thick smears**, and (iii) **permanent-stained preparations**.
- Various concentration methods can be used to increase the sensitivity of microscopic examination.
- If there is a delay in examination, use of preservatives such as formalin, sodium acetate and polyvinyl alcohol is recommended.

Wet Mounts

- **Unstained wet film:** The unstained wet film is the standard preparation and is made by emulsifying a small quantity of stool in a drop of (0.85%) saline placed on a slide and applying a coverslip (22 mm × 22 mm) on top, avoiding air bubbles. A proper preparation should be just dense enough for newspaper print to be read through it. If the feces contains mucus, it is advisable to prepare films using the mucus part. The entire field under coverslip should be systematically examined with low-power objective (10X) under lowlight intensity. Any suspicious object may then be examined with the high-power objective.
- **Wet saline mounts:** Wet saline mounts are particularly useful for detecting live motile trophozoites of *E. histolytica*, *Balantidium coli* and *Giardia lamblia*. Eggs of helminths are also readily seen. Rhabditiform larvae of *Strongyloides stercoralis* are detected in freshly passed stool.
- **Eosin staining:** Eosin 1% aqueous solution, can be used for staining wet films. Eosin stains everything except living protoplasm. Trophozoites and cysts of protozoa, as well as helminth larvae and thin-walled eggs stand out as pearly-white objects against a pink background and can be easily detected. Chromatoid bodies and nuclei of amebic cysts can be seen prominently. Eosin also indicates the viability of cysts; live cysts are unstained and dead ones are stained pink.
- **Iodine staining:** Iodine staining of wet mounts is another standard method of examination. Either **Lugol's iodine** diluted (5 g iodine, 10 g potassium iodide and 100 mL of distilled water) or Dobell and O'Connor iodine solution (1 g iodine, 2 g potassium iodide and 50 mL of distilled water) are used. Iodine helps to confirm the identity of cysts, as it prominently stains the glycogen vacuoles and nuclei. Protozoan cyst stained with iodine show yellow-gold cytoplasm, brown glycogen material and pale refractile nuclei.

Thick Smears

These are not useful for routine examination, but are valuable in surveys for intestinal helminth eggs.

The method described by Kato and Miura in 1954 is known as the **Kato thick smear technique**.

- About 50 mg stool is taken on a slide and covered with a special wettable cellophane coverslip soaked in glycerin containing aqueous malachite green.
- The preparation is left for about an hour at room temperature, during which the glycerin clears the stool, enabling the helminth eggs to be seen distinctly under low-power magnification.
- This method is, however not useful for diagnosis of protozoa or helminth larvae.

Permanent Stained Smears

Permanent stained smears are examined normally under oil immersion (100X) objective.

- Confirmation of the intestinal protozoan, both trophozoites and cysts, is the primary purpose of this technique.
- Helminthic eggs and larvae take up too much stain and usually cannot be identified.
- Permanent smear can be prepared with both fresh and polyvinyl alcohol preserved stool specimen.
- The two methods commonly used are: (1) the *iron-hematoxylin stain* and (2) *Wheatley's trichrome stain*. The iron-hematoxylin is the older method, but is more difficult.

1. Iron-hematoxylin stain

Procedure:

- Fecal smear on a slide is fixed in *Schaudinn's solution* for 15 minutes and is immersed successively for 2–5 minutes in 70% alcohol, 70% alcohol containing a trace of iodine, and then 50% alcohol for 2–5 minutes.
- It is washed in water for 5–10 minutes and immersed in 2% aqueous ferric ammonium sulfate solution for 5–15 minutes.
- It is again washed in water for 3–5 minutes and stained with 0.5% aqueous hematoxylin for 5–15 minutes.
- It is washed for 2–5 minutes and differentiated in saturated aqueous solution of picric acid for 10–15 minutes.
- It is then washed for 10–15 minutes and dehydrated by passing through increasing strengths of alcohol, cleared in toluene or xylol and mounted.

2. Trichrome stain (Wheatley's method)

- The trichrome technique of Wheatley for stool specimens is a modification of Gomori's original staining procedure for tissue.

Box 1: Reagents of trichrome stain

- Chromotrope 2R: 0.6 g
- Light green SF: 9.3 g
- Phosphotungstic acid: 0.7 g
- Acetic acid (glacial): 1.0 mL
- Distilled water: 100 mL

- It is a quicker and simpler method, which produces uniformly well-stained smears of the intestinal protozoa, human cells, yeast cells and artifact material in about 45 minutes or less.

Procedure:

- The smear is fixed in **Schaudinn's solution** and taken successively through alcohol, as earlier.
- Trichrome stain (chromotrope 2R, light green SF, phosphotungstic acid in glacial acetic acid and distilled water) is then applied for 5–10 minutes, differentiated in acid-alcohol dehydrated, cleared and mounted (**Box 1**).
- **Modified trichrome stain for microsporidia:**
 - This staining method is based on the fact that stain penetration of the microsporidial spore is very difficult, thus more dye is used in the chromotrope 2R than that routinely used to prepare Wheatley's modification of trichrome method and the staining time is much longer (90 minutes).
 - Other staining techniques are used for special purpose. For example, modified acid-fast or Giemsa stain is employed for detection of oocysts of *Cryptosporidium* and *Isospora*.
- **Modified Ziehl-Neelsen (acid-fast) stain (hot method):**
 - Oocysts of *Cryptosporidium* and *Isospora* in fecal specimens may be difficult to detect, without special staining. Modified acid-fast stains are recommended to demonstrate these organisms.
 - Application of heat to the carbol-fuchsin assists in the staining and the use of a milder decolorizer (5% sulfuric acid) allows the organisms to retain more of their pink-red color.
- **Kinyoun's acid-fast stain (cold method):**
 - *Cryptosporidium* and *Isospora* have been recognized as causes of severe diarrhea in immunocompromised hosts but can also cause diarrhea in immunocompetent hosts.
 - Kinyoun's acid-fast stains are recommended to demonstrate these organisms.
 - Unlike the Ziehl-Neelsen modified acid-fast stain, Kinyoun's stain does not require the heating of reagents for staining (**Box 2**).

Procedure:

- Smear 1–2 drops of specimen on the slide and allow it to air dry.

Box 2: Reagents of Kinyoun's acid-fast stain

- 50% ethanol (add 50 mL of absolute ethanol and 50 mL of distilled water).
- Kinyoun's carbol-fuchsin:
 - **Solution A:** Dissolve 4 g of basic fuchsin in 20 mL of 95% ethanol.
 - **Solution B:** Dissolve 8 g of phenol crystals in 100 mL of distilled water.
 - Mix solution A and B, and store at room temperature.
- 1% sulfuric acid.
- Alkaline methylene blue.
- Dissolve 0.3 g of methylene blue in 30 mL of 95% ethanol, and add 100 mL of dilute (0.01%) potassium hydroxide.

- Fix with absolute methanol for 1 minute.
- Flood the slide with Kinyoun's carbol-fuchsin and stain it for 5 minutes.
- Rinse the slide briefly (3–5 seconds) with 50% ethanol.
- Rinse the slide thoroughly with water.
- Decolorize by using 1% sulfuric acid for 2 minutes or until no more color runs from the slide.
- Rinse the slide with water (it may take less than 2 minutes; do not destain too much) and drain.
- Counterstain with methylene blue for 1 minute.
- Rinse the slide with water and air dry.
- Examine with the low or high dry objective. To see internal morphology, use the oil objective (100X).
- **Auramine O stain for coccidia:**
 - *Coccidia* are acid-fast organisms and also stain well with phenolized auramine O.
 - The size and typical appearance of *Cryptosporidium*, *Cyclospora* and *Isospora* oocysts enable auramine O-stained slides to be examined at low-power under the 10X objective.
 - The entire sample area can usually be examined in less than 30 seconds.
 - The low cost of the reagents, the simple staining protocol and the rapid microscopic examination also make this staining method suitable for screening unconcentrated stool specimens. Concentrated sediment from fresh or nonpolyvinyl alcohol-preserved stool may also be used.

Concentration Methods

When the parasites are scanty in stools, routine microscopic examination may fail to detect them. It is then necessary to selectively concentrate the protozoan cysts and helminth eggs and larvae. Concentration may be done using fresh or preserved feces. Several concentration techniques have been described.

They can be classified as the floatation or sedimentation methods.

- In *floatation method*, the feces are suspended in a solution of high specific gravity, so that parasitic eggs and cysts float up and get concentrated at the surface.
- In *sedimentation method*, the feces are suspended in a solution with low specific gravity, so that the eggs and cysts get sedimented at the bottom, either spontaneously or by centrifugation.

Floatation Methods

• Saturated salt solution technique

Procedure:

- A simple and popular method is salt floatation using a saturated solution of sodium chloride, having a specific gravity of 1.2. About 2 mL of the salt solution is taken in a flat bottomed tube (or *penicillin bottle*) and 1 g of feces is emulsified in it.
- The container is then filled completely to the brim with the salt solution.
- A slide is placed on the container, so that it is in contact with the surface of the solution without any intervening air bubbles. After standing for 20–30 minutes, the slide is removed, without jerking, reversed to bring the wet surface on top, and examined under the microscope.
- A coverslip need not to be applied, if examination is done immediately. Any delay in examination may cause salt crystals to develop, interfering with clarity of vision.

This simple method is quite useful for detecting the eggs of the common nematodes such as roundworm, hookworms and whipworm, but is not applicable for eggs of tapeworms, unfertilized egg of *Ascaris lumbricoides*, eggs of trematodes and protozoan cysts.

• Zinc sulfate centrifugal floatation

Procedure:

- Make a fine suspension of about 1 g of feces in 10 mL of water and strain through gauze to remove coarse particles.
- Collect the liquid in a small test tube and centrifuge for 1 minute at 2,500 revolutions per minute. Pour off the supernatant, add water, resuspend, and centrifuge in the same manner, repeating the process, till the supernatant is clear.
- Pour off the clear supernatant, add a small quantity of zinc sulfate solution (specific gravity 1.18–1.2) and resuspend the sediment well.
- Add zinc sulfate solution to a little below the brim and centrifuge at 2,500 revolution per minute for 1 minute (**Fig. 1A**).
- Take samples carefully from the surface, using a wire loop, transfer to slide and examine under the microscope (**Fig. 1B**). A drop of dilute iodine helps to bring out the protozoan cysts in a better way.

This technique is useful for protozoan cysts and eggs of nematodes and small tapeworms, but it does not detect unfertilized roundworm eggs, nematode larvae, and eggs of most trematodes and large tapeworms.

• Sugar floatation technique:

Sheather's sugar floatation technique is recommended for the detection of cryptosporidia infection.

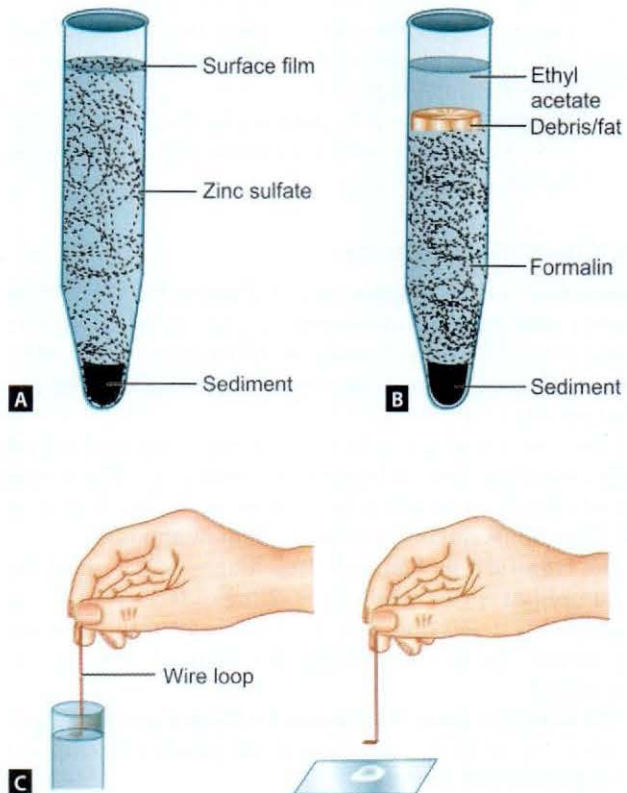
Sedimentation Methods

• Formol-ether sedimentation technique

Formol-ether concentration method has been the most widely used sedimentation method (**Fig. 1C**).

Procedure:

- Emulsify 1–2 g feces in 10 mL of water and let large particles sediment. Take the supernatant and spin at 2,500 revolutions per minute for 2–3 minutes.
- Discard the supernatant. Add 10% formol-saline, mix well and let it stand for 10 minutes.
- Add 3 mL ether and shake well. Spin at 2,500 revolutions per minute for 2–3 minutes. Four layers



Figs 1A to C: (A) Zinc sulfate floatation concentration technique; (B) Method used to remove surface film in the zinc sulfate floatation concentration procedure; and (C) Formol-ether sedimentation technique

will form—(1) a top layer of ether, (2) a plug of debris at the interface, (3) the formalin-saline layer and (4) the sediment at the bottom (**Fig. 1C**).

- Carefully detach the debris from the sides of the tube and discard the top three layers.
- Suspend the sediment in a few drops of fluid and examine wet mount and iodine preparation.
- As ether is inflammable and explosive, its use can be hazardous. Ethyl acetate can be conveniently used in its place, with equally good results.

The method is useful for all helminth eggs and protozoan cysts.

- **Baermann concentration method**

Procedure:

- Another method of examination of stool specimen suspected of having small numbers of *Strongyloides* larvae is the use of a modified Baermann apparatus (**Fig. 2**).
- The Baermann technique, which involves using a funnel apparatus, relies on the principle that active larvae migrate from a fresh fecal specimen that has been placed on a wire mesh with several layers of gauze, which are in contact with tap water.
- Larvae migrate through the gauze into the water and settle to the bottom of the funnel, where they can be collected and examined.
- Besides being used for patient's stool specimens, this technique can be used to examine soil specimens for the presence of larvae.

Egg Counting Methods

A **semiquantitative assessment** of the worm burden can be made by estimating the number of eggs passed in stools. This is done by **egg counts** and by relating the counts to the number of worms present by assuming the number of eggs passed per worm per day.

However, these are at best approximations and only a rough indication of worm burden can be obtained. Egg counts help to classify helminth infections as heavy, moderate, or light. Egg counts can be done by different methods.

- The **standard wet mount** gives rough indication of the number of eggs. Ordinarily, 1–2 mg of feces is used for preparing a wet film, and if all the eggs in the film are counted. The number of eggs per gram of feces can be assessed.
- The **modified Kato thick smear technique** using 50 mg of stool cleared by glycerin-soaked cellophane coverslip can be used for egg counting.
- **McMaster's egg counting** chamber can also be used. In this method, eggs in 20 mg of stool are concentrated by salt floatation on the squared grid on the roof of the chamber, which can be counted.

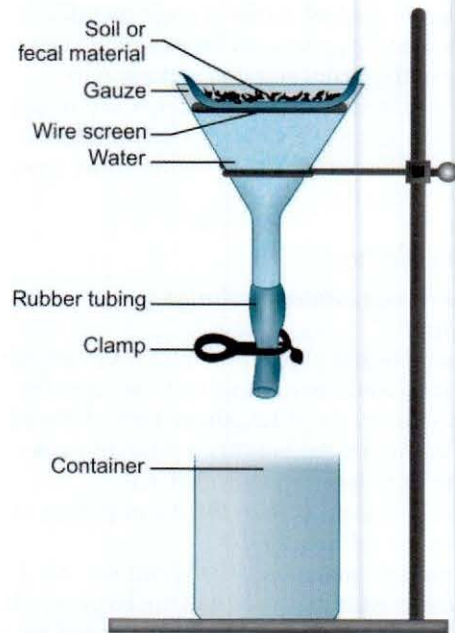
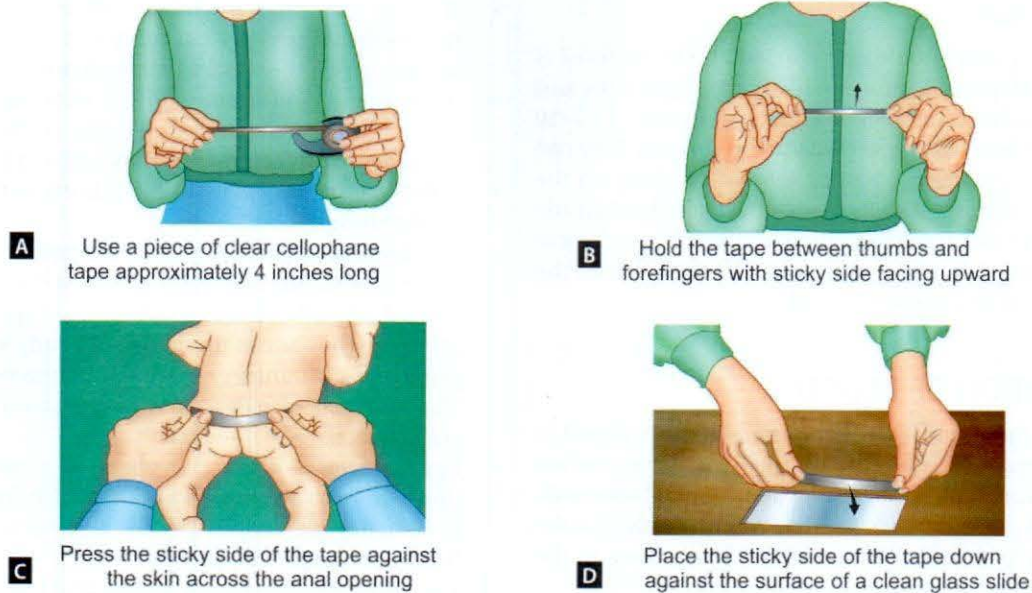


Fig. 2: Baermann concentration method

Box 3: Hatching test for schistosoma eggs

This test is used to demonstrate the viability of the miracidia within the schistosome eggs recovered from the urine or stool. Fecal or urine specimens must be processed without any preservative. The specimens are placed in 10 volumes of dechlorinated or spring water. Living miracidia may be released by hatching within few hours. The specimens are examined microscopically for presence of miracidia, which indicates active infection.

- In **Stoll's dilution technique**, 4 g of feces is mixed thoroughly with 56 mL of N/10 sodium hydroxide using beads in a rubber stoppered glass tube. Using a pipette, exactly 0.075 mL of the sample is transferred to a slide, cover glass is applied, and all the eggs present are counted. The number multiplied by 200 gives the number of eggs per gram of feces. This figure requires to be corrected for the consistency of feces, by multiplying by 1 for hard formed feces, by 2 for mushy formed feces, by 3 for loose stools and by 4 for liquid stools. Watery stools are unfit for counting.
- Special techniques have been described for particular purposes as for example, **Bell's dilution-filtration count** for schistosome eggs (**Box 3**).
- **Scotch tape method:** This is a simple and effective method for detection of eggs and female worms of *Enterobius vermicularis* and occasionally eggs of *Taenia solium*, *T. saginata* and *Schistosoma mansoni*. In this method, a piece of transparent adhesive tape is pressed firmly



Figs 3A to D: Method for collection of a cellophane (scotch) tape preparation for pinworm diagnosis. This method dispenses with the tongue depressor, requiring only tape and a glass microscope slide. The tape must be pressed deep into the anal crack

against perianal skin, and the adhesive surface of the tape is spread on a glass slide (**Figs 3A to D**). The slide is then placed under microscope and observed for parasitic eggs. A drop of toluene or xylol may be placed between the tape and the slide to clear the preparation. The specimen should be collected for 3 consecutive days at night or early in the morning.

Fecal Culture

Fecal culture is not used for routine diagnosis, but for species identification, for example in differentiation between *Ancylostoma* and *Necator*.

Harada-Mori Filter Paper Strip Culture

The test detects light infection with hookworm, *S. stercoralis*, *Trichostrongylus* spp, as well as to facilitate species identification of helminths.

The Harada-Mori culture method uses strips of filter paper on which feces is smeared in the middle third. The paper strips are kept in conical centrifuge tubes with water at the bottom, in which the strips dip (**Fig. 4**). The tubes are kept at room temperature in the dark for 7-10 days, during which time the larvae develop and fall into the water at the bottom, from which they can be collected. Also, caution must be exercised in handling the paper strip itself, since infective *Strongyloides* larvae may migrate upwards, as well as downwards on the paper strip.

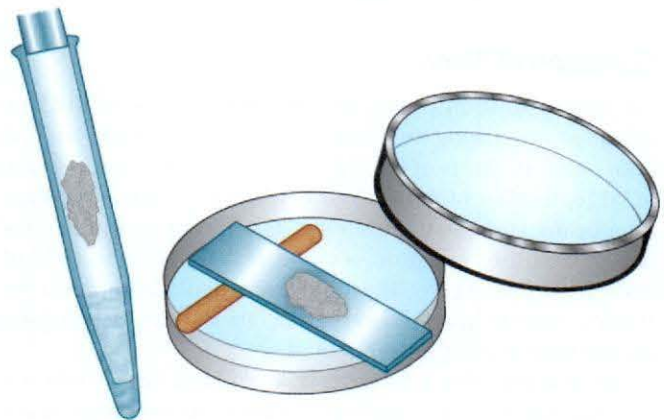


Fig. 4: Harada-Mori tube method and petri dish culture method

Agar Plate Culture for *Strongyloides*

Agar plate cultures are used to recover larvae of *S. stercoralis* and appear to be more sensitive. Approximately, 2 g fecal specimens are inoculated onto agar plates. Then the plates are sealed with tape to prevent accidental infection and placed in room temperature for 2 days. In positive cases, larvae will crawl over the agar, making visible tracks over it. For further confirmation of larvae, the plates are examined microscopically.

Charcoal Culture

Charcoal cultures are simple and efficient. Softened feces is mixed with 5–10 parts of moistened charcoal granules and packed into a suitable container and kept covered. In 7–10 days, the larvae hatch out and come to the surface. They can be collected by applying a pad of soft cotton cloth on the surface for half an hour. The cloth is removed and kept upside down on a sedimentation flask, filled to the brim with warm water. The larvae fall to the bottom of the flask, while the charcoal particles remain on the cloth.

■ EXAMINATION OF BLOOD

Next to feces, the largest number of parasites are found in blood. Blood examination is the routine diagnostic method in malaria, filariasis, African trypanosomiasis and babesiosis. It is sometimes positive in Chagas disease and rarely, in kala-azar and toxoplasmosis. Blood examination is done in the following ways.

Examination for Malarial Parasites

The standard diagnostic method in malaria is the examination of stained blood films—both thin and thick smears.

Collection of Blood

For demonstration of malarial parasites, blood should be collected not during the peak of fever, but optimally several hours after it. Bouts of fever follow the synchronous rupture of large number of parasitized erythrocytes, releasing their membrane shreds and contents. The emerging merozoites parasitize other erythrocytes and initiate a fresh cycle of *erythrocytic schizogony*. The timing is particularly important in *P. falciparum* infections, as here the late stages of schizogony are not seen in peripheral circulation.

- In practice, the rule is to take a blood smear when a suspected malaria patient is first seen and then again subsequently after a bout of fever.
- Smears should invariably be collected before starting antimalarial treatment.

Thin smear:

- A thin smear is prepared from finger prick or in infants from heel prick blood or ethylene diaminetetra-acetic acid (EDTA) anticoagulated venous blood can also be used, provided blood films are made within 30 minutes.
- A small drop (10–15 μL) is spread on a clean grease-free slide with a spreader to give a uniform smear, ideally a single cell thick smear. The margins of the smear should be well short of the sides of the slide, and the tail should end a little beyond the center of its length.

- The thin smear displays blood cells and parasites clearly. Its only disadvantage is that only a small volume of blood can be surveyed, so that a light infection could be missed.
- If the smears are prepared from anticoagulated blood, which is more than an hour old, the morphology of both parasites and infected RBCs may not be typical.
- After drying, the smear is stained with Giemsa or Leishman stain.
- For **Giemsa stain**, the smear is fixed in methanol for 3–5 minutes. After drying, Giemsa stain, diluted 1 drop in 1 mL of buffered water, pH 7–7.2, is applied for 30–45 minutes. The slide is then flushed gently with tap water, dried and examined under the oil immersion objective. The *cytoplasm* of malarial parasites is stained *blue* and the *chromatin dot* is stained *red*.
- For **Leishman's stain**, prior fixation is not necessary as the stain is an alcoholic solution, which fixes as it stains. Leishman stain is applied for 1–2 minutes and diluted with twice its volume of buffered water, pH 7–7.2 and is kept for 10–15 minutes. The smear is then dried and examined.

Reporting of thin blood films:

- In malignant tertian malaria, only the ring stage and gametocytes are seen in peripheral smear, while in benign tertian malaria, all stages of schizogony and gametocytes can be seen.
- Thin smear examination enables the appreciation of changes in the erythrocytes, such as enlargement, alteration of shape, fimbriation, red cells stippling (*Schuffner's dots*) as seen with *P. vivax*, and irregular stippling (*Maurer's clefts*), as seen in mature *P. falciparum* trophozoites.
- Any marked increase in white cell numbers and if indicated perform a differential white cell count.
- Parasitized erythrocytes are seen most often in the upper and lower margins of the tail of the smear.
- Count the percentage of parasitized red cells, when there is high *falciparum* malaria parasitemia (+++ or more parasites seen in the thick film) to monitor a patient's response to treatment.
- A minimum of 100 fields should be examined before a negative report is given.

Thick smear:

- Thick smears have the advantage that a larger quantity of blood can be tested. Increased volume of blood present on thick film may allow the malaria parasite to be detected even with low parasitemia. Compared with a thin film, a thick film is about **30 times** more sensitive and can detect about **20 parasites/ μL of blood**.
- The disadvantages are that the red cells are lysed and the morphology of the parasites is distorted, so that species identification becomes difficult.

- A big drop of blood (20–30 μL) from finger or heel prick is collected on a clean grease-free slide and spread with the corner of another clean slide to form a uniformly thick smear of about 1 cm^2 . The thickness of the smear should be such that the hands of a wristwatch can be seen through it, but not the figures on the dial.
- The smear is dried in a horizontal position, kept covered from dust.
- Thick smears have to be dehemoglobinized before staining.
- They can be stained with **Giemsa or Leishman's stains** as described earlier. Wright's stain and JSB stain (so called because it was devised by Jaswant Singh and Bhattacharjee, in 1944) are very useful for staining large numbers of thick films as in malaria surveys.

Wright's stain consists of two solutions:

1. Solution A contains methylene blue and azure B in phosphate buffer.
2. Solution B contains eosin in phosphate buffer. The film is immersed in solution A for 5 seconds, washed in tap water, immersed in solution B for 5 seconds, washed, dried and examined. Staining times may need adjustment. If the smear is too blue, stain longer in solution B; if too pink, in solution A.

Jaswant Singh and Bhattacharjee stain also consists of two solutions:

1. The first contains methylene blue, potassium dichromate, sulfuric acid, potassium hydroxide and water.
2. The second solution is aqueous eosin.

For staining, the smear is immersed in solution 1 for 10 seconds, washed for 2 seconds in acidulated water pH 6.2–6.6, stained in solution 2 for 1 second, washed in acidulated water, immersed again in solution 1 and washed.

Reporting of thick blood films:

- Select an area that is well-stained and not too thick.
- Examine for malaria parasites and malaria pigment under oil immersion objective (100X).
- Examine at least 100 high-power microscope fields for parasites.
- Report the approximate number of parasites (trophozoites, schizonts and gametocytes) and also whether malaria pigment is present in white cells or not.
- The plus sign scheme that can be used to report parasite numbers are described in **Box 4**.

Box 4: Plus sign scheme for reporting parasite numbers

- 1–10 per 100 high-power fields: +
- 11–10 per 100 high-power fields: ++
- 1–10 in every high-power field: +++
- More than 10 in every high-power field: ++++

Combined thick and thin blood films:

- Combined thick and thin smears can be taken on the same slide.
- Draw a thick line with a glass-marking pencil on a slide, dividing it into two unequal parts. The thick smear is made on the smaller part and the thin smear drawn on the larger.
- Thick smear is first dehemoglobinized and the two are then stained together. An easy method is to add undiluted Leishman stain over the thin smear, and then the diluted stain flooded over to the thick smear also.
- Do not allow the methanol to contact the thick film when fixing the thin film.
- The stained thin smear is examined first. If the thin smear is negative, the thick smear should be searched for parasites.
- When a slide is positive for malarial parasites, the report should indicate the species, the developmental stages found and the density of parasites in the smear.

Examination for Microfilaria

Microfilariae may be detected in peripheral blood, both in unstained mounts and in stained smear (**Table 1 and Box 5**).

Wet Mount

- Two or three drops of blood are collected on a clean glass slide and mixed with two drops of water to lyse the red cells.
- The preparation is covered with a coverslip and sealed.
- The preparation is examined under the low-power microscope for the motile microfilariae, which can be seen **wriggling** about, **swirling** the blood cells in their neighborhood.

Table 1: Parasites found in peripheral blood film

Protozoa	Nematodes
• <i>Plasmodium</i> spp.	• <i>Wuchereria bancrofti</i>
• <i>Babesia</i> spp.	• <i>Brugia</i> spp.
• <i>Leishmania</i> spp.	• <i>Loa loa</i>
• <i>Trypanosoma</i> spp.	• <i>Mansonella ozzardi</i>

Box 5: Time of collection

In case of nocturnal periodic microfilariae, blood should be collected between 10 PM and 2 AM. In subperiodic nocturnal infection, the time of collection of blood should be between 8 PM and 10 PM and for subperiodic diurnal infection the time of collection should be ideally between 2 PM and 6 PM.

- The examination may conveniently be deferred till next morning, as microfilariae retain their viability and motility for 1 or 2 days at room temperature.
- By using a simple counting chamber, microfilariae in the wet mount can be *counted*.

Stained Smears

- A thick smear is prepared as for malaria, dehemoglobinized, and stained with Leishman's, Giemsa, or Delafield's hematoxylin stains.
- Stained smears have the advantage that the **morphology** of microfilariae can be studied and **species identification** can be made. Thus, for differentiation between *Mf. bancrofti* and *Mf. malayi* stained smears are necessary.
- Sometimes, microfilariae may be seen in thin smears also.
- By using a measured quantity of blood for preparing smears, as for example with a 20 cubic mm pipette and counting the total number of microfilariae in the smear, microfilaria counts can be obtained. Multiplying the number of microfilariae in a 20 cubic mm smear by 50 gives the count per mL of blood.

Concentration Methods

These methods have been developed to recover low numbers of microfilariae from blood and employ venous blood.

- **Sedimentation method:**
 - In sedimentation method, the sample of blood is first lysed with acetic acid, saponin, or other lytic substance, or by freeze-thawing, and then centrifuged.
 - The sediment is stained and the microfilariae are counted.
- **Membrane filtration concentration:**
 - In membrane filtration method, a measured quantity (1–5 mL) of blood is collected into an anticoagulant solution and passed through membrane filters fixed on syringes with Swinney filter holder. Blood cells and proteins sticking on to the filter are washed away by repeatedly passing saline through it.
 - The filter is removed, placed on a slide, stained with dilute Giemsa stain and examined under low-power microscope for microfilariae.
 - **Millipore** and **nucleopore membrane filters** (5 μm porosity) are available for this purpose; the latter being more sensitive, as it can screen larger volumes of blood.
 - Membrane filtration recovers most species of microfilariae; however, because of their small size, *Mansonella perstans* and *M. ozzardi* may not be recovered. Membranes with smaller pores (3 μm) have been suggested to recover these two species.

- The membrane filter method is much more sensitive than the finger prick method as the blood samples are taken during day, it also give reliable results even with nocturnal periodic microfilariae.
- However, the method has the disadvantages that venipuncture is necessary, membranes are costly, and microfilariae may not be in a satisfactory condition for detailed morphological study.
- The number of microfilariae counted divided by 10 gives the number of microfilariae per mL of blood.
- This is the most sensitive method of detecting small numbers of microfilariae, but it is expensive for routine use.

- **Microhematocrit tube method:**

- Capillary blood is collected in two heparinized capillary tubes or about 100 μL is first collected into EDTA anticoagulant, and then transferred to plain capillary tubes.
- The blood is centrifuged in a microhematocrit centrifuge.
- The **buffy coat** is examined microscopically for motile microfilariae.
- In areas where the species is known and *Mansonella* microfilariae are not found, this is a rapid technique for detecting microfilariae.

- **Buffy coat blood film:**

- The buffy coat containing white blood cells (WBCs) and platelets obtained after centrifugation of whole anticoagulated blood and the layer of RBCs just below the buffy coat layer, can be used to prepared thick and thin blood films in suspected infections with filaria, *Leishmania*, *Trypanosoma* and malaria. The sensitivity of this method is much higher than that of routine thick film.

Diethylcarbamazine Provocation Test

Oral administration of diethylcarbamazine (**DEC**; 100 mg or 2 mg/kg of body weight) brings about mobilization of microfilariae into peripheral blood. Blood collected 20–50 minutes after the drug is given, will show microfilariae so that blood collection can be done during day time. This is a great advantage for surveys. But the drug may cause febrile reactions, particularly in brugianis. It cannot be used in areas endemic for onchocerciasis because of the danger of provoking severe reactions.

■ SPUTUM EXAMINATION

Sputum is examined commonly for the demonstration of eggs of *Paragonimus westermani*, and sometimes for detection of trophozoites of *E. histolytica* in amebic pulmonary abscess. Rarely, the larval stages of hookworm, *A. lumbricoides*, or

Box 6: Parasites found in sputum

- *Paragonimus westermani*
- *Entamoeba histolytica* (trophozoites in case of pulmonary abscess)
- *Pneumocystis jirovecii*
- Rarely migrating larvae of *Ascaris lumbricoides*
- Rarely migrating larvae of *Strongyloides stercoralis*
- Rarely migrating larvae of *Ancylostoma duodenale*
- Rarely migrating larvae of *Necator americanus*.

S. stercoralis or the cestode hooklets may be seen in sputum samples (**Box 6**).

- Concentrated stained preparations of induced sputum are commonly used to detect *P. jirovecii* and differentiate trophozoite and cyst forms from other possible causes of pneumonia, particularly in an acquired immunodeficiency syndrome (AIDS) patient.
- Normally, direct saline mount preparation is done for microscopy.
- If the sputum is thick, equal volume of 3% N-acetyl cysteine or 3% sodium hydroxide is added to the sputum to liquefy the specimen and after centrifugation, the sediment is examined for microscopic examination under low (10X) and high (40X) power magnifications.
- In a *Paragonimus* spp. infection, the sputum may be viscous and tinged with brownish flecks, which are clusters of eggs (**iron filings**) and may be streaked with blood.

■ URINE OR BODY FLUIDS EXAMINATION

- Large volume of urine samples should be allowed to settle for 1–2 hours.
- About 50 mL of the bottom sediment of the sample is taken for centrifugation.
- The highly concentrated sediment after centrifugation is examined for direct wet mount microscopy.
- May show eggs of *Schistosoma* and *Trichomonas vaginalis*. Microfilaria may be detected from chylous urine in lymphatic filariasis.

■ TISSUE BIOPSY

Tissue biopsies and fine-needle aspirations are taken from cutaneous ulcers of trypanosomiasis or leishmaniasis and from skin nodules of onchocerciasis and post-kala-azar dermal leishmaniasis (PKDL).

- A **skin snip** can be obtained to diagnose subcutaneous filariasis or leishmaniasis by grasping with a forceps or elevating a portion of skin with the tip of needle. Tip of the small cone of the skin is, then sliced with a sharp blade or razor.

- Wet mount preparation of lymph node aspirate and chancre fluid are used as rapid methods for demonstration of trypanosomes.
- Biopsies from liver, spleen, bone marrow and lymph nodes are taken in visceral leishmaniasis for demonstration of Leishman-Donovan (LD) bodies.
- All biopsy tissues must be submitted to the laboratory without the addition of formalin fixative. If there is delay in transport or processing, the specimen should be placed in polyvinyl alcohol fixative. In soft specimens, a small part should be scraped and examined as direct saline wet mount.
- **Impression smears** can be made from freshly cut tissue specimens on a glass slide and examined after fixation with Schaudinn's solution. Trichrome or other stains can be used.
- The residual part of the biopsy specimen may be processed for histopathological examination.
- Adult filarial worms can sometimes be found in section of biopsied lymph node.
- Corneal scrapings are useful in diagnosis of acanthamoeba keratitis.

■ MUSCLE BIOPSY

Spiral larval form of *Trichinella spiralis*, larval form of *T. solium* (*cysticercus cellulosae*) and amastigote of *Trypanosoma cruzi* can be demonstrated in skeletal muscle biopsy. In trichinosis, muscle biopsy (gastrocnemius, deltoid and biceps) specimen must be examined by compressing the tissue between two slides and checking the preparation under low-power (10X) objective. This method does not become positive until 2–3 weeks after the illness.

■ DUODENAL CAPSULE TECHNIQUE (ENTEROTEST)

Enterotest is a simple method of sampling duodenal contents.

- The device is composed of a length of nylon yarn-coiled inside a **gelatin capsule**.
- The end of the yarn is affixed to the patient's face.
- The capsule is then swallowed and the gelatin dissolves in the stomach.
- The weighted string is carried into the duodenum by peristalsis.
- Bile-stained mucus is then retrieved after 3–4 hours and duodenal contents adherent to the yarn is scrapped off and examined under microscope as wet mount or as stained smear after preservation in formalin or polyvinyl alcohol.
- Usually 4–5 drops of material is obtained.

- Enterotest is used for detecting trophozoites of *Giardia*, larvae of *Strongyloides*, eggs of liver flukes and oocysts of *Isospora*.

■ SIGMOIDOSCOPY MATERIAL

Material obtained from sigmoidoscopy is useful in the diagnosis of *E. histolytica* that cannot be diagnosed by routine examination for at least 3 days.

- Material from the intestinal mucosa should be aspirated or scraped and not to be collected by cotton swabs.
- The material should be processed immediately.
- In heavy infection of *Trichuris*, sigmoidoscopy may show white bodies of the worms hanging from the inflamed mucosa of large intestine.

■ UROGENITAL SPECIMEN

The detection of *T. vaginalis* is usually based on wet preparation of vaginal and urethral discharges and prostatic specimens. Specimens should be collected in small volume of 0.85% saline and should be sent immediately for detection of actively motile organisms, as the jerky movements of *Trichomonas* begin to diminish with time.

■ CULTURE METHODS

Many parasites can now be grown in culture, but this has not become a routine diagnostic method in parasitic infections (**Box 7**). It is sometimes employed for accurate identification of the parasite species. It is more often employed for obtaining large yields of the parasite as a source of antigen, animal inoculation, drug-sensitivity testing, experimental or physiological studies and teaching purposes. Some of the culture methods used for different parasites are indicated here.

Ameba

E. histolytica and other intestinal amebae can be grown in diphasic or monophasic media, media containing other microorganisms, or axenic cultures.

- **Boeck and Drbohlav diphasic medium**, the classical culture medium for ameba has been modified by various workers (**Box 8**).
 - The medium as used now, is basically an egg slant, with an overlay of sterile serum or liver extract in buffered saline.
 - A loopful of sterile rice powder is added to the medium just before inoculation with fresh feces or its saline centrifugal sediment.
 - Cultures can be obtained from feces-containing cysts or trophozoites.

Box 7: Parasites which can be cultured in the laboratory

- *Entamoeba histolytica*
- *Giardia lamblia*
- *Trichomonas vaginalis*
- *Leishmania* spp.
- *Trypanosoma* spp.
- *Acanthamoeba* spp.
- *Naegleria fowleri*
- *Balantidium coli*
- *Plasmodium* spp.

Box 8: Composition of Boeck and Drbohlav medium (Locke's solution)

- Sodium chloride: 9 g
- Potassium chloride: 0.4 g
- Calcium chloride: 0.2 g
- Sodium bicarbonate: 0.2 g
- Glucose: 2.5 g
- Distilled water: 1000 mL
- Egg: Four (clean and washed)

Box 9: Composition of Balamuth's medium

- Liver concentrate powder: 1 part
- Egg yolk medium: 9 part
- Phosphate buffer
- Tribasic potassium phosphate: 212 g
- Monobasic potassium: 136 g
- Distilled water

- The cultures are incubated at 37°C and subcultured at 48-hour intervals.
- Amebae can be demonstrated in the liquid phase in unstained mounts or stained smears.
- **Balamuth's monophasic liquid medium** is also used commonly for cultivation of amebae and other intestinal protozoa. This is an egg yolk-liver extract infusion medium (**Box 9**).
 - Both protozoa and bacteria present in stools grow in the earlier media.
 - Bacterial growth can be reduced by addition of penicillin or other antibiotics that do not inhibit protozoa.
 - Axenic cultures (pure cultures without bacteria or other microorganisms) were first developed by Diamond in 1961. Axenic cultivation has enabled precise antigenic and biochemical studies on amebae.
 - *B. coli* grows well in Balamuth's medium. *G. lamblia* had been established in association with *Candida*

and *Saccharomyces*, but axenic cultures were developed in 1970.

- *T. vaginalis* grows very well in several commercially available media such as trypticase serum media.
- *Naegleria* and *Acanthamoeba* from cerebrospinal fluid (CSF) can be grown on agar plates heavily seeded with *Escherichia coli*.

Leishmania and Trypanosomes

- **Novy-MacNeal-Nicolle medium:** The classical *Novy-MacNeal-Nicolle (NNN) medium* first described in 1904 for cultivation of *Leishmania*, is equally satisfactory for trypanosomes also. This is a defibrinated rabbit blood agar medium (**Box 10**). Several modifications of this medium have been introduced.
 - Two bottles of culture are aseptically inoculated with 0.1 mL of specimen in each and incubated at 24°C for 4 weeks.
 - The primary culture is examined every 4 days for promastigotes in leishmaniasis and for epimastigote stages in trypanosomiasis for up to 30 days.
- **Schneider's insect tissue culture medium:** It is recommended *in vitro* culture of *Leishmania*. This medium is said to be more sensitive than NNN medium (**Box 11**).

Malaria Parasites

- Cultivation of malaria parasites was first obtained by Bass and Jones in 1912. A simple method of cultivation is as follows:
 - About 10–12 mL of defibrinated or heparinized blood rich in ring forms of malaria parasite, mixed with 0.2 mL of 50% dextrose solution are incubated at 37°C in a sterile test tube in an upright position.
 - The blood separates into the erythrocytes below, plasma above and the buffy coat in between.
 - Malaria parasites grow in the erythrocyte layer immediately below the buffy coat.
 - Smears are collected from this layer at intervals, without tilting the tube.

Box 10: Composition of Novy-MacNeal-Nicolle (NNN) medium

- Bactoagar (Difco): 1.4 g
- Sodium chloride: 0.6 g
- Double distilled water: 90 mL
- Defibrinated rabbit blood (10%): 10 mL.

Box 11: Composition of Schneider's insect tissue culture medium

- Schneider's *Drosophila* tissue culture medium: 80 mL
- Fetal calf serum: 20 mL
- Antibiotic-antimycotic solution: 1.2 mL.

- Segmented schizonts are usually observed after incubation for 24–36 hours.
- The breakthrough in cultivation of malarial parasites came in 1976 when Trager and Jensen successfully maintained *P. falciparum* in continuous cultures in human erythrocytes using Roswell Park Memorial Institute (RPMI) 1640 medium.
 - The cultures are incubated at 38°C with 10% human serum at pH 6.8–7.2 under an atmosphere with 7% carbon dioxide and 1–5% oxygen.
 - A continuous flow system is used in which the medium flows slowly and continuously over the layer of erythrocytes. The method has been applied to various species of *Plasmodia*.
 - It has been employed for preparation of antigens, drug-sensitivity studies, vaccine tests and many other purposes.

ANIMAL INOCULATION

Animal inoculation is not a routine diagnostic procedure in parasitic infections, but can be used in some instances because of its sensitivity.

- **Toxoplasmosis:** Animal inoculation can be used for isolating *Toxoplasma gondii* from infected persons. Lymph node or other biopsy materials are inoculated intraperitoneally into immunosuppressed mice. Peritoneal fluid obtained 7–10 days later, may show the parasite in Giemsa-stained smears. However, serial passages may be necessary for its isolation. Brain smears may be examined for cysts after sacrificing the mice 3–4 weeks after inoculation. Seroconversion of the animal inoculation also indicates a positive result.
- **Visceral leishmaniasis:** Bone marrow, liver, spleen, or lymph node aspirates from kala-azar patients, injected intraperitoneally into hamsters is a very sensitive method for diagnosing visceral leishmaniasis. Even a single amastigote can establish the infection in the animal. Spleen smears taken 4–6 weeks later show *Leishmania donovani* (LD) bodies.
- **Trypanosomiasis:** Blood from patients with trypanosomiasis can be injected intraperitoneally or into the tail vein of mice, rats and guinea pigs, etc. These animals are susceptible to infection by *T. brucei rhodesiense*. Parasitemia can be demonstrated in 2 weeks.

XENODIAGNOSIS

This method involves the diagnostic infection of a vector, in which the parasite multiplies and can be demonstrated. In *T. cruzi*, diagnosis may be established by letting the vector **reduviid bug** feed on suspected patients. In 4–5 weeks, live flagellate forms can be seen in the feces of the bugs.

■ IMMUNOLOGICAL DIAGNOSIS

Serology

Several serological tests have been developed for detection of antibodies to parasites using antigens from cultured parasites or from natural or experimental infections in animals or humans. In some cases, antigens are obtained from related parasites or even sometimes from bacteria. Advances in cultivation of parasites have made parasitic antigens more readily available. Cloning of parasitic antigens promises to be a new source.

In some instances, diagnosis is attempted by serological demonstration of parasitic antigens in blood, tissues, or secretions of suspected patients.

Virtually, all types of serological reactions have been used. However, serodiagnosis in parasitic infections has only limited value due to various factors:

- Parasites are complex antigenically and exhibit wide range of cross-reactions, so that serological tests are not sufficiently specific.
- Another difficulty is in distinguishing between past and current infections. This has been solved partly by looking for immunoglobulin M (IgM) antibody, as in amebiasis and toxoplasmosis.
- In general, indirect hemagglutination (IHA), enzyme-linked immunosorbent assay (ELISA) and counter-immunoelectrophoresis (CIEP) are most sensitive; indirect immunofluorescence (IF), direct agglutination test (DAT) and complement fixation test (CFT) are moderately sensitive; and simple precipitation in gel and coated particle agglutination tests are least sensitive. Serology has not been very useful in the diagnosis of individual cases, but has been valuable as a screening method in epidemiological surveys. However, in some infections where parasites are seldom demonstrable in patients, for example in toxoplasmosis and hydatidosis, serology is of great help. Listed here are some of the applications of serology.

Amebiasis

Serology is of no value in the diagnosis of acute amebic dysentery or luminal amebiasis. But in invasive amebiasis, particularly in liver abscess, serology is very useful.

- *Indirect hemagglutination is most widely employed.* Titers of 1:256 or more are significant in cases of amebic liver abscess and have prognostic value.
- **Tech Lab E. histolytica** test was able to detect galactose lectin (*GalNAc*) antigen in almost all patients of amebic liver abscess.

Giardiasis

Enzyme-linked immunosorbent assay and *indirect immunofluorescence (IIF) test* have been developed for detection of *Giardia*.

- Commercially available ELISA (**ProSpec T/Giardia**) kit detects *Giardia-specific antigen 65 (GSA 65)*. The sensitivity of the test is 95% and specificity is 100%, when compared to conventional microscopy.

Trypanosomiasis

Serological tests used to detect trypanosomiasis are *IHA*, *indirect fluorescent antibody (IFA)* and *ELISA*.

- Specific antibodies are detected by these tests in the serum within 2–3 weeks infection.
- Specific antibodies can be demonstrated by *IFA* and *ELISA* in *CSF*.

Leishmaniasis

Indirect hemagglutination, *CIEP* and *DOT-ELISA* are usually positive in kala-azar.

- *Complement test using Witebsky, Klingenstein and Kuhn (WKK) antigen* from the acid-fast Kedrowsky bacillus are relatively less sensitive.
- Indirect fluorescent antibody test is positive very early in the disease, even before the appearance of symptoms and becomes negative within 6 months of cure.
- **rK39 micro ELISA test** is a qualitative immunochromatographic assay for detection of antibodies to *Leishmania*.

Malaria

Indirect immunofluorescence, *ELISA* and *IHA* are sensitive and specific, but are not useful for diagnosis of acute malaria because antibodies persist for some years after cure.

- A negative test may, however help to exclude malaria.
- Serological tests are useful in epidemiological surveys for malaria.
- Molecular assays such as antigen capture for detection of *histidine-rich protein II (HRP-2)* and *Plasmodium lactate dehydrogenase (pLDH)* have been applied for developing rapid dipstick tests (e.g. ParaSight-F in malignant tertian malaria).

Toxoplasmosis

Serological tests offer the most useful diagnostic method in toxoplasmosis.

- The original **Sabin-Feldman dye test**, though very specific and sensitive, is no longer in use. *IIF*, *IHA* and *CFT* were

other useful tests. The dye test remains positive for life, while CFT becomes negative soon after active infection.

- At present, *ELISA* is routinely used in *Toxoplasma* serology. It is very informative, as it provides titers of IgM and IgG antibodies separately for better interpretation of the results.

Cryptosporidiosis

Indirect fluorescent antibody and *ELISA* using purified oocysts as antigens have been used to detect circulating antibodies specific to *Cryptosporidium parvum*.

Intestinal Helminths

Antibodies can be demonstrated in most intestinal helminthiases, but extensive cross-reactions limit their use in diagnosis.

Trichinosis

Serology is very useful in diagnosis of trichinosis. *Bentonite flocculation slide tests* and *CFT* become positive 3–4 weeks after infection.

- *Indirect immunofluorescence* becomes positive even earlier.
- *Enzyme-linked immunosorbent assay* is also available. Demonstration of seroconversion is diagnostic.

Toxocariasis

High titers in serological tests are obtained in visceral larva migrans, but specificity is low due to cross-reactions with intestinal nematode antigens.

Filariasis

Indirect hemagglutination and *bentonite flocculation tests* with antigen from *Dirofilaria immitis* gives positive reaction in patients, and high titers in tropical pulmonary eosinophilia. But cross-reactions are frequent.

Immunochromatographic card test (ICT) is a new and rapid filarial antigen test that detects soluble *Wuchereria bancrofti* antigens in the serum of infected humans.

Echinococcosis

Several serological tests have been developed using hydatid fluid or scolex antigens from hydatid cysts in sheep. *IHA*, *IIF*, *CIEP* and *ELISA* are very sensitive. Cross-reactions occur with cysticercosis.

■ SKIN TESTS

Intradermal tests have been used in many parasitic infections. They are sensitive and persist for many years, sometimes even for life. But specificity is relatively low.

- *Casoni's test*: This test had been used widely in the diagnosis of hydatid disease since its original description in 1911. The antigen is sterile hydatid fluid drawn from hydatid cysts from cattle, sheep, pig, or humans, filtered and tested for sterility. Intradermal injection of 0.2 mL of the antigen induces a wheal and flare reaction within 20 minutes in positive cases. A saline control is used. False-positive tests are seen in schistosomiasis and some other conditions. Casoni's test is now largely replaced by serological tests.
- *Leishmanin (Montenegro) test*: This test is used to measure delayed hypersensitivity. *Leishmania* test is sensitive and relatively specific. The antigen is obtained from cultured *Leishmania* and consists of killed promastigotes in phenol saline. Intradermal injection of 0.1 mL induces a papule of 5 mm or more in diameter in 48–72 hours. This delayed hypersensitivity test is positive in cutaneous leishmaniasis and negative in diffuse cutaneous and visceral leishmaniasis.
- *Fairley's test*: This skin test is group-specific and gives positive results in all schistosomiasis. The intradermal allergic test uses antigen infected snails, cercariae, eggs and adult schistosomes from experimentally infected laboratory animals.
- *Skin test in Bancroftian filariasis*: Intradermal injection of filarial antigens (extracts of microfilariae, adult worms and third-stage larvae of *Brugia malayi*, or the dog filaria, *Dirofilaria immitis*) induce an immediate hypersensitivity reaction, but the diagnostic value of the skin test is very limited due to the high rate of false-positive and negative reactions.

■ MOLECULAR METHODS

Nucleic acid-based diagnostic tests are mainly available in specialized or reference centers. Nucleic acid probes and amplification techniques such as polymerase chain reaction (**PCR**) and multiplex PCR, western blot and deoxyribonucleic acid (**DNA**) **hybridization** techniques are increasingly used to detect parasites in specimens of blood, stool, or tissue from patients.

- These test are useful for detecting subspecies or stain level identification which is important for epidemiological studies and are also used to detect parasitic drug resistance. For example, specific 17 kDa and 27 kDa

sporozoite antigens are employed for seroepidemiological studies in cryptosporidiosis using western blot technique.

- Deoxyribonucleic acid probe is a highly sensitive method for the diagnosis of malaria. It can detect even less than 10 parasite/ μ L of blood.
- **B₁ gene** of *T. gondii* can be detected by PCR of the amniotic fluid in case of congenital toxoplasmosis. PCR have been developed for detection of filarial DNA from patients blood. If parasite cannot be identified by microscopy, amplification of babesial 18S ribonucleic acid (RNA) by PCR is recommended.
- **Drug resistances** in malaria are detected now by PCR techniques. PCR is increasingly used now for species specification and for detection of drug resistance in malaria. Chloroquine resistance in *P. falciparum* has been attributed to mutation in the *Plasmodium falciparum* chloroquine resistance transporter (PfCRT), a transporter gene in the parasite. Point mutation in another gene *Plasmodium falciparum* multidrug resistance protein 1 (PfMDR1) has also been implicated in determining resistance *in vitro*. Pyrimethamine and sulfadoxine resistances are associated with point mutations in dihydrofolate reductase (DHFR) and dihydropteroate synthase (DHPS) genes respectively. Mutation in PfATPase gene is associated with reduced susceptibility to artemisinin derivatives.

REVIEW QUESTIONS

1. Enumerate the various methods employed for examination of stools and describe in detail the concentration methods of stool examination.
2. Describe various skin tests used for diagnosis in many parasitic infections.

3. Write short notes on:

- a. Scotch tape method
- b. Blood examination for malarial parasite
- c. Blood examination for microfilaria
- d. Enterotest
- e. Casoni's test
- f. Floatation method of stool examination

MULTIPLE CHOICE QUESTIONS

1. Time of collection of blood is important in
 - a. Microfilaria
 - b. *Trypanosoma* spp.
 - c. *Leishmania* spp.
 - d. *Babesia* spp.
2. Modified acid-fast stain is used for the diagnosis of
 - a. *Entamoeba histolytica*
 - b. *Toxoplasma gondii*
 - c. *Cryptosporidium parvum*
 - d. *Leishmania donovani*
3. Sputum examination is commonly done for detecting the eggs of
 - a. *Strongyloides stercoralis*
 - b. *Entamoeba histolytica*
 - c. *Paragonimus westermani*
 - d. *Ascaris lumbricoides*
4. Larval forms of which parasite can be found in muscle biopsy
 - a. *Ascaris lumbricoides*
 - b. *Taenia solium*
 - c. *Trichuris trichiura*
 - d. *Ancylostoma duodenale*

Answer

1. a 2. c 3. c 4. b

Page numbers followed by *b* refer to box, *f* refer to figure, *fc* refer to flow chart and *t* refer to table

- A**
- Abscess, splenic 19
 - Acanthamoeba* 12, 13, 15, 26, 28, 29*t*, 231, 233, 244
 - culbertsoni*, life cycle of 29*f*
 - keratitis 29, 30
 - Acanthocheilonema 223
 - Acanthopodia 28
 - Accidental host 2, 121
 - Acephalocysts 133
 - Acetabulum 141
 - Acid-fast
 - parasitic organisms 105*b*
 - stain 100*f*, 236
 - Acidosis, metabolic 79
 - Acquired immunodeficiency syndrome 5, 13, 29, 93, 104, 184, 243
 - Adenolymphangitis, acute 214
 - Adenophorea 166
 - Adoral cilia 107
 - Adult *Trichuris trichiura* worms 176*f*
 - Adult worm 112, 144, 151, 154, 156, 160, 170, 175, 180, 181, 198, 203
 - African trypanosomiasis 42, 46
 - Agar plate culture 239
 - Albendazole 128, 135
 - Alimentary canal, amebae of 13
 - Alphonse Laveran 67
 - Amastigote 42, 48, 48*f*, 53, 54*f*
 - Ameba 244
 - classification of 15*t*
 - drug sensitivity of 23
 - Amebapores 18
 - Amebiasis 20*fc*, 246
 - cutaneous 19, 21
 - genitourinary 19, 21
 - hepatic 20
 - lesions of 22*f*
 - metastatic 21
 - pulmonary 19, 21
 - Amebic
 - antigen detection 23
 - appendicitis 19
 - colitis 24
 - cysteine proteases 18
 - dysentery 13, 15, 19, 20
 - encephalitis, granulomatous 26, 29
 - granuloma 30
 - hepatitis 19, 20
 - keratitis 26, 29
 - lectin 18
 - liver abscess 13, 15, 19, 20*f*, 21, 21*fc*, 24
 - meningoencephalitis 13, 26-29
 - ulcer 18, 19*f*
 - flask-shaped 19*f*
 - Amebida 12
 - Ameboflagellate 27
 - Ameboma 19, 30
 - Amebostomes 27
 - American trypanosomiasis 47
 - American visceral leishmaniasis 56
 - Amoeboflagellate 39
 - Amphotericin B 28, 61
 - Ampulla of Vater 155
 - Ancylostoma* 6, 140, 165, 189
 - braziliense* 165, 167
 - caninum* 167
 - ceylanicum* 193
 - duodenale* 3, 7, 165, 176, 180, 187-189, 192, 194, 207, 229, 243
 - adult worm of 188*f*
 - egg of 189*f*
 - life cycle of 190*f*
 - Anemia 46, 57
 - causes of 56*b*, 78*b*, 192*b*
 - dimorphic 192
 - severe 56, 87
 - Angiostrongyliasis, abdominal 231
 - Angiostrongylus cantonensis* 167, 230-233
 - Animal inoculation 8, 47, 50, 59, 94, 245
 - Anisakiasis 232, 233
 - Anisakis simplex 167, 232
 - Anodic antigen, circulating 147
 - Anopheles barbirostris* 210, 219
 - Anthroponotic urban type 62
 - Anthropozoonoses 2
 - Antiamebic drugs 24*t*
 - Antibody
 - demonstration of 217
 - detection 7, 23, 35, 51, 60, 95, 128, 147
 - Antigen 7
 - detection 7, 35, 47, 51, 59, 95, 128, 135, 146
 - tests, rapid 83
 - Anti-oocyst antibody 100
 - Aposporoblastina 12
 - Aphasmidia 165
 - Apicomplexa*, phylum 66, 66*t*
 - Appendicitis 178
 - Artemisinin-based combination therapy 84
 - Ascariasis, ectopic 205
 - Ascaris* 6, 8, 140, 207
 - eggs, types of 202*f*
 - fertilized egg of 202*f*
 - lumbricoides* 3, 7, 112, 165, 167, 176, 180, 189, 194, 199-201, 201*f*, 204, 206*fc*, 207, 243, 248
 - life cycle of 204*f*
 - pneumonia 203
 - suum* 167
 - unfertilized egg of 202*f*
- Ascites 57
- Aspirates, splenic 58
- Aspiration 135, 135*b*
 - biopsies 59
- Atovaquone 88
- Autoimmune hemolysis 56
- Axoneme 41, 42, 53
- Azithromycin 88
- B**
- Babesia* 4, 12, 66
 - bovis* 86
 - microti* 13, 86, 86*f*
 - Babesiosis 87, 87*t*
 - Bachman intradermal test 174
 - Bacillary dysentery 20, 20*t*
 - Bacterial infection, secondary 227
 - Baermann concentration method 238, 238*f*
 - Balamuth's medium 23
 - composition of 244*b*
 - Balamuth's monophasic liquid medium 244
 - Balamuthia* 26
 - mandrillaris* 15, 30
 - Balantidiasis 109
 - Balantidium* 12, 109
 - coli* 3, 7, 11, 13, 14, 39, 107, 107*f*, 109, 150, 244
 - life cycle of 108*f*
 - Bancroftian filariasis 213, 247
 - Basal body 10
 - Basophilic stippling 73
 - Baylisascaris* 207
 - procyonis* 167
 - Bell's dilution-filtration count 238
 - Bentonite flocculation tests 247
 - Benznidazole 51
 - Bile
 - duct carcinoma 145
 - staining 123
 - Bilharziasis 143
 - Biliary
 - cirrhosis 156
 - obstruction, acute 205
 - passage 152
 - tract 142, 154

- Binary fission 11, 16, 41
 Binucleate cyst 16*f*, 25*f*
 Biopsy 217
 Bithionol 153
 Blackwater fever 79
 Bladder
 carcinoma 145
 containing seeds 142
 worm 117, 123
Blastocystis hominis 101, 101*f*
 Blastomeres 188
 Blepharoplast 42, 53
 Blinding filaria 221
 Blister formation 227
 Blood 13, 142
 collection of 240
 examination 6, 135
 flake 141-143
 incubation infectivity test 47
 loss 178
 picture 87
 smear 82*b*
 transfusion malaria 80*t*
 urea nitrogen 88
 Boeck and Drbohlav diphasic medium 244, 244*b*
 Bone marrow 56
 aspirate 58
 macrophage of 13
 Bothriocephalus anemia 120
 Bradyzoites 91, 93, 102
 Brain 21, 104, 232
 parenchyma 128*f*
 Bronchi 161
Brugia malayi 4, 7, 165, 208, 210, 218, 219*f*, 224, 226
Brugia pahangi 167, 223
Brugia patei 167
Brugia timori 165, 208, 210, 219, 226
 Buffy coat blood film 242
Bunostomum phlebotomum 167
- C**
- Cachexia 57
 Calabar swellings 219, 221
 Calcofluor white staining 29
 Candidate vaccine 61
Capillaria aerophila 161
Capillaria philippinensis 4, 165, 180, 231, 232
 Card agglutination trypanosomiasis test 46, 47
 Cardiac implantable electronic device 133
 Cartwheel appearance 16
 Casoni's intradermal test 134
 Casoni's test 247
 Cat liver fluke 156
 Cathodic antigen, circulating 147
 Caudal papillae 166
 Cecum 18
 Cellular exudates 20, 235
 Cellulose acetate membrane precipitation test 23
 Central nervous system 13, 46, 129, 150, 171
 infection 232*t*
 Centrilobular necrosis 77
 Cercarial dermatitis 148
 Cerebral
 amebiasis 19
 angiostromyiasis 230
 malaria 79
 paragonimiasis 161
 Cerebrospinal fluid 6, 27-29, 45-47, 128, 230, 231, 245
 Cestodes 4, 112, 115
 classification of 115, 116*t*
 living 122*b*
 Chagas disease 13, 42, 47
 acute 49, 50
 chronic 50
 Chagas radioimmune precipitation assay 51
 Chagoma 50
 Chancre
 painless 45
 trypanosomal 45
 Charcot culture 240
 Charcot-Leyden crystals 19, 20, 22, 22*f*, 235
 Chemoprophylaxis 84, 85
 Chiclero's ulcer 53, 63
Chilomastix 12
 mesnili 32, 38
 egg of 38*f*
 Chinese liver fluke 154
 Chocolate brown sputum 21
 Cholangiocarcinoma 156
 Cholangitis 156
 Chopra's antimony test 60
 Chromatoid bodies 10, 16
 Chrysops 220, 221
 Chylous urine 215*f*
 Cilia 11
 Ciliophora 11, 12
 Cloaca 164
Clonorchis 113, 141, 207
 sinensis 4, 7, 143, 145, 151, 154, 172, 194, 201, 232
 egg of 154*f*
 life cycle of 155*f*
 Coccidia 12, 66, 90
 Coenurus 117, 129
 Colon 13, 18
 Complement fixation test 7, 46, 47, 58, 133, 135, 216, 246
 Complete blood count 205
 Congestive cardiac failure 87
 Conjunctiva 165
 Conjunctival biopsies 222
 Conjunctival epithelium 104
 Coproantigen, detection of 23
 Copulatory spicules 200
 Coracidium 118, 120
 Cornea 29, 104
 Corneal stroma 104
 Counter-current immunoelectrophoresis 23
 Craig's medium 22
 Creeping myiasis 167
 Crescentic tachyzoites 90*f*
 Crustacea 232
 Cruzin 51
 Cryptosporidiosis 247
Cryptosporidium 12, 14, 66, 100, 236
 parvum 3, 4, 7, 13, 10, 97, 99, 100, 105, 199, 204, 248
 life cycle of 99*f*
 oocysts of 98*f*, 100*f*
Ctenodactylus gundi 90
Culex quinquefasciatus 210, 213
 Culicoides 210, 223
 Cutaneous leishmaniasis, diffuse 53, 62
 Cyclophyllidean 117, 117*t*
 tapeworms 122
 Cyclops 118, 232
Cyclospora 66, 101, 236
 cayetanensis 3, 7, 39, 99, 100, 105
 Cylindrical esophagus 180
 Cyst 14, 16, 17, 26, 27, 29, 30, 39, 107, 107*f*
 fluid 134
 mature 96*f*
 uninucleate 16*f*
 Cysteine-peptone-liver-maltose 37
 Cysticerci in muscles 124*f*
 Cysticercosis 126, 128, 140
Cysticercus 117, 123
 bovis 123, 124*f*
 cellulosae 123, 124*f*
 cysts of 128*f*
 Cytoadherence 74
 Cytolysis 18
 Cytopharynx 107
 Cytoplasm 10, 16
 Cytopyge 107
 Cytostome 107
- D**
- Deoxyribonucleic acid 8, 21, 35, 47, 58, 83, 127, 133, 217, 247
 Dermatitis 184
 Diamond's axenic medium 23
 Diarrhea 13, 34*b*, 97
 bloody 150*b*
 Dichlorodiphenyltrichloroethane 85, 218
Dicrocoelium dendriticum 150, 153
Dientamoeba 12, 39
 fragilis 32, 39
 trophozoite of 39*f*

- Diethylcarbamazine 168, 215, 217, 222
 medicated salts 218
 provocation test 216, 242
- Dihydrofolate reductase 84, 248
- Dihydropteroate synthase 84, 248
- Dipetalonema 223
- Diphyllobothrium* 113, 115
latum 4, 7, 112, 116, 117, 118*f*, 122, 151,
 172, 232
 life cycle of 119*f*
- Dipylidium* 113, 115
caninum 7, 116, 139, 139*f*, 226
- Direct agglutination test 51, 58, 60, 246
- Direct fluorescent method 105
- Dirofilaria* 167
conjunctivae 224
immitis 161, 167, 223
repens 224
- Disseminated intravascular coagulation 87
- Distomata 141
- Doxycycline 218
- Dracunculiasis 227
- Dracunculus medinensis* 4, 164, 165, 225,
 226, 227*fc*, 229
 adult worm of 226*f*
 infection 225*f*
 larva of 226*f*
 life cycle of 228*f*
- Dumdum fever 52, 53
- Duodenal aspirates 97, 184, 205
- Duodenal capsule technique 243
- Duodenum 156
- Dysentery 13
- E**
- East African trypanosomiasis 45, 45*t*
- Echinococcosis 247
- Echinococcus* 8, 115, 117
granulosus 2, 4, 46, 116, 117, 129, 130*f*,
 133*fc*, 140, 161, 204, 226, 232
 life cycle of 131*f*
multilocularis 2, 116, 136, 226, 232
- Echinostoma* 113, 156, 159
- Echinostomatoidea 141
- Ectocyst 132
- Ectoparasite 1
- Ectopic infection 146, 167
- Ectoplasm 10
- Edema 46, 57
 painless 221
- Elephantiasis 210, 214, 215*f*
- Embryophore, inner 123
- Encephalitis 13
 granulomatosa 29
- Encephalitozoon* 12, 104
intestinalis 105
- Encephalopathy, diffuse symmetric 79
- Encysted larvae 165
- Endemic foci 160
- Endocyst 132
- Endodyogeny 11
- Endogony 91
- Endolimax nana* 15, 25, 26*f*
- Endoparasite 1
- Endoplasm 10
- Endoscopy 51
- Endospore 105
- Entamoeba* 6, 12
coli 15, 24, 25*f*
gingivalis 15, 25
hartmanni 15, 25
 trophozoite of 25*f*
histolytica 3, 6, 7, 10, 13, 15, 16*f*, 18*b*,
 21*fc*, 23*f*, 99, 105, 109, 150, 199,
 204, 234, 243, 244, 248
 life cycle of 17*f*, 17*fc*
polecki 15
- Enteric cycle 92
- Enterobius vermicularis* 3, 4, 6, 7, 39, 165,
 175, 176, 189, 195, 196, 196*fc*, 198*fc*,
 199, 207
 adult worm of 195*f*
 life cycle of 197*f*
- Enterocyte 105
- Enterocytozoon bienersi* 105
- Enteromonadina 12
- Enteromonas* 12
hominis 32, 38, 40
 cyst of 38*f*
- Enterotest 35
- Enzyme-linked immunosorbent assay 7,
 21, 23, 35, 46, 47, 51, 58, 83, 94, 95,
 127, 133, 147, 168, 173, 185, 205,
 206, 216, 217, 227, 246, 247
- Eosinophil count 215
- Eosinophilia 128, 178
 peripheral 185
- Eosinophils 5*f*
- Epilepsy, focal 133
- Epimastigotes 42, 43, 45, 48, 48*f*
- Erythematous patches 57*f*
- Erythrocyte
 mature 73
 sedimentation rate 46
 sequestration 79
 surface antigens, ring-infected 85
- Erythrocytic schizogony 68, 69, 76*f*, 240
- Escherichia coli* 29
- Esophagus, double bulb 181
- Espundia 63
- Ethylene diaminetetra-acetic acid 240
- Eucoccidia 12
- Eurytrema pancreaticum* 154
- Excystation 17
- Exflagellating male gametocytes 71
- Exoenteric cycle 93
- Exoerythrocytic
 schizogony 68
 schizont 69
 stage 69
- Extrinsic incubation period 45, 55
- Eyes 232
- F**
- Fairley's test 147, 247
- Falciparum malaria, complications of 79*b*
- Falcon assay screening test 147
- Fasciola* 113, 141, 167
gigantica 7, 151
hepatica 4, 7, 143, 150, 151, 151*f*, 153,
 194, 201
 egg of 151*f*
 life cycle of 152*f*
- Fascioliasis 153
- Fasciolidae 141
- Fasciolopsis* 113, 141
buski 4, 7, 143, 151, 153, 156, 157*f*, 201
 egg of 157*f*
 life cycle of 158*f*
- Fast-flowing rivers 222
- Fat malabsorption 34
- Ferrissia tenuis* 145
- Fever 20
 high-grade 56
- Fibrin degradation products 84
- Filarial antigen, circulating 217
- Filarial worm 208
 classification of 208*t*
- Filariasis 208, 247
 lymphatic 210
 subcutaneous 210, 219
- Filariform 183
 larva 181, 181*f*, 184, 188, 191*t*, 213
 third-stage 188
- Flagella 13
- Flagellates 32, 32*t*
 zoological classification of 41
- Flagellum 41, 42
- Floatation method 237
- Flukes 141
- Fluorescent antibody
 direct 37
 indirect 83, 205, 206
- Fluorescent staining 100
- Formogel test 60
- Formol-ether sedimentation technique 237,
 237*f*
- Fragilis 39
- Free-living soil cycle 182
- Frenkel, skin test of 95
- Fulminant amebic colitis 19
- Furcocercous cercaria 145
- Fusiform worms 195

- G**
- Gametocytes 68, 71
 - Gametogony 11, 71, 73, 90, 97
 - Gastric washings 205
 - Gastrodiscoides* 113, 141
 - hominis* 7, 151, 153, 156, 159, 159^f
 - Gastrointestinal tract 142
 - Gastrophilus 167
 - Gelatin capsule 243
 - Gelminths 112
 - Genital flagellates 32
 - Geohelminths 207^b
 - Giant intestinal fluke 156
 - Giardia 6, 12, 13
 - lamblia* 3, 5-7, 13, 14, 32, 33^f, 35^f, 99, 109, 199, 244
 - life cycle of 34^f
 - Giardiasis 246
 - Giardia-specific antigen 35, 65
 - Giemsa stain 46, 59^f, 91^f, 240, 241
 - Glisson's capsule 153
 - Glucose-6-phosphate dehydrogenase 78, 79
 - deficiency 80
 - Glycogen
 - mass of 16
 - vacuole, large 16
 - Glycophorin 69
 - Glycoproteins 18
 - Glycosylphosphatidylinositol 56, 74
 - Gnathostoma spinigerum* 167, 231, 232
 - egg of 231^f
 - Gnathostomiasis 166
 - Golgi 67
 - cycle 67
 - Gomori methenamine silver 94
 - Gram's stain 105
 - Granules, column of 211
 - Granuloma formation 214
 - Ground glass appearance 16
 - Guinea worm 165
 - Gymnamebia 12
 - Gynecophoric canal 142
- H**
- Harada-Mori filter paper strip culture 239
 - Harada-Mori tube method 192, 239^f
 - Hartmannella culbertsoni* 28
 - Heart 13
 - Heidenhain's hematoxylin magnification 25^f
 - Helminths 1, 111, 111^t, 113
 - zoological classification of 113
 - Hemagglutination, indirect 7, 83, 127, 133, 205, 206
 - Hemoflagellates 13, 14, 32, 41
 - stages of 42^t
 - Hemoglobin 79, 83
 - nature of 80
 - Hemoglobinuric nephrosis 79
 - Hemoptysis 161
 - Hemorrhage 56
 - Hemosporina 12
 - Hemozoin pigment 69, 77
 - Hepatic lobe, right 134^f
 - Hermaphrodites 112, 116
 - Hermaphroditic flukes 143, 150
 - Hermaphroditic trematode, morphology of 142^f
 - Herring worm disease 233
 - Heterophyes 113, 141, 156
 - heterophyes 7, 151, 158, 232
 - Heterophyidae 141
 - Hexacanth 117
 - embryo 118, 123, 130
 - oncosphere 136
 - Histidine rich protein 7, 74, 83
 - Hookworm 187
 - diagnosis of 193^{fc}
 - filariform larva of 180^t
 - infection 187^b, 190, 192^b
 - Host-parasite relationships 2, 3^{fc}
 - Human African trypanosomiasis 45^b, 47
 - treatment of 47^t
 - Human
 - acquire infection 93
 - hookworm 166
 - immunodeficiency virus 10, 24, 36, 57, 105^b
 - infection 230
 - large intestine 159
 - leukocyte antigen 80
 - malaria 66
 - parasites 69^t
 - nematode 167
 - trematode 167
 - Humoral immunity 81
 - Hydatid
 - cyst 130, 131, 131^f, 132^f, 134^f, 136
 - fate of 133
 - disease, malignant 136^b
 - fluid 132
 - sand 132
 - Hydrocele 214
 - Hymenolepiasis 139
 - Hymenolepis* 113, 115
 - diminuta* 7, 116, 139, 226
 - nana* 3, 4, 7, 112, 116, 122, 136, 139, 189, 199, 226
 - adult worm of 137^f
 - egg of 137^f
 - life cycle of 138^f
 - Hypergammaglobulinemia 60
 - Hyperinfection 184
 - Hypnozoites 69, 71, 81
 - reactivation of 81
 - Hypochromic microcytic anemia 192
 - Hypoglycemia 79
- I**
- Iatrogenic transmission 4
 - Iliac crest 58
 - Immature cyst 96^f
 - Immunity 5, 24, 58, 80
 - Immunochromatographic card test 58, 216, 217, 247
 - Immunofluorescence
 - assay 227
 - indirect 35
 - Immunoglobulin
 - E 198, 215
 - M 5, 80, 246
 - Indian visceral leishmaniasis 56
 - Indirect fluorescent antibody 23, 216, 217, 246
 - test 94, 95
 - Indirect hemagglutination 21, 23, 46, 47, 51, 216, 217, 246, 247
 - assay 23
 - Indirect immunofluorescence 47, 51, 246, 247
 - Infective rhabditiform 201
 - larva 176
 - Inflammatory reaction 5
 - Innate immunity 80
 - Intercellular adhesion molecule 74
 - Interferon gamma 74
 - Intestinal
 - amebiasis 18, 19, 19^f, 21, 24
 - chronic 19^b
 - sequelae of 19^b
 - bilharziasis 148
 - biopsy 97
 - entamoeba 26^t
 - flagellates 13, 32
 - flukes 141, 142, 156, 176
 - helminths 247
 - human nematodes 165
 - invasion, stage of 173
 - sarcocystosis 102
 - taeniasis 126, 128
 - Intestine 13
 - large 13, 107, 142, 165, 175, 175^b
 - small 13, 32^b, 122^b, 142, 165, 180, 180^b, 200
 - Intradermal
 - allergic tests 156
 - skin test 147
 - test 51
 - Intravenous pyelogram 134, 147
 - Iodamoeba* 12, 26
 - butschlii* 15, 25, 26
 - Iodine staining 235
 - Iodophilic body 26
 - Iodoquinol 24
 - Iron-hematoxylin stain 235
 - Isoenzyme study 47

- Isospora* 12, 66, 236
belli 3, 7, 13, 96, 105
 oocysts of 96*f*
 Itching papules 165
 Ivermectin 218, 222
- J**
- Jaundice, obstructive 136
 Jejunal biopsies 184
 Jejunum 129, 156, 187
- K**
- Kala-azar 13, 52, 53, 55, 56, 56*b*, 57*f*, 58*fc*
 Karyosome 10
 Katayama
 disease 150
 fever 148, 150
 Kato thick smear technique 235
 modified 238
 Kato-Katz smear technique 192
 Kawamoto technique 83
 Keratitis 13, 29
 stromal 104
 Keratoconjunctivitis 104
 Kidney 21
 Kinetoplast 10, 41, 42, 53
 Kinetoplastida 12, 13
 Kinyoun's acid-fast stain 97, 236
 reagents of 236*b*
 Kinyoun's carbol fuchsin 236
 Knott's concentration technique 216
 Kupffer cells 56
- L**
- Lactophenol cotton blue 135
 Lancet fluke 153
 Larva 165, 171, 225
 currens 166, 184
 detection of 227
 development of 227
 infective stage of 166
 migrans 165, 232
 cutaneous 167, 167*t*, 168, 168*t*
 third-stage 191*t*
 Latex agglutination test 23, 95
 Laverania 66
 Leishman's stain 240, 241
 Leishman-Donovani body 54*f*, 59*f*
Leishmania 4, 12, 13, 41, 52, 245
aethiopica 53, 61
braziliensis 13
 complex 53
 classification of 53*t*
donovani 7, 13, 52, 53, 59*f*, 248
 life cycle of 55*f*
 morphology of 54*f*
 transmission of 56*t*
 infantum 53
 major 53, 61
 mexicana complex 53
 peruviana 53
 tropica 13, 53, 61
 complex 61
 Leishmaniasis 246
 cutaneous 13, 52, 53
 mucocutaneous 13, 52, 53, 63
 Leishmanin skin test 60, 247
 Lepromatous leprosy 184
 Leukopenia 56, 57
 Lieberkuhn, crypts of 18
 Lipophosphoglycan 23, 55
 Liposomal amphotericin-B 61
 Liver 56, 131*f*, 151
 abscesses 21
 biopsy 23
 fluke 141, 142, 150
 rot 151
 Loa loa 7, 165, 167, 208, 210, 219, 221, 222, 224, 226, 241
 Lobopodia 27
 Lobosea 12
 Locke's solution 244*b*
 Locomotion 112
 Loeffler's syndrome 166, 203, 204*b*
 Lugol's iodine 235
 Lumbricoides 200
 Lumen-dwelling flagellates 32
 Luminal amebicides 24
 Lung 150, 160
 flukes 141, 142, 160
 right lower lobe of 134*f*
Lutzomyia 63
flaviscutellata 53
longipalpis 53
olmeca 53
umbratilis 53
 Lymph node 13
 aspirates 59
 peripheral 56
 Lymphadenitis 214
 Lymphadenopathy 45, 57, 93
 Lymphangioma 214
 Lymphangitis 214
 Lymphedema 214
 Lymphoreticular malignancies 184
 Lymphorrhagia 214
- M**
- Machado-Guerreiro test 51
 Macrogamete 92, 98
 Macrogametocyte 71, 73
 Macules, hypopigmented 223
 Malaria 13, 66, 78*b*, 83*b*, 87*t*
 congenital 80
 Control Programs 86
 global distribution of 67*f*
 initiative, roll-back 86
 merozoite-induced 80
 organs in 78*f*
 parasite 14, 66, 70*f*, 73*f*, 74*f*, 82*b*, 82*f*, 240, 245
 culture of 82
 pigment 69, 69*b*
 septicemic 79
 tertian malignant 79
 vaccine 85
 Malarial parasite
 drug resistance of 85
 types of 71
 Malnutrition, severe 184
Mansonella
ozzardi 165, 208, 210, 223, 241
perstans 165, 208, 210, 223, 224, 242
streptocerca 208, 210, 223, 233
 Mass therapy 217
 Mastigophora 12, 13
 Mastigote 41
 Maurer's clefts 73
 Mazzotti reaction 222
 McMaster's egg counting 238
 Melarsoprol 47
 Membrane filtration concentration 242
 Meningoencephalitis 230
 Merogony 69, 105
 Merozoites 68
 Mesoendemic 67
 Metacyclic trypomastigotes 43, 49
 Metacyst 18
 Metacystic trophozoites 18
Metagonimus 141
yokogawai 7, 143, 156, 159, 172, 232
 Metazoa 10
 Metriphonate 147
 Metronidazole 24
 Meyers Kouwenaar syndrome 215
 Microabscesses 148
 Microconcentration technique 82
Microfilaria 208, 211, 219, 241, 248
bancrofti 211, 220*f*
 morphology of 211*f*
 demonstration of 215
malayi 220*f*
 Microgamete 92, 98
 Microhematocrit tube method 242
Microspora 11, 12, 14, 66, 104
 Microsporidia 3, 48, 105, 106
 classification of 104*t*
 infective stage of 105
 Microsporidium 104, 105
Microsporium 12
 Migrating larva 190, 203
 Mild flu 93
 Monocytosis 46
 Montenegro test 60, 247

Mosquito-borne malaria 80*t*
 Motile bacteria 20
 Motile trophozoites 20
 Mucus plug 175
Multiceps multiceps 129
 Multilocular hydatid 136
 Multiple fission 11
 Murine strain 139
 Muscle 104, 171
 biopsy 172, 173*b*, 243
 invasion, stage of 173
 Muscular cysticercosis 126
 Myocarditis 46, 46*b*
 Myositis 104

N

Naegleria 12, 15, 29*t*, 233
 fowleri 1, 13, 15, 26, 231, 244
 life cycle of 28*f*
 Napier's aldehyde test 60
 National Rural Health Mission 86
 National Vector Borne Disease Control Programme 86
Necator 165
 americanus 3, 7, 165-167, 176, 180, 187, 189, 192, 204, 207, 229, 243
 Nelson's medium 23
 Nematodes 111-113, 164
 classification of 165*t*
 zoological classification of 166*t*
 Nematohelminthes 111
 Neoplasia 5
 Nerves 13
 Neural larva migrans 168, 207
 Neurocysticercosis 126
 Neutropenia 56
 Nifurtimox 51
 Nitazoxanide 100
 Nocturnal enuresis 197
 Noncalcified hydatid cyst 134*f*
 Nonspecific serum tests 60
 Normocytic normochromic anemia 60
Nosema bombycis 104
 Novy-MacNeal-Nicolle medium 245, 245*b*
 Nucleic acid amplification test 37
 Nuclepore filtration 216
 Nucleus 10, 16, 41, 42

O

Ocular cysticercosis 127, 128
 Ocular toxoplasmosis 94
Onchocerca volvulus 165, 208, 210, 221, 221*f*, 223
Onchocerca 222
 Onchodermatitis 222
 Oncosphere 117, 118
 Oocyst 71, 90, 92, 105
 mature 96*f*

 spherical 98
 thin-walled 98
 Ookinete 71
 Operculate snails 154
 Operculum 118
 Ophthalmic larva migrans 168, 207
 Opisthorchioidea 141
Opisthorchis 113, 141
 felineus 143, 151
 viverrini 143, 145, 151
 Opportunistic infections 105*b*
 Oral flagellates 32
 Ovarian lobe, accessory 122
Oxyuris vermicularis 195

P

Packed cell volume 79, 83, 84
 Pancreatic duct 154
 Pancreatitis 205
 Panstrongylus megistus 48
 Parabasal body 42, 53
 Paragonimiasis, abdominal 161
Paragonimus 113, 141
 westermani 4, 143, 151, 160, 160*f*, 161, 163, 204, 230, 232, 233, 242, 243, 248
 egg of 161*f*
 life cycle of 162*f*
 Paramphistomatidae 141
 Parasite 1, 2*b*, 3*t*, 7*b*, 115, 201*b*, 204*b*
 aberrant 1
 accidental 1
 detection of 205
 escape mechanisms 6*t*
 exhibiting antigenic variations 5*b*
 F test 83
 facultative 1
 free-living 1
 infectious 199*b*
 lactate dehydrogenase 83
 life cycle of 3
 quantification of 82*b*
 types of 2*fc*
 Parasitic diseases 7*t*
 Parasitology 1
 Paratenic host 2
 Paromomycin 24, 61, 100
 Pelvic
 plexuses 144
 venous plexuses 145
 Pentamidine 47
 Peribronchial granulomatous lesions 161
 Pericardial amebiasis 19
 Pericyst 131
 Peridomestic cycle 48
 Periodic acid-Schiff stain 91, 105
 Peripheral blood 7*t*, 82*f*
 Peristome 107

Petri dish culture method 239*f*
 Phasmid 166
Phlebotomus
 argentipes 53
 ariasi 53
 longipes 53
 orientalis 53
 papatasi 53
 pedifer 53
 perniciosus 53
 sergenti 53
 Pinworm 165
 Piroplasmia 12
 Pistia plant, removal of 218
 Plagiorchioidea 141
 Planoconvex egg 196*f*
Plasmodium 1, 11, 12, 66
 falciparum 5, 7, 66, 67, 69, 73, 74*f*, 77, 78, 82*f*, 83, 88, 89
 chloroquine resistance transporter 84, 248
 erythrocyte membrane protein-1 74, 79
 histidine-rich protein 83
 lactate dehydrogenase 7
 multidrug resistance protein 84, 248
 lactate dehydrogenase 246
 malariae 66, 67, 69, 75, 77, 78, 89
 stages 76*f*
 ovale 66, 67, 69, 75, 77, 78, 89
 vivax 7, 66, 67, 69, 71, 72*f*, 73*f*, 77, 78, 88, 89
 life cycle of 68*f*
 Plastic envelope medium 37
 Platyhelminthes 111, 115
Pleistophora 104
 Plerocercoid larva 118
Pneumocystis
 jirovecii 5, 243
 pneumonia 94
 Pneumonitis 204*b*
 Polar tubule 105
 Polymerase chain reaction 8, 35, 83, 84, 87, 127, 133, 216, 217, 247
 Portal hypertension 148, 156
 Post-kala-azar dermal leishmaniasis 13, 52, 57, 57*t*, 243
 treatment of 57
 Praziquantel 128, 147, 148, 158
 Precyst 16
 Pre-erythrocytic schizogony 68, 69*t*
 Primaquine 84, 85
 Procercoid larva 118, 120
 Proglottids 116, 127
 Promastigote 42, 53, 54*f*
 Protein 34
 merozoite surface 85
 Protozoa 1, 410, 32*b*

- classification of 11, 12*t*
 transmitted 37*b*
 Protozoan parasites 34*b*
 Protozoology 1
 Pruritus ani 196
 Pseudocele 164
 Pseudocyst 91
 Pseudophyllidean 117, 117*t*
 tapeworms 117
 Pseudopodia 10, 13, 15, 16
 Pseudotumoral growth, granulomatous 19
 Pulmonary capillaries 130
 Pyknotic bodies 22
 Pyriform 129, 159
 Pyrimethamine 95
- Q**
- Quadrinucleate ameba 18
 Quadrinucleate cyst 26*f*, 33*f*
 mature 16
 Quantitative buffy coat 82, 83
 Quartan malaria 75
 Quinine 84
- R**
- Rat fleas 138
 Rat tapeworm 139
 Rectal biopsy 146, 148
 Red blood cell 13, 19, 20, 39, 67, 68, 74, 78,
 80, 82, 235
 splenic sequestration of 56
 Renal transplantation 80
 Respiratory distress syndrome, acute 87
 Reticulocytes 72
 Reticuloendothelial system 13
 Retortamonadida 12
 Retortamonas 12
 intestinalis 32, 38
 Retroinfection 196
 Rhabditiform larva 181, 181*f*, 183, 188, 203
 Rhizopoda 12
Rhodnius prolixus 48
 Ribonucleic acid 82, 248
 River blindness 222
 RK 39 test 60
 Robinson's medium 23
 Rodent feces 138
 Romana's sign 50
 Roundworm egg 202*t*
- S**
- Sabin-Feldman dye test 95, 246
 Salivary gland 68
 Salpingitis, chronic 197
 Sandy patches 145
Sarcocystis 12, 66, 102
 hominis 32, 172, 226
 oocyst of 102*f*
 suihominis 172, 226
 Sarcocystosis, muscular 102
 Sarcodina 12, 13
 Sarcomastigophora 11, 12, 15
 Saturated salt solution 176*b*
 technique 237
 Schaudinn's solution 236
Schistosoma 141, 144*f*
 eggs 238*b*
 haematobium 5, 7, 143-145, 147*fc*, 149,
 207, 217
 egg of 144*f*
 intercalatum 150
 japonicum 143, 149, 232
 mansoni 143, 147, 149
 mekongi 150
 Schistosomatidae 141
 Schistosomes 143, 143*b*, 150
 morphology of 143*f*
 Schistosomiasis 145
 acute 145
 chronic 145
 Schizogony 11, 68, 73, 90, 97, 98
 Schneider's drosophila tissue culture
 medium 59
 Schneider's insect tissue culture medium
 245, 245*b*
 Schuffner's dots 72
 Scotch tape method 198, 198*f*, 238
 Segmentina 157
 Serological tests 7, 205
 Serous cavity filariasis 210, 223
 Serpent worm 225
 Serum glutamic pyruvate transaminase 88
 Sheep liver fluke 150
 Sigmoidorectal region 18, 144
 Sigmoidoscopy 178
 Silkworm disease 104
 Skeletal muscle 104, 171
 Skin 13
 snip 243
 test 7, 8*b*, 60, 62, 63, 217, 227, 247
 transmission 4
 Sleeping sickness 13, 42
 Slender thread-like worms 208
 Smooth curves 216
 Somatic cells 211
 Somatic human nematodes 165
 South American trypanosomiasis 42
 Sparganosis 120, 121, 166
 Sparganum 118
 larva 120
 Spherical nucleus 38
Spirometra 115, 120
 erinacei 116
 life cycle of 121*f*
 theileri 116
 Spirurid nematode 231
- Spleen 21, 56, 78
 Spoliative effects 203
 Sporoblasts 96
 Sporocyst 96, 142, 153, 154
 Sporogony 68, 71, 90, 104, 105
 Sporozoa 12, 66*t*
 Sporozoites 68, 71
 Stallion's disease 43
 Stercoraria 42
 Stoll's dilution technique 238
 Strawberry mucosa 37
 String test 35
 Strobila 116, 117
Strongyloides 165, 229, 239
 stercoralis 4, 105, 164, 165, 167, 180,
 184*fc*, 185, 199, 204, 207, 226, 232,
 243, 248
 egg of 181*f*
 larvae of 181*f*
 life cycle of 182*f*, 183*fc*
 Strongyloidiasis 185
 Sugar floatation technique 237
Suihominis 32
 Sulfadiazine 95
 Suppurative inflammation, acute 29
 Swimmer's itch 145
 Sylvatic zoonosis 48
 Syngamy 11
 Systemic lupus erythematosus 29
- T**
- Tachyzoites 91, 93
Taenia 115
 antigen, detection of 127
 egg of 124*f*
 multiceps 129, 226, 232
 saginata 4, 7, 116, 122, 123*t*, 140, 172,
 176, 201, 226
 asiatica 122, 129, 226
 life cycle of 125*f*
 solium 2-4, 7, 112, 116, 117, 122, 122*f*,
 123*t*, 140, 199, 201, 207, 226, 229,
 232
 adult worm of 122*f*
 egg of 176
 life cycle of 125, 126*f*
 Tapeworm 115, 115*f*, 122, 129,
 Tetracyclines 218
Tetrapetalonema
 perstans 223
 streptocerca 223
 Thrombocytopenia 56, 57, 60
 Tick-borne disease 86
 Tinidazole 24
 Tiny knob 154
 Tissue 6
 amebicides 24
 biopsy 243

- cyst 90, 91, 93
hypoxia 77
necrosis 18
- Toxic megacolon 19
- Toxocara canis* 167, 206, 232, 233
adult worms of 206f
- Toxocara cati* 167, 206, 232
- Toxocariasis 247
- Toxoplasma* 11, 12, 14, 66, 90, 94
encephalitis 95, 96
gondii 1, 2, 4, 5, 10, 14, 46, 48, 90, 90f, 91f, 93, 94fc, 96, 105, 172, 248
life cycle of 92f
infection 93, 94
pneumonia 94
- Toxoplasmosis 94, 245, 246
acquired 93
acute 93
congenital 93, 95
- Trachipleistophora 104
- Transfusion malaria 80
- Transovarian transmission 87
- Transverse binary fission 108
- Trauma 5
- Traveler's diarrhea 99b
- Trematodes 4, 112, 141, 143b
classification of 141
zoological classification of 141t
- Triatoma infestans* 48
- Trichina worm 170
- Trichinella* 140, 164
cyst 171
spiralis 4, 7, 46, 165, 170, 172, 173fc, 174, 180, 199, 207, 226, 232, 243
adult worms of 170f
life cycle of 172f, 173t
- Trichinosis 247
- Trichomonadida 12
- Trichomonas* 12, 13, 36, 39
hominis 32, 36f, 38
tenax 32, 36f, 37, 204
vaginalis 3, 6, 7, 13, 36, 36f, 95, 109, 217, 244
- Trichostomatina 12
- Trichostrongyliasis 193
- Trichostrongylus orientalis* 7
- Trichrome stain 235
modified 105, 236
reagents of 236b
- Trichuris* 175, 229
trichiura 3, 7, 109, 150, 165, 175, 176, 178, 178fc, 189, 196, 201, 207
egg of 176f
life cycle of 177f
- Triclabendazole 153
- Tripartite 187
- Trop-bio test 217
- Trophozoite 11, 14, 16, 16f, 27f, 29, 33, 33f, 38f, 39, 86f, 90, 91, 91f, 107, 107f
extracellular 90f
- Tropical pulmonary eosinophilia 215, 217
- Trypanosoma* 12, 13, 41, 233, 241, 244, 248
brucei 4, 13, 32, 42, 231
brucei 43
life cycle of 44f
gambiense 5, 42, 50
rhodesiense 5, 43, 45, 46, 50
cruzi 4, 13, 32, 43, 46-48, 48f, 50, 50f, 51, 93, 226
life cycle of 49f
equiperdum 43
evansi 43
gambiense 43, 43f
lewisi 43
infections 95
rangeli 43, 51
rhodesiense 43f, 46f
- Trypanosomatidae 41
- Trypanosomatina 12
- Trypanosomes 42, 51
classification of 42
- Trypanosomiasis 43f, 46fc, 245, 246
- Trypomastigote 42, 48, 48f
- Tsetse fly 45
- Tubercles 147
- Tubulina 12
- Typhus-like exanthema 94
- U**
- Uncinaria stenocephala* 167
- United Nations Children's Fund 86
- United Nations Development Programme 86
- Upper respiratory tract 29
- Urethra 13
- Urethritis 13
- Urinary bladder 144
carcinoma 145
- Urine 6, 7b
- V**
- Vaccination 5
- Vacuole 53
- Vagina 13
- Vaginal sphincter, prominent 122
- Vaginitis 13
- Vascular cell adhesion molecule-1 74
- Vector mosquito, eradication of 218
- Vector transmission 4
- Vermicures 87
- Vertebrate host 44
- Visceral larva migrans 167, 167t, 168, 168t, 206, 207
- Visceral leishmaniasis 52, 53, 54f, 61b, 245
- Viviparous nematodes 226b
- W**
- Water plants, ingestion of 159
- Watsonius watsoni* 153, 156, 159
- West African trypanosomiasis 43, 45f
- Western blot 100
- Wet saline mounts 235
- Wheatley's trichrome stain 235
- Whip-like flagella 32
- Whipworm 165, 175, 176f
- White blood cell 29, 83, 242
- Winterbottom's sign 45
- Wolbachia* 208, 223
- Wright's stain 241
- Wuchereria* 164
bancrofti 4, 7, 165, 199, 208, 210, 211f, 212, 213, 216fc, 217, 218, 224, 226, 241
adult worm of 211f
life cycle of 212f
- Y**
- Young erythrocytes 72
- Young trophozoites 69
- Z**
- Ziehl-Neelsen stain 100f
modified 97, 98, 236
- Ziemann's stippling 75
- Zinc sulfate floatation concentration technique 237f
- Zooanthroposes 2
- Zoomastigophorea 12
- Zoonoses 2, 8
- Zoonotic filariasis 223
- Zoophilic nematode 167
- Zygocotylidae 141
- Zygote 71